



PATIENT

Major Lasiw

SPECIES

Canine

BREED

Pit Bull Terrier

SEX

MN

AGE

6 years

WEIGHT

65 lbs.

INTERPRETED BY

R. McKenzie Daniel,
DVM, DABVP
(Canine and Feline)

IMAGING PERFORMED BY

Kelly Vazquez

HOSPITAL NAME

The Venturing Vet

REFERRING VET

Dr. Marisa Herzog

INVOICE

13456

DATE

3/9/22

PRESENTING CLINICAL SIGNS

Patient presents for evaluation of neck/thyroid due to firm swelling/tissue density along the right side of the neck. Previous aspirations revealed suspicion for an epithelial tumor and possible salivary structure with mesenchymal proliferation.

ULTRASONOGRAPHIC EXAMINATION OF THE NECK

Sonographic assessment of the right neck revealed an unspecified hypoechoic lesion to mass effect, measuring approximately 2.0 cm in diameter but potentially larger given the depth and penetration of the study. Lesion potentially in the area of the right thyroid, although not definitive. The area of the left thyroid / parathyroid gland was sonographically unremarkable.

The right carotid artery appeared to be structurally normal yet potentially displaced medially towards the trachea. The left carotid artery was structurally normal.

The visualized esophagus and visualized trachea were overtly normal.

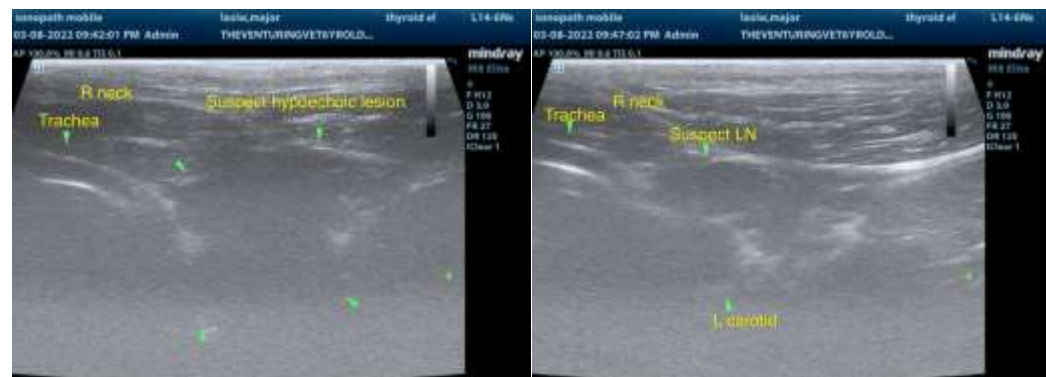
Suspect potential associated mild regional lymphadenopathy was noted. An example of a suspected lymph node measured 0.5 cm in diameter. Mild evidence of regional inflammation was noted. No evidence of free fluid was present.

ULTRASONOGRAPHIC FINDINGS

- Unspecified lesion to mass effect in right neck potentially in the area of the right thyroid gland, suspect potential mild regional lymphadenopathy and mild Inflammation

INTERPRETATION OF THE FINDINGS & FURTHER RECOMMENDATIONS

CT of the neck in the area of the reported soft tissue swelling is ideal given this presentation and recommended prior to potential biopsies / sampling for further assessment, clarification, and potential biopsy planning. Histopathology is required for further definition.





PATIENT

Major Lasiw

SPECIES

Canine

BREED

Pit Bull Terrier

SEX

MN

AGE

6 years

WEIGHT

65 lbs.

INTERPRETED BY

R. McKenzie Daniel,
DVM, DABVP
(Canine and Feline)

IMAGING PERFORMED BY

Kelly Vazquez

HOSPITAL NAME

The Venturing Vet

REFERRING VET

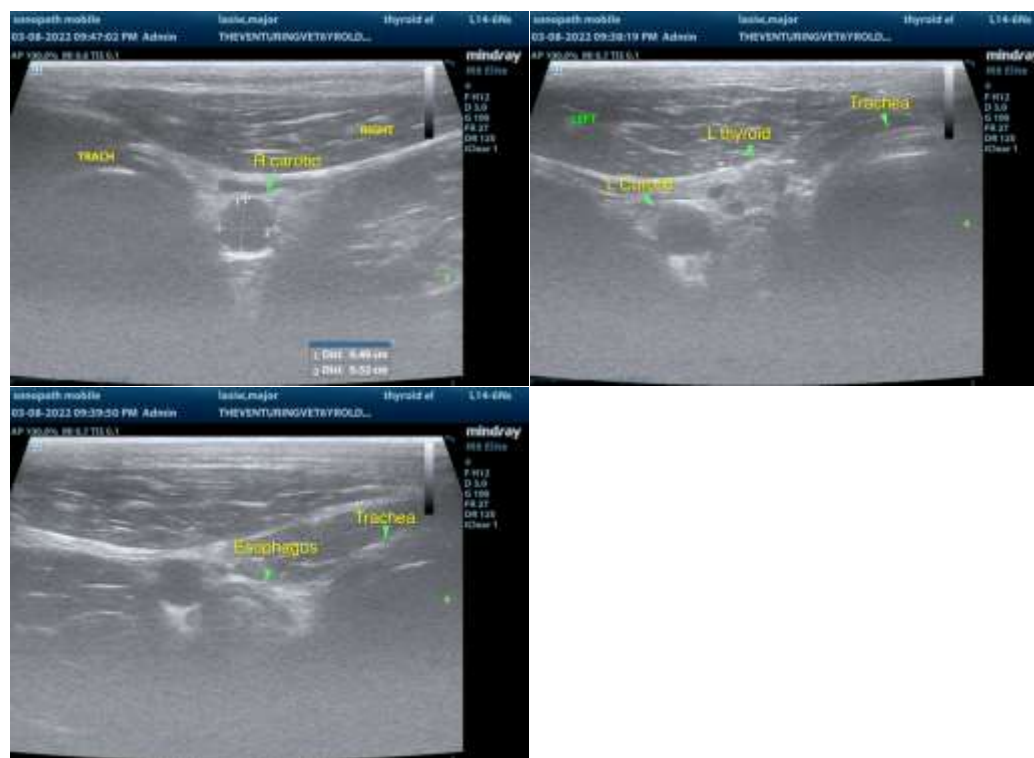
Dr. Marisa Herzog

INVOICE

13456

DATE

3/9/22



The information and recommendations provided are based on the images presented by the referring veterinarian/sonographer. No evaluation can be communicated regarding pathology that was not visible in the image/video clips provided.

Thank you for this referral. If the clinical or image interpretation does not parallel your findings or if I can be of any further assistance please contact me.

R. McKenzie Daniel, DVM, DABVP (Canine / Feline Practice)
info@SonoPath.com

SonoPath CT Services are offered at the Blairstown Animal Hospital. Blairstown, New Jersey. More information can be found at

<https://sonopath.com/resources/sonopaths-teleconsultation-services-and-sdep-certification/sonopath-ct-services>