



PATIENT

Shredder
Christensen

SPECIES

Canine

BREED

MIn Pincher

SEX

Neutered Male

AGE

12

WEIGHT

5.8 kg.

INTERPRETED BY

R. McKenzie Daniel,
DVM, DABVP
(Canine and Feline)

IMAGING PERFORMED BY

Dr. Belan

HOSPITAL NAME

Stoney Trail Vet
Clinic

REFERRING VET

Dr. Huet

INVOICE

13450

DATE

3/8/22

PRESENTING CLINICAL SIGNS

2/6 murmur detected on last wellness exam dental procedure pending. Pre anesthetic assessment.

ULTRASONOGRAPHIC EXAMINATION OF THE HEART

CANINE CARDIAC PARAMETERS	MR VMAX (m/s)	TR VMAX (m/s)	LA/AO (Boon method)	LA/AO (Heart Base; Swe)	FS (%)	EF (%)	EPSS (cm)
NORMAL PARAMETER	4.5-5.5	<2.7	1.3	<1.6	28-40	40-100	<0.6
PATIENT	5.0	<2.0		1.33	37.2	69.5	0.25
CANINE CARDIAC PARAMETERS	HR (BPM)	AV VMAX (m/s)	PV MAX (m/s)	BODY WEIGHT (kg)	LA 2D short axis Base view (cm)	LVIDd Avg; 2D and m-mode short axis (cm)	LVIDs Avg; 2D and m-mode short axis (cm)
NORMAL PARAMETER	50-100	0.7-1.7	0.7-1.6	BELOW	BELOW	BELOW	BELOW
PATIENT	125	1.1	1.0		2.3	2.4	

Cardiac Presentation

The echocardiogram in this patient demonstrated normal **left atrial** size based on 3 different LA measurement methods. Chamber volumes and echogenicity were normal. The cranial and caudal **mitral** valve leaflets presented vegetative thickening consistent with endocardiosis. Doppler indicated measurable mild eccentric insufficiency. The **left ventricle** presented thicknesses with linear contour and was not dilated nor restricted. The **myocardium** presented normal echogenicity without subjective evidence of significant fibrotic or ischemic disease. **Contractility** of the ventricular walls was adequate and in normal range for this patient evidenced by the fractional shortening measurement and subjective evaluation of the different regions of the myocardium. The **left ventricular outflow** tract demonstrated normal laminar flow and subjective structural integrity. The **right atrium** and auricle revealed normal size, structure and content. No evidence of masses was noted or chamber overload. **Tricuspid** valvular assessment revealed concurrent mild thickening with minor TR. The **right ventricle** was of normal size (1/3 diameter of LV), chordae structure, myocardial echogenicity and thickness. **Pulmonic** tract assessment revealed normal valve structure, laminar flow, and diameter (approx.1:1 pa/ao ratio). No visible **pericardial** or free pleura fluid was noted. No echographically detectable evidence of infiltrative disease was visible. The cranial **mediastinum and pericardial regions** were free of masses in the visible window.

ULTRASONOGRAPHIC FINDINGS

- Chronic mitral valve disease (ACVIM B1)
- Minor TR - not consistent with clinical pulmonary hypertension



PATIENT

Shredder
Christensen

SPECIES

Canine

BREED

MIn Pincher

SEX

Neutered Male

AGE

12

WEIGHT

5.8 kg.

INTERPRETED BY

R. McKenzie Daniel,
DVM, DABVP
(Canine and Feline)

IMAGING PERFORMED BY

Dr. Belan

HOSPITAL NAME

Stoney Trail Vet
Clinic

REFERRING VET

Dr. Huet

INVOICE

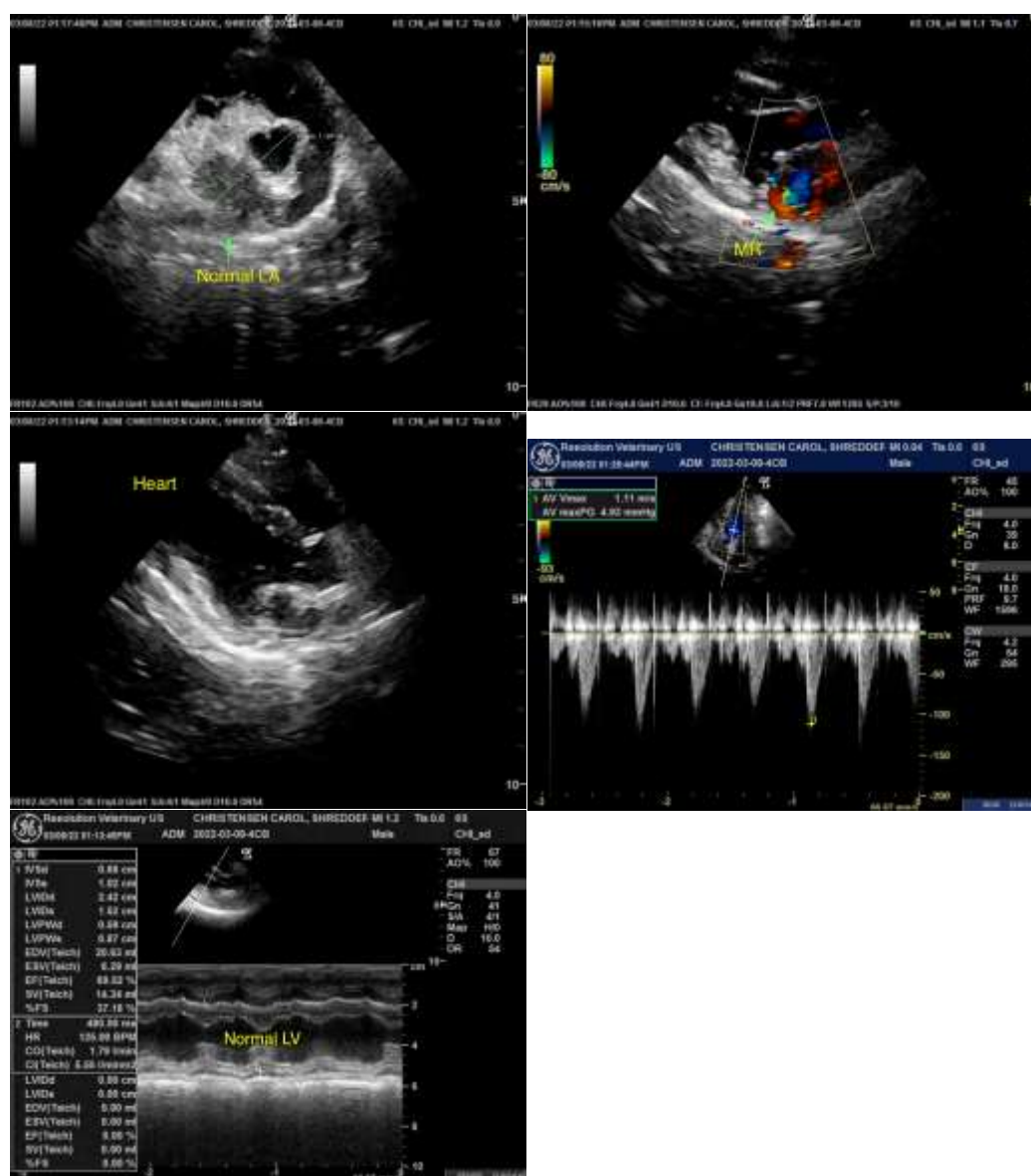
13450

DATE

3/8/22

INTERPRETATION OF THE FINDINGS & FURTHER RECOMMENDATIONS

The cause of the murmur is chronic degenerative valvular changes with secondary eccentric mitral valve insufficiency. The lack of left atrial enlargement implies that the hemodynamic effects of the mitral valve insufficiency are low and that the risk of complication secondary to mitral valve Insufficiency Is as well low. No other clinical issues such as systolic dysfunction or evidence of clinical pulmonary hypertension were noted. In a nonclinical patient without current clinical signs, medical therapy is not indicated. Conservative monitoring at this stage would be appropriate. However, sonographic monitoring is required for further prognosis. Initial recheck echocardiogram is suggested in 6-12 months, sooner if clinical signs arise.



The information and recommendations provided are based on the images presented by the referring veterinarian/sonographer. No evaluation can be communicated regarding pathology



PATIENT

Shredder
Christensen

SPECIES

Canine

BREED

MIn Pincher

SEX

Neutered Male

AGE

12

WEIGHT

5.8 kg.

INTERPRETED BY

R. McKenzie Daniel,
DVM, DABVP
(Canine and Feline)

**IMAGING
PERFORMED BY**

Dr. Belan

HOSPITAL NAME

Stoney Trail Vet
Clinic

REFERRING VET

Dr. Huet

INVOICE

13450

DATE

3/8/22

that was not visible in the image/video clips provided.

Thank you for this referral. If the clinical or image interpretation does not parallel your findings or if I can be of any further assistance please contact me.

R. McKenzie Daniel, DVM, DABVP (Canine / Feline Practice)
info@SonoPath.com