



PATIENT PRESENTING CLINICAL SIGNS

UJ Sharpe History: Grade IV/V/VI murmur, coughing, difficulty breathing.
 Abnormal PE/Chem/CBC/UA Results: PLT 424, Neut 54, Lymph 33, TP 7.8, Glob 3.9, ALKP 547, Ca 12.9

SPECIES

Canine

ULTRASONOGRAPHIC EXAMINATION OF THE HEART & ABDOMEN

BREED

Dachshund

SEX

Neutered Male

AGE

14 Years 8 Months

WEIGHT

13 Pounds

CANINE CARDIAC PARAMETERS	MR VMAX (m/s)	TR VMAX (m/s)	LA/AO (Boon method)	LA/AO (Heart Base; Swe)	FS (%)	EF (%)	EPSS (cm)
NORMAL PARAMETER	4.5-5.5	<2.7	1.3	<1.6	28-40	40-100	<0.6
PATIENT	5.1	<2.0	2.5	2.6	42.1	74.2	0.21
CANINE CARDIAC PARAMETERS	HR (BPM)	AV VMAX (m/s)	PV MAX (m/s)	BODY WEIGHT (kg)	LA 2D short axis Base view (cm)	LVIDd Avg; 2D and m-mode short axis (cm)	LVIDs Avg; 2D and m-mode short axis (cm)
NORMAL PARAMETER	50-100	0.7-1.7	0.7-1.6	BELOW	BELOW	BELOW	BELOW
PATIENT	183	1.1	0.8	--	4.7	3.5	--

INTERPRETED BY

R. McKenzie Daniel, DVM, DABVP (Canine and Feline)

IMAGING PERFORMED BY

Shari Reffi, CVT

HOSPITAL NAME

ACC Flanders

REFERRING VET

Dr. Hallihan

INVOICE

14242

DATE

3/8/22

Cardiac Presentation

The echocardiogram for this patient presented severely excessive **left atrial size** expressed both in the LA/AO and LA max measurements. Deviation of the intra-atrial septum towards the right atrium, consistent with increased left atrial pressure was present. The cranial and caudal **mitral** valve leaflets presented vegetative thickening consistent with endocardiosis with mild prolapse of the anterior leaflet. Doppler indicated measurable moderate eccentric insufficiency. The **left ventricle** presented thicknesses with linear contour with increased left ventricle volume. The **myocardium** presented normal echogenicity without subjective evidence of significant fibrotic or ischemic disease. **Contractility** of the ventricular walls was adequate and in normal range for this patient evidenced by the fractional shortening measurement and subjective evaluation of the different regions of the myocardium. The **left ventricular outflow** tract demonstrated normal laminar flow and subjective structural integrity. The **right atrium** and auricle revealed normal size, structure and content. No evidence of masses was noted or chamber overload. **Tricuspid** valvular assessment demonstrated mild thickening with minor TV insufficiency. The **right ventricle** was of normal size (1/3 diameter of LV), chordae structure, myocardial echogenicity and thickness. **Pulmonic** tract assessment revealed normal valve structure, laminar flow, and diameter (approx.1:1 pa/ao ratio). Trace PV insufficiency present. No visible **pericardial** or free pleura fluid was noted. No echographically detectable evidence of infiltrative disease was visible. The cranial **mediastinum and pericardial regions** were free of masses in the visible window. Subjective mild tachycardia present.

Urinary System



PATIENT

LJ Sharpe

The urinary bladder, trigone, cystourethral junction, and visible pelvic urethra to a depth of 2.0 cm exhibited normal thickness and tone. Primarily anechoic urine was present in the lumen. Minor echogenic to particulate sediment, likely consistent with minor cellular or crystalline debris. The ureteral papillae were normal. The ureters were not visible which is normal. No evidence of inflammatory or neoplastic mural changes were noted. The residual prostate was without pathology. Aortic trifurcation was normal.

SPECIES

Canine

Normal size and margination were present in the kidneys. A normal 1:3 cortex / medulla ratio was maintained. The medulla and cortices were uniform in texture with some increased echogenicity and loss of corticomedullary symmetry and definition expected for the age of the patient. No evidence of pelvic dilation was present. Focal areas of nonobstructive areas of medullary mineral. The left kidney measured 4.3 cm in length. The right kidney measured 4.7 cm in length.

BREED

Dachshund

Adrenal Glands

SEX

Neutered Male

The bilateral adrenal glands were normal in size. Mild parenchyma heterogeneity and mild capsule asymmetry was present without suspicion for overt neoplasia. The left adrenal gland measured 1.8 cm in length x 0.6 cm width in the caudal pole. The right adrenal gland measured 1.9 cm in length x 0.57 cm in the caudal pole.

AGE

14 Years 8 Months

Spleen

WEIGHT

13 Pounds

The spleen was overall normal in size and contour with generalized mild splenic parenchyma heterogeneity. A solitary, subtly expansive to hypoechoic nodule was present in the cranial lateral spleen, measuring 1.7 cm in diameter. No evidence of splenic parenchymal escape.

Liver

INTERPRETED BY

R. McKenzie Daniel,
DVM, DABVP
(Canine and Feline)

The liver was subjectively normal in size, structure, and contour. The liver parenchyma was mildly nonuniform and hypoechoic to the spleen with a moderate coarse echotexture and subjective mild to benign parenchymal remodeling. The hepatic and portal vasculature were normal in appearance without signs of congestion.

IMAGING PERFORMED BY

Shari Reffi, CVT

The gallbladder was non distended in size with moderate, nondependent yet nonorganized gallbladder debris, occupying the majority of the gallbladder lumen. No evidence of gallbladder or peripheral gallbladder inflammation. The cystic duct and common bile ducts were normal without evidence of dilation.

HOSPITAL NAME

ACC Flanders

Gastrointestinal

The stomach presented intact wall layering with a normal wall layer ratio. The lumen of the stomach was empty with no signs of ileus, obstruction or foreign material.

REFERRING VET

Dr. Hallihan

The small intestine presented intact wall layering with 1:3 muscularis/mucosa ratio. The lumen of the small intestine was empty with no signs of ileus, obstruction or foreign material.

Normal visible colon wall layers were present with apparent formed feces in lumen.

INVOICE

14242

Pancreas

The pancreas was normal in size and contour with isoechoic to heterogeneous parenchyma compared to adjacent omentum. No signs of active inflammation or neoplasia.

DATE

3/8/22

Free Abdomen

No overt lymphadenopathy or peritoneal effusion was present.



PATIENT	ULTRASONOGRAPHIC FINDINGS
LJ Sharpe	<ul style="list-style-type: none"> Chronic mitral valve disease- consistent with likely ACVIM stage C, mild anterior mitral valve leaflet prolapse
SPECIES	<ul style="list-style-type: none"> Severe LAE
Canine	<ul style="list-style-type: none"> Minor TR- estimated pulmonary pressure gradient not consistent with overt clinical pulmonary hypertension
BREED	<ul style="list-style-type: none"> Trace PV Insufficiency- not clinically significant
Dachshund	<ul style="list-style-type: none"> Nonspecific, subtly expansive splenic nodule-hyperplasia, hematopoiesis, splenitis or granuloma possible with neoplasia considered a less likely differential diagnosis yet cannot be excluded.
SEX	
Neutered Male	<ul style="list-style-type: none"> Vacuolar hepatopathy pattern with minor parenchymal remodeling-subjectively benign
AGE	<ul style="list-style-type: none"> Moderate gallbladder debris (non-mucocele) Bilateral chronic renal changes with nonobstructive medullary mineral Mild pancreatic remodeling-likely age-related pancreatic changes and incidental
14 Years 8 Months	
WEIGHT	<u>INTERPRETATION OF THE FINDINGS & FURTHER RECOMMENDATIONS</u>
13 Pounds	<p>The cause of the murmur is secondary to chronic degenerative valvular changes with secondary eccentric mitral valve insufficiency. The severe left atrial enlargement indicates that the current and future risk going forward for complication is significantly elevated with potential for cardiogenic pulmonary edema. Concurrent mainstem bronchi irritation or compression owing to left atrial enlargement as a contributing factor to the cough is possible. Potential for concurrent chronic lower airway disease cannot be definitively excluded. No overt evidence of clinical pulmonary hypertension.</p> <p>Pimobendan at 0.3 mg/kg PO BID, Lasix/Spironolactone combination at 1-2 mg/kg PO BID and hydrocodone (at appropriate dose) warranted. ECG, BP and monitoring of renal parameters is advised. Ace-inhibitor medication could also be considered, if BP >130 (not advised if BO <130).</p> <p>Going forward, this patient will be at increased risk for episodes of CHF and potential development of malignant arrhythmias (i.e., atrial fibrillation). Recheck echocardiogram suggested in 6 months or sooner if continued clinical signs or evidence of CHF is noted.</p> <p>Sonographic monitoring of the splenic nodule with initial recheck in 4 weeks for evidence of progression would be reasonable. Alternatively, assuming normal clotting status and using a 25-gauge needle, ultrasound guided FNA of the splenic nodule +/- hepatic FNA could be considered for screening cytology.</p>
INTERPRETED BY	
R. McKenzie Daniel, DVM, DABVP (Canine and Feline)	
IMAGING PERFORMED BY	
Shari Reffi, CVT	
HOSPITAL NAME	
ACC Flanders	
REFERRING VET	
Dr. Hallihan	
INVOICE	
14242	
DATE	
3/8/22	



PATIENT

LJ Sharpe

SPECIES

Canine

BREED

Dachshund

SEX

Neutered Male

AGE

14 Years 8 Months

WEIGHT

13 Pounds

INTERPRETED BY

R. McKenzie Daniel,
DVM, DABVP
(Canine and Feline)

IMAGING PERFORMED BY

Shari Reffi, CVT

HOSPITAL NAME

ACC Flanders

REFERRING VET

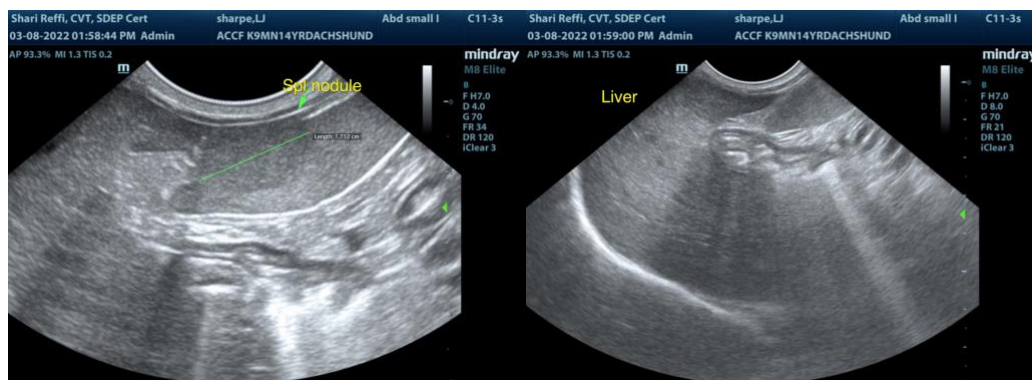
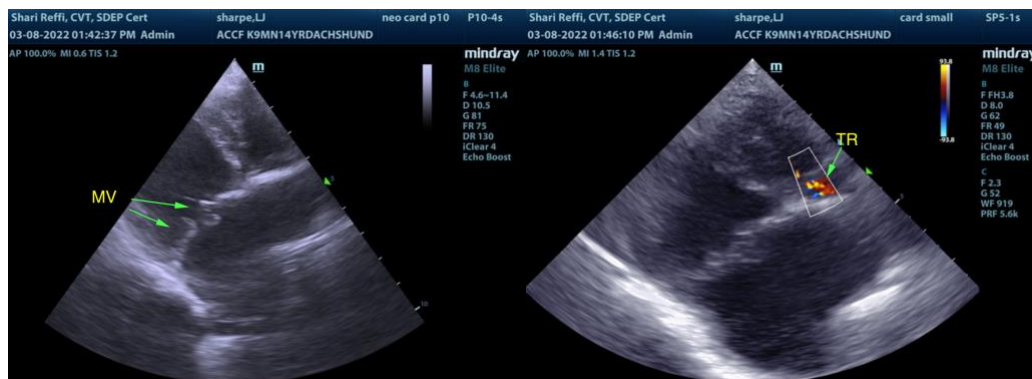
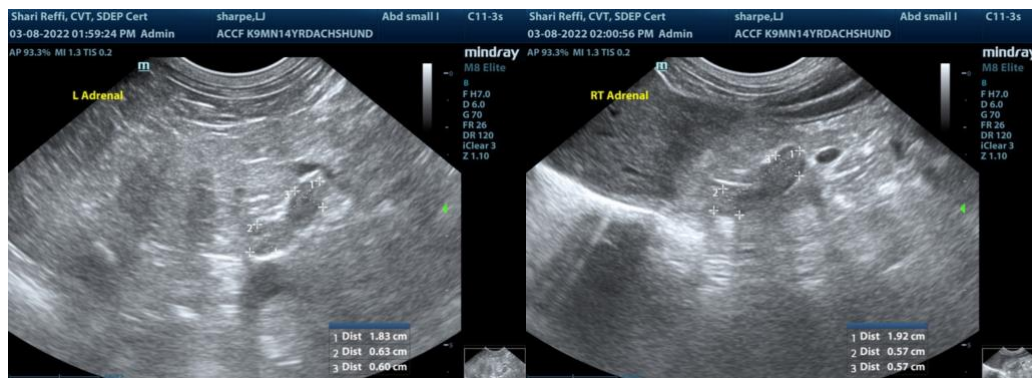
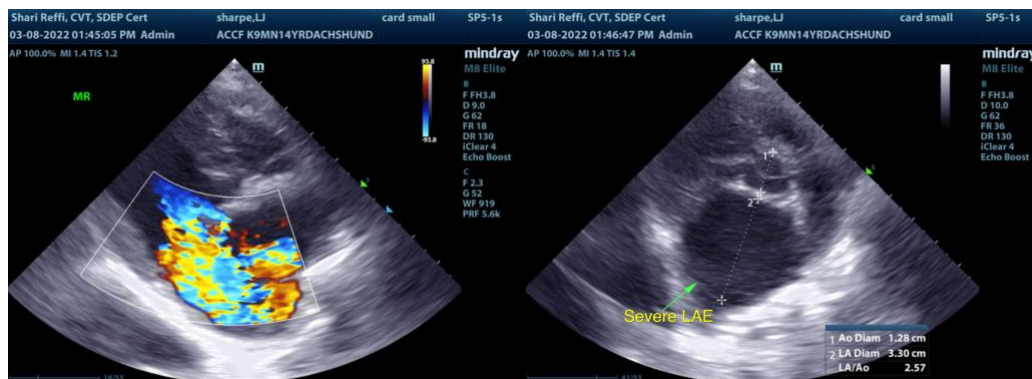
Dr. Hallihan

INVOICE

14242

DATE

3/8/22





PATIENT

LJ Sharpe

SPECIES

Canine

BREED

Dachshund

SEX

Neutered Male

AGE

14 Years 8 Months

WEIGHT

13 Pounds

INTERPRETED BY

R. McKenzie Daniel,
DVM, DABVP
(Canine and Feline)

IMAGING PERFORMED BY

Shari Reffi, CVT

HOSPITAL NAME

ACC Flanders

REFERRING VET

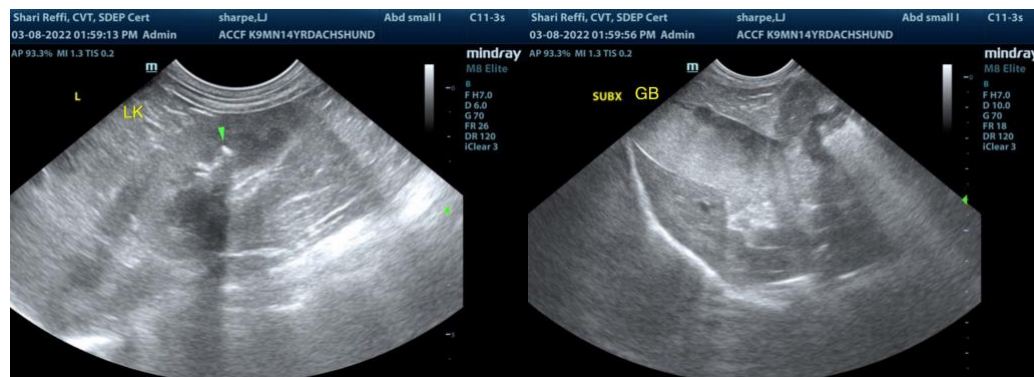
Dr. Hallihan

INVOICE

14242

DATE

3/8/22



The information and recommendations provided are based on the images presented by the referring veterinarian. No evaluation can be communicated regarding pathology that was not visible in the image/video clips provided.

Thank you for this referral. If the clinical or image interpretation does not parallel your findings or if I can be of any further assistance please contact me.

R. McKenzie Daniel, DVM, DABVP (Canine / Feline Practice)
info@SonoPath.com