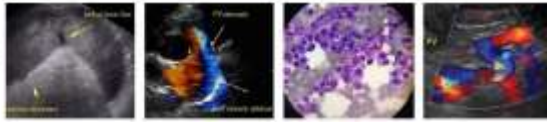


PATIENT	PRESENTING CLINICAL SIGNS
Jules Kong	Recheck has been on Cartrophen and Clinacin. Poss worsening spleen enlargement on palpation., Previous scan Oct 19, 2021
SPECIES	Abnormal PE/Chem/CBC/UA Results: n/a
Canine	ULTRASONOGRAPHIC EXAMINATION OF THE ABDOMEN
BREED	Urinary System
Retrvr X	The urinary bladder, trigone, cystourethral junction, and visible pelvic urethra to a depth of 4.0 cm exhibited normal thickness and tone. Anechoic urine was present in the lumen with no uroliths or sediment. The ureteral papillae were normal. The ureters were not visible which is normal. No evidence of inflammatory or neoplastic changes was noted.
SEX	The area of the aortic trifurcation was free of pathology.
FS	
AGE	Normal size and margination were present in the kidneys. A normal 1:3 cortex / medulla ratio was maintained. The medulla and cortices were uniform in texture with some increased echogenicity and mild loss of corticomedullary symmetry and definition expected for the age of the patient. Focal small cortical cysts were present in both the left and right kidneys. No evidence of pelvic dilation was present. The left kidney measured 6.0 cm in length. The right kidney measured 7.3 cm in length.
12 years	
WEIGHT	Adrenal Glands
38.5	A discreet, mildly nonhomogeneous, non-expansive nodule was present in the cranial pole of the left adrenal gland with mild associated symmetrical capsule expansion. The nodule did not exhibit signs of mineralization or vascular invasion. The nodule measured 0.8 cm x 0.55 cm. The overall left adrenal gland measured 2.1 cm length x 0.82 cm width at the caudal pole.
INTERPRETED BY	The right adrenal gland was normal in size. Mild parenchyma heterogeneity and mild capsule asymmetry was present without suspicion for overt neoplasia. The right adrenal gland measured 2.6 cm length x 1.1 cm width in the caudal pole. No evidence of concurrent right adrenal nodules was noted.
R. McKenzie Daniel, DVM, DABVP	
IMAGING PERFORMED BY	Spleen
Crystal Hill	Previously noted, nonhomogeneous, mildly expansive cranial splenic mass measuring 5.8 cm in diameter was present. Generalized mild cranial splenomegaly was present with the overall cranial spleen measuring approximately 7.5 cm in diameter. The mid to caudal spleen was sonographically unremarkable.
HOSPITAL NAME	Liver/ Gallbladder
The Maples AH	The liver was subjectively normal in size, structure, and contour. The liver parenchyma was mildly nonuniform and hypoechoic to the spleen with a moderate coarse echotexture and subjective mild to benign parenchymal remodeling. The hepatic and portal vasculature were normal in appearance
REFERRING VET	
Dr. Kazienko	
INVOICE	
DATE	
3/8/22	



PATIENT

without signs of congestion. The gallbladder was non-distended in size with thin walls and primarily anechoic luminal content. The cystic and common bile ducts were normal.

Jules Kong

Gastrointestinal

SPECIES

The stomach presented intact wall layering with a normal wall layer ratio. The lumen of the stomach was empty with no signs of ileus, obstruction, or foreign material.

Canine

The small intestine presented intact wall layering with 1:3 muscularis/mucosa ratio. The lumen of the small intestine was empty with no signs of ileus, obstruction, or foreign material.

BREED

Retrvr X

Normal visible colon wall layers were present with apparent formed feces in lumen.

SEX

Pancreas

FS

The parenchyma of the left limb, body, and right limb of the pancreas presented isoechoic to the adjacent omental fat. A normal curvilinear capsule contour of the pancreas was present. The visible pancreatic duct was normal. No signs of active inflammation or neoplastic disease were evident.

AGE

Free Abdomen

12 years

No evidence of peritoneal effusion or splenic mass rupture was present. No overt lymphadenopathy was noted. The generalized omentum including perisplenic omentum was of uniform echogenicity.

WEIGHT

ULTRASONOGRAPHIC FINDINGS

38.5

- Previously noted cranial splenic mass with mild generalized cranial splenomegaly
- Static mild hepatic parenchymal remodeling
- Static mild chronic renal changes with focal small cortical cysts
- Discreet cranial left adrenal nodule - suspect adenoma

INTERPRETED BY

R. McKenzie Daniel,
DVM, DABVP

INTERPRETATION OF THE FINDINGS & FURTHER RECOMMENDATIONS

**IMAGING
PERFORMED BY**

Crystal Hill

Subjectively, the previously noted cranial splenic mass appeared to be mildly progressive compared to the previous study, yet without overt evidence of significant changes or capsule expansion. Previously mentioned potential etiologies are still applicable yet, given the lack of significant changes or enlargement associated with the cranial splenic mass, a higher potential for benign etiology may be considered, although neoplastic criteria is possible. No evidence of intra-abdominal metastasis, if a splenic neoplastic process is present.

HOSPITAL NAME

The Maples AH

REFERRING VET

Dr. Kazienko

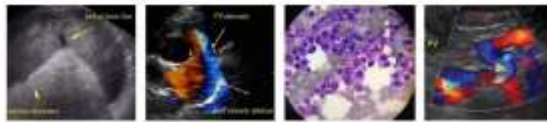
The potential for emerging left adrenal neoplastic or metastatic nodule, however, cannot be technically excluded. Screening blood pressure to assess for evidence of hypertension is recommended.

INVOICE

Assuming no evidence of thoracic pathology on three-view chest radiographs, splenectomy is still a recommendation that should be considered in this case vs. continued conservative sonographic monitoring of the splenic mass, as well as the discreet left adrenal nodule, for evidence of progression.

DATE

3/8/22



PATIENT

Jules Kong

SPECIES

Canine

BREED

Retrvr X

SEX

FS

AGE

12 years

WEIGHT

38.5

INTERPRETED BY

R. McKenzie Daniel,
DVM, DABVP

**IMAGING
PERFORMED BY**

Crystal Hill

HOSPITAL NAME

The Maples AH

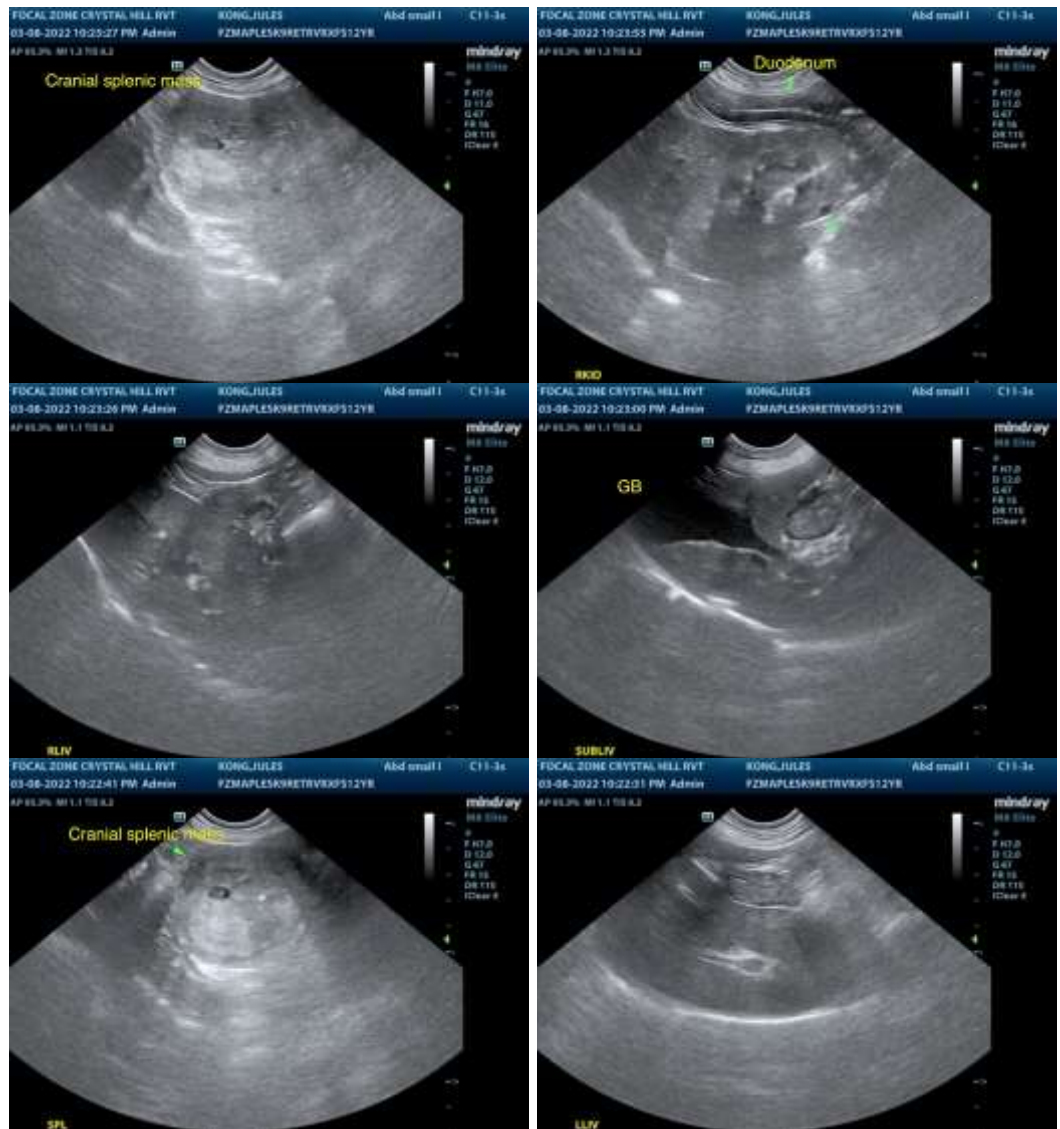
REFERRING VET

Dr. Kazienko

INVOICE

DATE

3/8/22





PATIENT

Jules Kong

SPECIES

Canine

BREED

Retrvr X

SEX

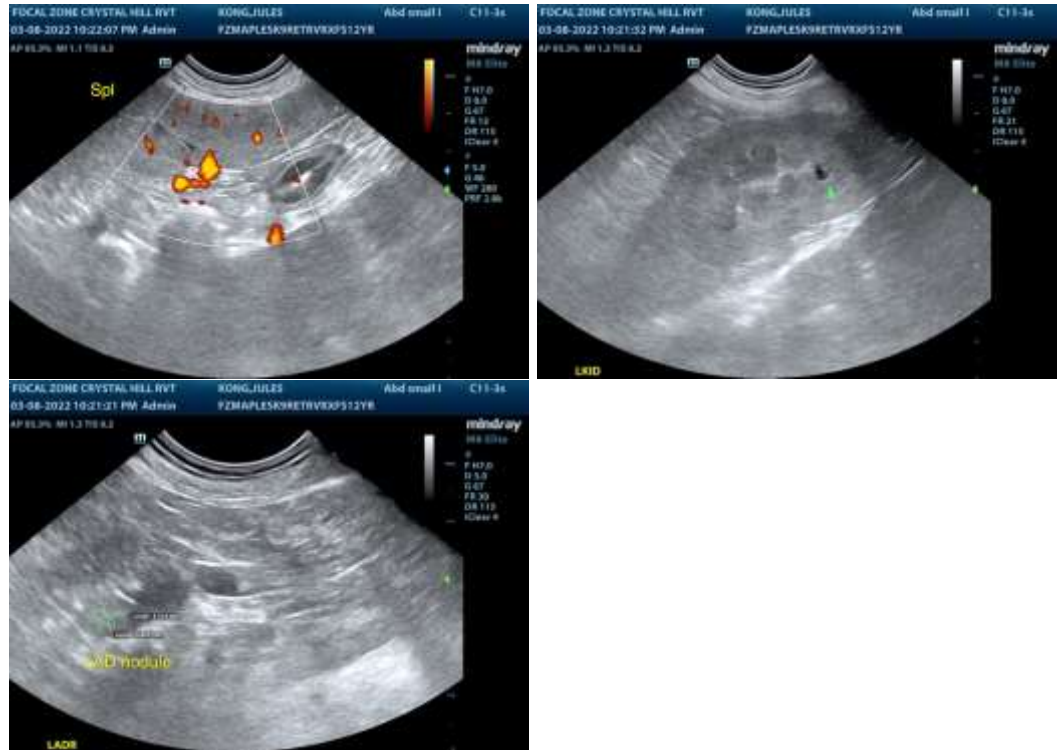
FS

AGE

12 years

WEIGHT

38.5



INTERPRETED BY

R. McKenzie Daniel,
DVM, DABVP

IMAGING PERFORMED BY

Crystal Hill

HOSPITAL NAME

The Maples AH

REFERRING VET

Dr. Kazienko

INVOICE

DATE

3/8/22

The information and recommendations provided are based on the images presented by the referring veterinarian/sonographer. No evaluation can be communicated regarding pathology that was not visible in the image/video clips provided.

Thank you for this referral. If the clinical or image interpretation does not parallel your findings or if I can be of any further assistance please contact me.

R. McKenzie Daniel, DVM, DABVP (Canine / Feline Practice)
info@SonoPath.com