



PATIENT PRESENTING CLINICAL SIGNS

Lacey Volpe History: Elevated liver values, liver supplement

ULTRASONOGRAPHIC EXAMINATION OF THE ABDOMEN

SPECIES

Canine

Urinary System

The urinary bladder, trigone, cystourethral junction, and visible pelvic urethra to a depth of 3.0 cm exhibited normal thickness and tone. Anechoic urine was present in the lumen with no uroliths or sediment. The ureteral papillae were normal. The ureters were not visible which is normal. No evidence of inflammatory or neoplastic changes were noted. Aortic trifurcation was normal.

BREED

Shih X

Normal size and margination were present in the kidneys. A normal 1:3 cortex / medulla ratio was maintained. Mild, nonuniform cortex echogenicity exhibiting indistinct areas of increased cortex echogenicity which may indicate areas of indistinct to minor infarction, fibrosis or emerging mineralization. Mild loss of corticomedullary symmetry and definition, expected for the age of the patient. No evidence of pelvic dilation was present. The left kidney measured 4.7 cm in length. The right kidney measured 5.1 cm in length.

SEX

Spayed Female

AGE

2009

Adrenal Glands

The left adrenal gland was uniform in size and contour with a uniformly hypoechoic parenchyma. The left adrenal gland measured 2.2 cm in length x 0.56 cm width at the caudal pole.

WEIGHT

32 Pounds

The right adrenal gland was uniform in size and contour with a uniformly hypoechoic parenchyma. The right adrenal gland measured 2.3 cm in length x 0.56 cm width at the caudal pole. A mild, well-defined, hyperechoic nodule was present in the mid right adrenal gland, resulting in subtle distortion of the ventral right adrenal capsule yet without evidence of parenchymal escape or vascular invasion. No evidence of mineralization. The nodule measured 0.69 cm x 0.43 cm.

INTERPRETED BY

R. McKenzie Daniel,
 DVM, DABVP
 (Canine and Feline)

Spleen

The spleen was overall normal in size and contour with generalized mild splenic parenchyma heterogeneity. A solitary, non-expansive, nonhomogeneous caudal splenic nodule was present, measuring 0.84 cm in diameter.

IMAGING PERFORMED BY

Rebekah Jakum, CVT
 ARDMS/RVT

Liver

The liver was subjectively normal in size, structure, and contour. The liver parenchyma was mildly nonuniform and hypoechoic to the spleen with a moderate coarse echotexture and subjective mild to benign parenchymal remodeling. The hepatic and portal vasculature were normal in appearance without signs of congestion. Intermittent, indistinct, mildly nonhomogeneous to mixed echogenic minor intraparenchymal nodules were present.

HOSPITAL NAME

Community VP

REFERRING VET

Dr. Carpenter

The gallbladder was non distended in size with mild dependent to nondependent yet nonorganized gallbladder debris. The cystic duct and common bile ducts were normal without evidence of dilation.

INVOICE

14227

Gastrointestinal

The stomach presented intact wall layering with a normal wall layer ratio. The lumen of the stomach was empty with no signs of ileus, obstruction or foreign material.

DATE

3/7/22



PATIENT

Lacey Volpe

The small intestine presented intact wall layering with 1:3 muscularis/mucosa ratio. The lumen of the small intestine was empty with no signs of ileus, obstruction or foreign material.

Normal visible colon wall layers were present with apparent formed feces in lumen.

SPECIES

Canine

Pancreas

The parenchyma of the left limb, body and right limb of the pancreas presented isoechoic to the adjacent omental fat. A normal curvilinear capsule contour of the pancreas was present. The visible pancreatic duct was normal. No signs of active inflammation or neoplastic disease was evident.

BREED

Shih X

Free Abdomen

No overt lymphadenopathy or peritoneal effusion was present.

SEX

Spayed Female

ULTRASONOGRAPHIC FINDINGS

AGE

2009

- Mild chronic renal changes, exhibiting mild nonuniform, nonspecific cortex echogenicity
- Nonspecific, small right adrenal nodule- suspect adenoma
- Nonspecific, caudal splenic nodule
- Chronic hepatopathy- subjectively benign, vacuolar hepatopathy, inflammatory/immune mediated disease, emerging fibrosis, hematopoiesis, nodular hyperplasia possible with neoplasia considered less likely or other hepatopathy
- Mild gallbladder debris (non-mucocele)

WEIGHT

32 Pounds

INTERPRETATION OF THE FINDINGS & FURTHER RECOMMENDATIONS

Possibility of emerging right adrenal neoplasia is considered less likely yet cannot be definitively excluded. Screening blood pressure warranted. Ideally, sonographic reassessment of the small right adrenal nodule with initial recheck in 4-6 weeks to assess for evidence of progression is recommended.

INTERPRETED BY

R. McKenzie Daniel,
DVM, DABVP
(Canine and Feline)

The caudal splenic nodule may suggest focal area of nodular hyperplasia, lipogranuloma, hematopoiesis, small hematoma, previous infarct with emerging neoplasia considered a less likely differential diagnosis. In addition to sonographic reassessment of the right adrenal nodule, sonographic monitoring of the caudal splenic nodule for evidence of progression would be reasonable.

IMAGING PERFORMED BY

Rebekah Jakum, CVT
ARDMS/RVT

HOSPITAL NAME

Community VP

Ultrasound guided FNA of the liver could be considered for screening cytology. The addition of Ursodiol to current hepatosupportive medications may prove beneficial.

REFERRING VET

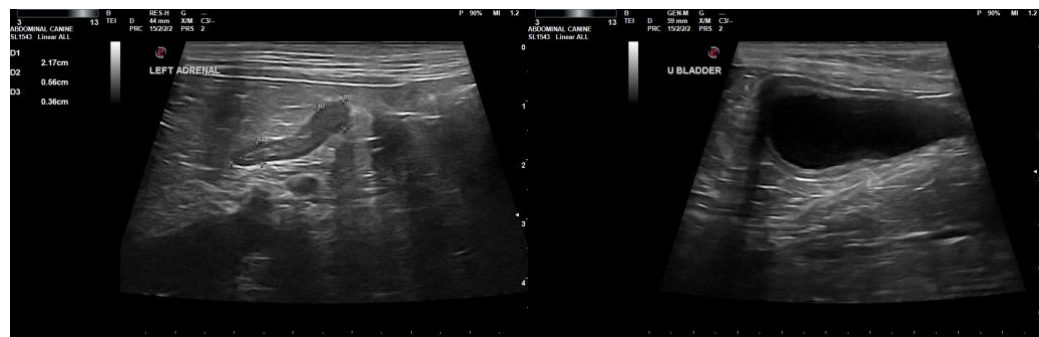
Dr. Carpenter

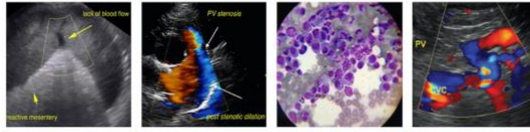
INVOICE

14227

DATE

3/7/22





PATIENT

Lacey Volpe

SPECIES

Canine

BREED

Shih X

SEX

Spayed Female

AGE

2009

WEIGHT

32 Pounds

INTERPRETED BY

R. McKenzie Daniel,
DVM, DABVP
(Canine and Feline)

IMAGING PERFORMED BY

Rebekah Jakum, CVT
ARDMS/RVT

HOSPITAL NAME

Community VP

REFERRING VET

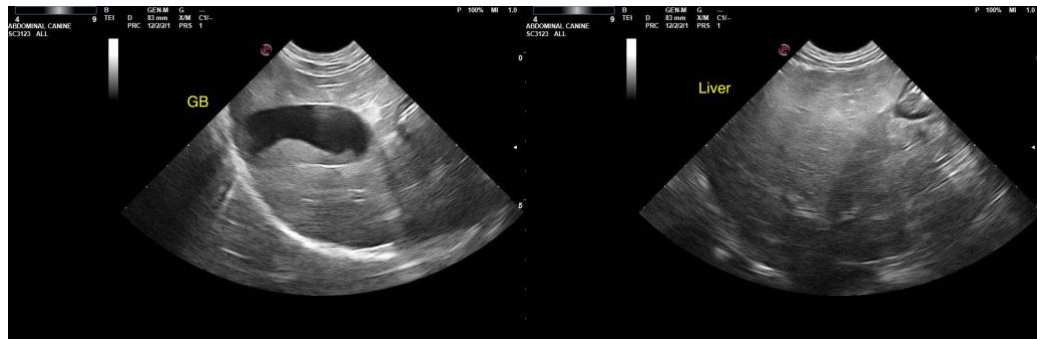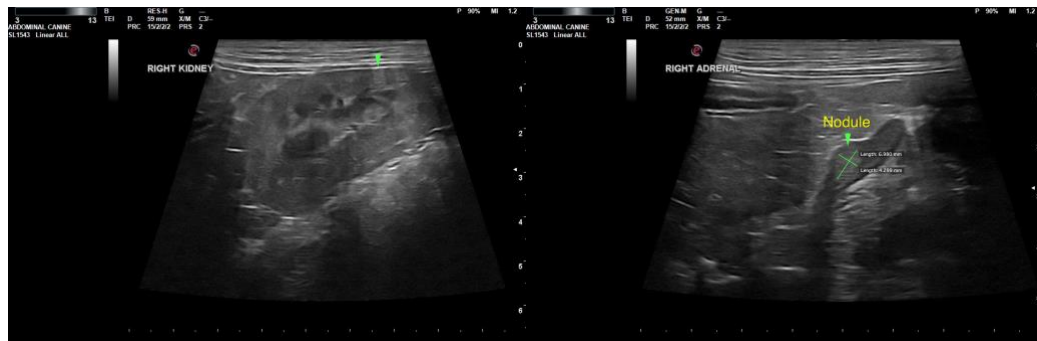
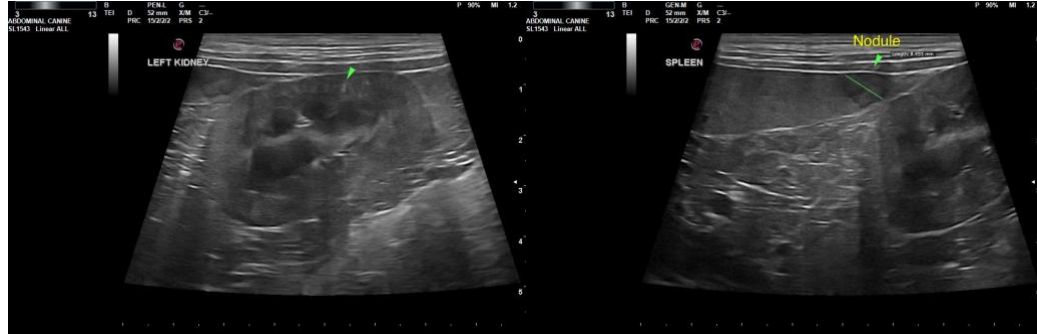Dr. Carpenter

INVOICE

14227

DATE

3/7/22



The information and recommendations provided are based on the images presented by the referring veterinarian. No evaluation can be communicated regarding pathology that was not visible in the image/video clips provided.

Thank you for this referral. If the clinical or image interpretation does not parallel your findings or if I can be of any further assistance please contact me.

R. McKenzie Daniel, DVM, DABVP (Canine/Feline Practice)
mac.daniel@sonopath.com