



PATIENT

Eli Horowitz Moon

SPECIES

Canine

BREED

JRT

SEX

Neutered male

AGE

13 years

WEIGHT

10.8 kg

INTERPRETED BY

R. McKenzie Daniel,
DVM, DABVP
(Canine and Feline)

IMAGING PERFORMED BY

Dr. Amy Hess

HOSPITAL NAME

Petmedic Urgent Care
Veterinty Clinic

REFERRING VET

Dr. Amy Hess

INVOICE

10138ag

DATE

03/06/2022

PRESENTING CLINICAL SIGNS

History: Presented yesterday for acute onset hematemesis BW, rads ok treated with SCF, cerenia and sent home on ondansetron, probiotics At home uncomfortable, not eating, no further vomit AUS today and continued supportive care

Abnormal PE/Chem/CBC/UA Results: Abdominal radiographs normal CBC- wnl Chem- SDMA 20, BUN/Crea normal, ALT 142, otherwise normal CPL normal

ULTRASONOGRAPHIC EXAMINATION OF THE ABDOMEN

Urinary System

The urinary bladder, trigone, cystourethral junction, and visible pelvic urethra to a depth of 3 cm exhibited normal thickness and tone. Anechoic urine was present in the lumen with no uroliths or sediment. The ureteral papillae were normal. The ureters were not visible which is normal. No evidence of inflammatory or neoplastic changes were noted.

Normal size and margination was present in the kidneys. A normal 1:3 cortex / medulla ratio was maintained. The medulla and cortices were uniform in texture with some mildly increased echogenicity and loss of corticomedullary symmetry and definition expected for the age of the patient. Mild pyelectasia was present in the right kidney. The left kidney measured 4.0 cm in length. The right kidney measured 4.6 cm in length.

The area of the aortic trifurcation was free of pathology.

The residual prostate was free of pathology and measured 1.0 cm in diameter.

Adrenal Glands

The left adrenal gland was uniform in size and contour with a uniformly hypoechoic parenchyma. A well-defined, hyperechoic nodule was present in the cranial left adrenal gland with mild associated symmetrical capsule expansion. The nodule did not exhibit signs of mineralization or vascular invasion. The nodule measured 0.68 cm x 0.44 cm. The left adrenal gland measured 0.95 cm width in the cranial pole and 0.72 cm width in the caudal pole. The right adrenal gland was indistinctly visualized yet revealed a likely cranial pole nodule measuring 0.67 cm in diameter. The right adrenal gland measured 0.81 cm width.

Spleen

The spleen exhibited a finely textured and homogenous parenchyma which was hyperechoic to the liver and renal cortical parenchyma. The capsule was smooth and regular without apparent expansion. The splenic vasculature at the hilus was normal in volume with no evidence of congestion or thrombosis. Acute to chronic inflammatory, neoplastic, or benign parenchyma changes were not noted.

Liver

The liver was subjectively normal in size, structure, and contour. A solitary nonexpansive well demarcated mildly hyperechoic parenchymal nodule measuring 1.2 cm in diameter was noted. The liver parenchyma was mildly nonuniform and hypoechoic to the spleen with a moderate coarse echotexture and subjective mild to benign parenchymal remodeling. The hepatic and portal vasculature were normal in appearance without signs of congestion. The gallbladder was non-distended in size with thin walls and primarily anechoic luminal content. The cystic and common bile ducts were normal.



PATIENT

Gastrointestinal

Eli Horowitz Moon

The stomach presented mild wall thickening secondary to echogenic mucosa hypertrophy. Intact wall layering was maintained and distinct. Mild gastric distension with mild retained primarily anechoic fluid was present without overt evidence of retained ingesta or foreign material. The gastric body wall measured 0.49 cm in width.

SPECIES

Canine

The duodenum exhibited intact yet subjective prominent wall layering with nonspecific areas of increased mucosal echogenicity to mucosal speckling. The jejunum and ileum to the level of the colon exhibited intact wall layering with 1:3 muscularis/mucosa ratio with minor segmental concurrent jejunal mucosal speckling. The lumen of the small intestine was empty with no signs of ileus, obstruction or foreign material. The duodenum wall measured 0.54 cm. The jejunum wall measured 0.45 cm.

BREED

JRT

Normal visible colon wall layers were present with apparent formed feces in lumen.

SEX

Neutered male

Pancreas

The pancreas was normal in size and contour with isoechoic to heterogeneous parenchyma compared to adjacent omentum. No signs of active inflammation or neoplasia.

AGE

13 years

Free Abdomen

Regional to segmental peri intestinal reactive mesentery and small pocket of scant free fluid was noted. No evidence of significant lymphadenopathy.

WEIGHT

10.8 kg

ULTRASONOGRAPHIC FINDINGS

INTERPRETED BY

R. McKenzie Daniel,
DVM, DABVP
(Canine and Feline)

- Bilateral nodular adrenal glands-suspect adenomas.
- Mild chronic renal changes with mild right kidney pyelectasia.
- Non specific yet likely benign hepatic nodule-probable lipogranuloma.
- Gastroenteritis pattern with mild gastric hypomotility and moderate duodenitis. Dietary indiscretion/food intolerance with potential for more chronic enteropathies such as IBD are possible.
- Associated regional peri intestinal reactive mesentery and scant free fluid-likely secondary to intestinal inflammation.
- Mild pancreatic remodeling.

IMAGING PERFORMED BY

Dr. Amy Hess

HOSPITAL NAME

INTERPRETATION OF THE FINDINGS & FURTHER RECOMMENDATIONS

Petmedic Urgent Care
Veterinty Clinic

Minor potential for emerging adrenal neoplasia such as pheochromocytoma or adenocarcinoma cannot be definitively excluded yet thought less likely. Screening BP is recommended. Ideally sonographic monitoring of the bilateral adrenal nodules with initial recheck in 4-6 weeks is recommended to rule out nodular progression.

REFERRING VET

Dr. Amy Hess

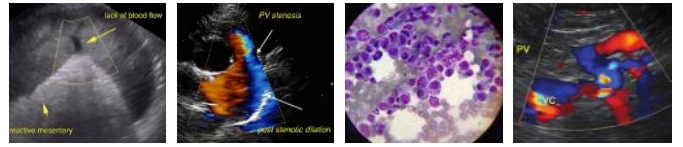
Potential for low grade to chronic pancreatitis cannot be excluded. Continued supportive care would be reasonable with recheck sonogram to assess for progressive inflammatory gastrointestinal changes if clinical signs persist.

INVOICE

10138ag

DATE

03/06/2022



PATIENT

Eli Horowitz Moon

SPECIES

Canine

BREED

JRT

SEX

Neutered male

AGE

13 years

WEIGHT

10.8 kg

INTERPRETED BY

R. McKenzie Daniel,
DVM, DABVP
(Canine and Feline)

IMAGING PERFORMED BY

Dr. Amy Hess

HOSPITAL NAME

Petmedic Urgent Care
Veterinty Clinic

REFERRING VET

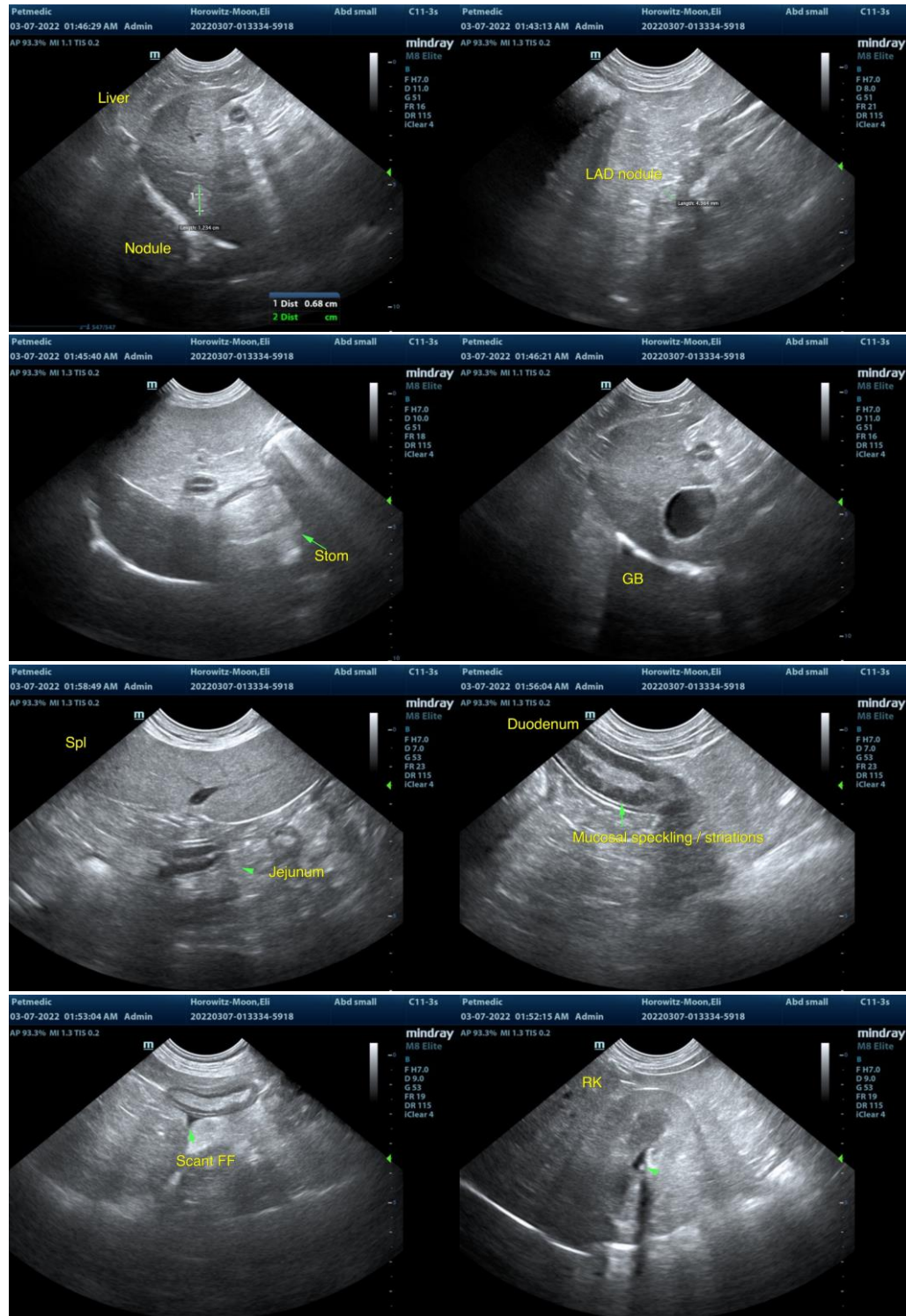
Dr. Amy Hess

INVOICE

10138ag

DATE

03/06/2022





PATIENT

Eli Horowitz Moon

SPECIES

Canine

BREED

JRT

SEX

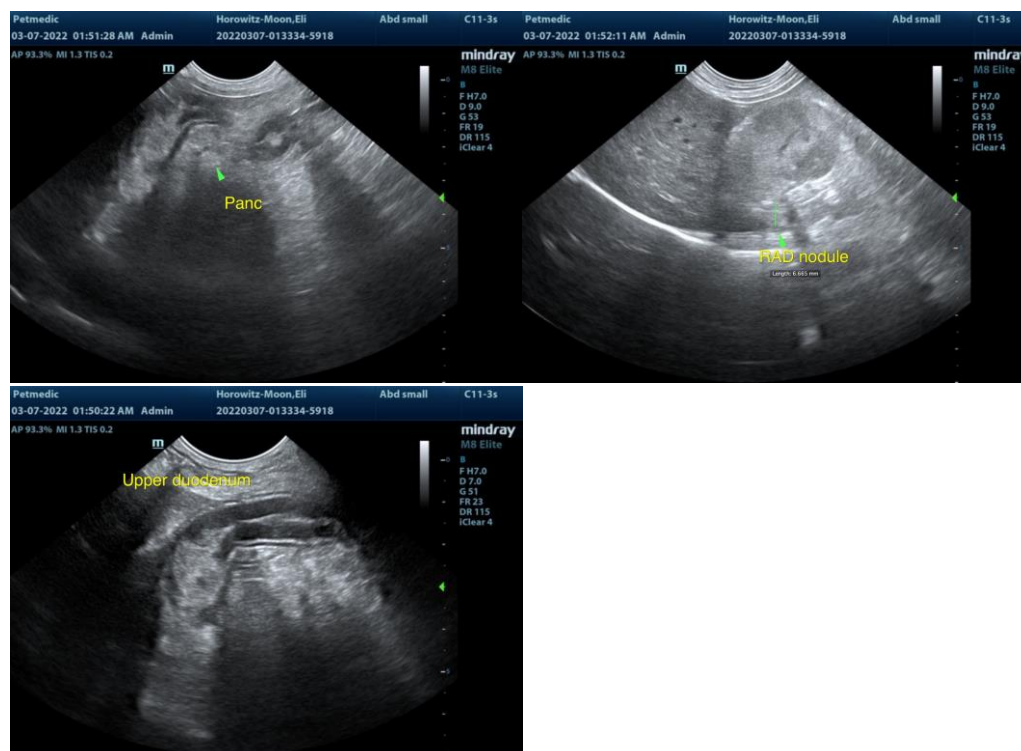
Neutered male

AGE

13 years

WEIGHT

10.8 kg



INTERPRETED BY

R. McKenzie Daniel,
DVM, DABVP
(Canine and Feline)

IMAGING PERFORMED BY

Dr. Amy Hess

HOSPITAL NAME

Petmedic Urgent Care
Veterinty Clinic

REFERRING VET

Dr. Amy Hess

INVOICE

10138ag

DATE

03/06/2022

The information and recommendations provided are based on the images presented by the referring veterinarian/sonographer. No evaluation can be communicated regarding pathology that was not visible in the image/video clips provided.

Thank you for this referral. If the clinical or image interpretation does not parallel your findings or if I can be of any further assistance please contact me.

R. McKenzie Daniel, DVM, DABVP (Canine / Feline Practice)

info@SonoPath.com