



PATIENT

Olive Wellington

SPECIES

K9

BREED

Pug

SEX

FS

AGE

7Y

WEIGHT

19.7lbs

INTERPRETED BY

R. McKenzie Daniel,
DVM, DABVP
(Canine and Feline)

IMAGING PERFORMED BY

Brandon

HOSPITAL NAME

Dillsburg Veterinary
Center

REFERRING VET

Dr. Amber

INVOICE

74051

DATE

3-4-26

PRESENTING CLINICAL SIGNS

pre-op ECG showed mild deviation of the electrical axis, suggestive of cardiac enlargement, but it is also commonly identified as a normal patient variant. Thoracic radiographs were performed, and the heart silhouette in the lateral view appeared subjectively enlarged. The VHS measurement was upper normal range (10.25 (8.7-10.7)). However, the right side of the heart appeared enlarged in the VD view as well. Echo was elected before anesthesia for dental cleaning. No murmur heard.

ULTRASONOGRAPHIC EXAMINATION OF THE HEART

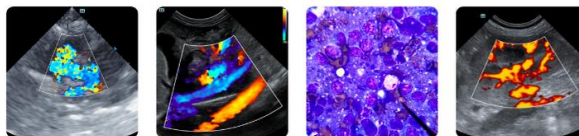
CANINE CARDIAC PARAMETERS	MR VMAX (m/s)	TR VMAX (m/s)	LA/AO M-mode	LA/AO (Heart Base; Swe)	FS (%)	EF (%)	EPSS (cm)
NORMAL PARAMETER	4.5-5.5	<2.7	1.3	Up to 1.6	28-40	40-100	<0.6
PATIENT			--	1.2	40	74	0.25
CANINE CARDIAC PARAMETERS	HR (BPM)	AV VMAX (m/s)	PV MAX (m/s)	BODY WEIGHT (kg)	LAD LA MAX 4 Chamber	LVIDd Avg; 2D and m-mode short axis (cm)	LVIDs Avg; 2D and m-mode short axis (cm)
NORMAL PARAMETER	50-100	0.7-1.7	0.7-1.6				
PATIENT		1.0	0.6	19.7	1.8	2.3	--

Cardiac Presentation

The echocardiogram in this patient demonstrated normal **left atrial** size based on 2 separate methods of LA evaluation. The cranial and caudal **mitral** valve leaflets presented normal linear structure, extension in systole, and union in diastole with normal kinesis. No visualized MR on doppler. The **left ventricle** presented thicknesses with linear contour and was not dilated nor restricted. The **myocardium** presented normal echogenicity without subjective evidence of significant fibrotic or ischemic disease. **Contractility** of the ventricular walls was adequate and in normal range for this patient evidenced by the fractional shortening measurement and subjective evaluation of the different regions of the myocardium. The **left ventricular outflow** tract demonstrated normal laminar flow and subjective structural integrity. The **right atrium** and auricle revealed normal size, structure and content. No evidence of masses was noted. **Tricuspid** valvular assessment demonstrated adequate linear morphology and kinesis. No visualized TR on doppler. The **right ventricle** was of normal size (1/3 diameter of LV), chordae structure, myocardial echogenicity and thickness. **Pulmonary outflow** tract assessment revealed normal valve structure, laminar flow, and diameter (approx.1:1 pa/ao ratio). No visible **pericardial** or free pleura fluid was noted. The cranial **mediastinum and pericardial and extra-cardiac regions** were free of masses in the visible window. No obvious arrhythmia.

ULTRASONOGRAPHIC FINDINGS

- Normal cardiac structure/function.



PATIENT

Olive Wellington

SPECIES

K9

BREED

Pug

SEX

FS

AGE

7Y

WEIGHT

19.7lbs

INTERPRETED BY

R. McKenzie Daniel,
DVM, DABVP
(Canine and Feline)

IMAGING PERFORMED BY

Brandon

HOSPITAL NAME

Dillsburg Veterinary
Center

REFERRING VET

Dr. Amber

INVOICE

74051

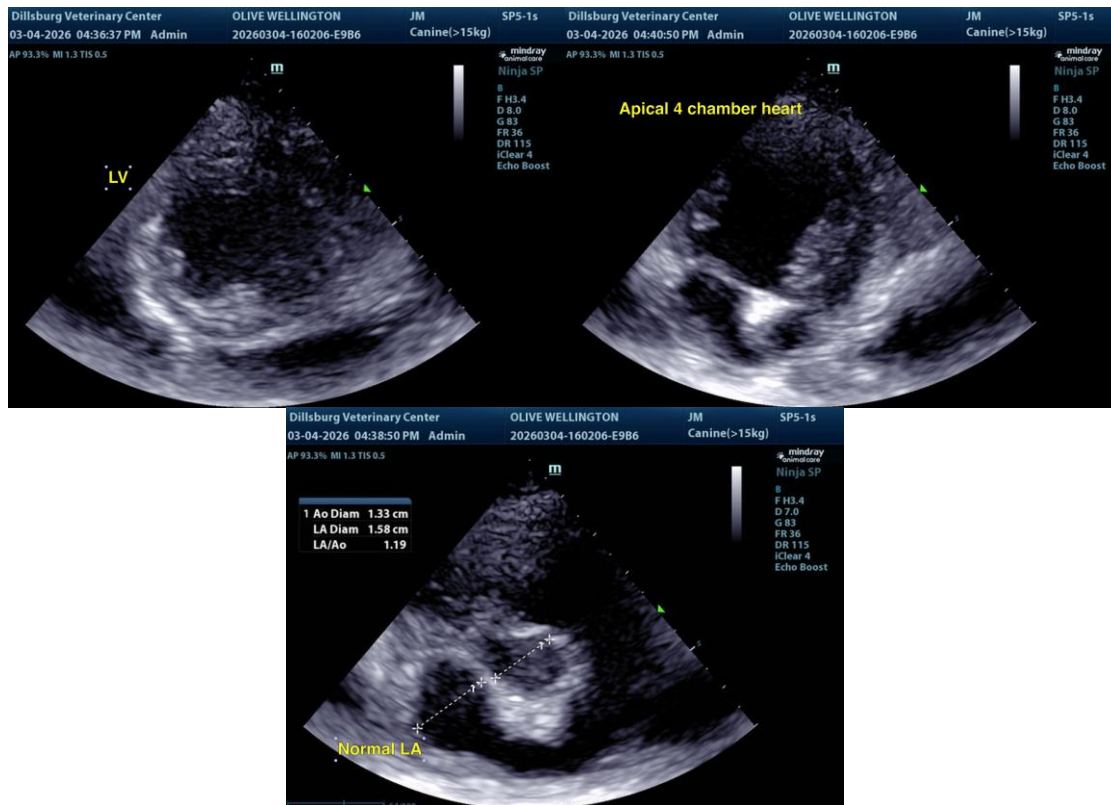
DATE

3-4-26

INTERPRETATION OF THE FINDINGS & FURTHER RECOMMENDATIONS

No evidence of clinical issues such as left or right heart chamber enlargement, LV systolic dysfunction, or arrhythmia. No overt anesthetic contraindications based on this study.

Suggested anesthetic protocol may include opioid or Benzodiazepine pre-med, induction with Propofol or Alfaxalone, and appropriate gas anesthesia with avoidance of alpha 2 agonists.



The information and recommendations provided are based on the images presented by the referring veterinarian/sonographer. No evaluation can be communicated regarding pathology that was not visible in the image/video clips provided.

Thank you for this referral. If the clinical or image interpretation does not parallel your findings or if I can be of any further assistance please contact me.

R. McKenzie Daniel, DVM, DABVP (Canine/Feline Practice)
info@sonopath.com