



## PATIENT

Avery Cushway

## SPECIES

Canine

## BREED

Labrador Retriever

## SEX

Female Intact

## AGE

4y 4m

## WEIGHT

55 lbs

## INTERPRETED BY

R. McKenzie Daniel,  
DVM, DABVP  
(Canine and Feline)

## IMAGING PERFORMED BY

Amanda Crook

## HOSPITAL NAME

River's  
Edge PMC

## REFERRING VET

Dr. David Gray

## INVOICE

13252

## DATE

3/4/26

## PRESENTING CLINICAL SIGNS

Submitted study contained images focusing on the reproductive tract, small intestine, colon and urinary bladder

History:

- 9 DAYS AGO PUPPIES DYSTOCIA NOW DIARRHEA AND ANO

Abnormal PE/Chem/CBC/UA Results: Calcium WNL no rads at this time

## LIMITED ULTRASONOGRAPHIC EXAMINATION OF THE ABDOMEN

### Urinary System

The urinary bladder, trigone, cystourethral junction, and visible pelvic urethra to a depth of 3.0 cm exhibited normal thickness and tone. Anechoic urine was present in the lumen with no uroliths or sediment. The ureteral papillae were normal. The ureters were not visible which is normal. No evidence of inflammatory or neoplastic changes were noted.

The uterus exhibited mild prominent size containing primarily mild, hyperechoic, non-shadowing lumen content. Intact mild prominent uterine wall measured 0.5 cm width. Subtle peri-uterine mild, hyperechoic mesentery without evidence of peri-uterine or peridermal effusion.

The left and right ovaries were sonographically normal. The right ovary measured 1.7 cm in diameter. The left ovary measured 1.6 cm in diameter.

### Gastrointestinal

The visualized segments of the small intestine presented intact wall layering with 1:3 muscularis/mucosa ratio. The lumen of the small intestine was empty with no signs of ileus, obstruction or foreign material.

Normal visible colon wall layers were present with apparent semi-formed to soft feces in lumen.

### Free Abdomen

Intermittent, mildly prominent to enlarged mesenteric node was present. The lymph node was essentially isoechoic to adjacent omentum without evidence of peripheral inflammation and maintaining a normal width: length ratio (<0.5).

## ULTRASONOGRAPHIC FINDINGS

- Normal postpartum uterus vs emerging postpartum metritis
- Normal urinary bladder and visible proximal urethra
- Normal visualized small intestine/colon with semi-formed to soft fecal matter
- Intermittent, mild benign mesenteric lymphadenopathy

## INTERPRETATION OF THE FINDINGS & FURTHER RECOMMENDATIONS

Monitoring for vaginal discharge is recommended if present. C/S of vaginal discharge including anaerobic/aerobic testing is recommended. Gastrointestinal support and consideration for empirical therapy for potential emerging postpartum metritis is recommended. Sonographic reassessment or



**PATIENT**

Avery Cushway

**SPECIES**

Canine

**BREED**

Labrador Retriever

**SEX**

Female Intact

**AGE**

4y 4m

**WEIGHT**

55 lbs

**INTERPRETED BY**

R. McKenzie Daniel,  
DVM, DABVP  
(Canine and Feline)

**IMAGING PERFORMED BY**

Amanda Crook

**HOSPITAL NAME**

River's  
Edge PMC

**REFERRING VET**

Dr. David Gray

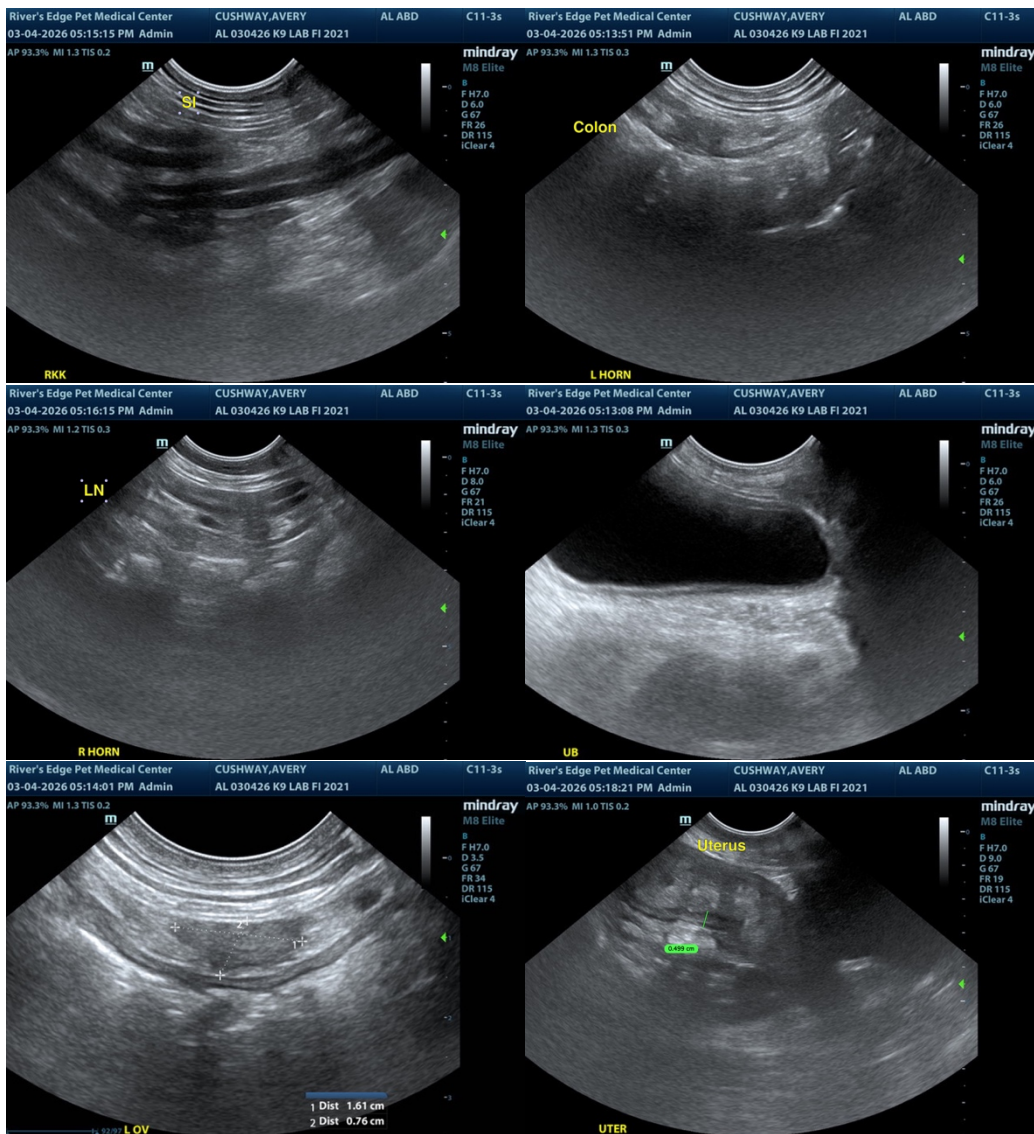
**INVOICE**

13252

**DATE**

3/4/26

monitoring of the uterus indicated if progressive clinical signs or vaginal discharge. No overt evidence of retained fetus.





## PATIENT

Avery Cushway

## SPECIES

Canine

## BREED

Labrador Retriever

## SEX

Female Intact

## AGE

4y 4m

## WEIGHT

55 lbs

## INTERPRETED BY

R. McKenzie Daniel,  
DVM, DABVP  
(Canine and Feline)

## IMAGING PERFORMED BY

Amanda Crook

## HOSPITAL NAME

River's  
Edge PMC

## REFERRING VET

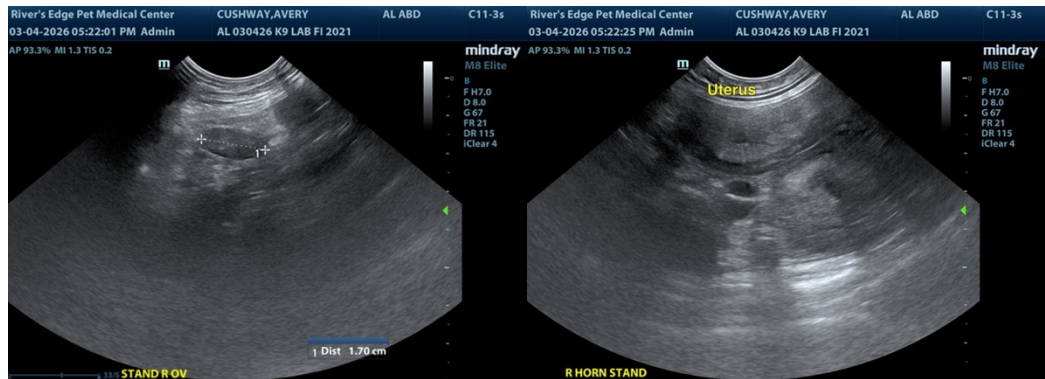
Dr. David Gray

## INVOICE

13252

## DATE

3/4/26



The information and recommendations provided are based on the images presented by the referring veterinarian/sonographer. No evaluation can be communicated regarding pathology that was not visible in the image/video clips provided.

Thank you for this referral. If the clinical or image interpretation does not parallel your findings or if I can be of any further assistance, please contact me.

R. McKenzie Daniel, DVM, DABVP (Canine / Feline Practice)

[info@sonopath.com](mailto:info@sonopath.com)