



PATIENT PRESENTING CLINICAL SIGNS

Boots Rennick Had lost weight unintentionally, but it has been gained back. Resorptive oral lesions. Grade I/VI systolic murmur. BP: 142,143 mmHg. Having bi-cavity ultrasound exams.
SPECIES Abnormal PE/Chem/CBC/UA Results: Chol 370, RBC 11.5, Hemo 15.9; HCT 15.9; plat 55; USG 1.068, protein 1+, WBC 0-1, squam epith 2-3

Feline

ULTRASONOGRAPHIC EXAMINATION OF THE ABDOMEN

BREED

Urinary System

DSH

The urinary bladder, trigone, cystourethral junction, and visible pelvic urethra exhibited normal thickness and tone. Anechoic urine was present in the lumen with no uroliths or sediment. The ureteral papillae were normal. The ureters were not visible which is normal. No evidence of inflammatory or neoplastic changes were noted.

SEX

MN

No evidence of pathology in the area of the aortic trifurcation.

AGE

2 Years

Normal size and margination were present in the kidneys. A normal 1:3 cortex / medulla ratio and normal corticomedullary definition were maintained. The echogenicity of the cortex was similar to or slightly less than normal liver parenchyma while the medulla echogenicity was hypoechoic to the cortex with no evidence of pelvic dilation. The left kidney measured 4.3 cm in length. The right kidney measured 4.2 cm in length.

WEIGHT

11 lbs

Adrenal Glands

The left adrenal gland was uniform in size and contour with a uniformly hypoechoic parenchyma. The left adrenal gland measured 0.31 cm. The right adrenal gland was uniform in size and contour with a uniformly hypoechoic parenchyma. The right adrenal gland measured 0.40 cm.

INTERPRETED BY

Spleen

R. McKenzie Daniel, DVM,
 DABVP (Canine and
 Feline)

The spleen exhibited a finely textured and homogenous parenchyma which was hyperechoic to the liver and renal cortical parenchyma. The capsule was smooth and regular without apparent expansion. The splenic vasculature at the hilus was normal in volume with no evidence of congestion or thrombosis. Acute to chronic inflammatory, neoplastic, or benign parenchyma changes were not noted. The spleen measured 0.83 cm width at the level of the hilus.

IMAGING PERFORMED BY

Liver

Pamela Harrigan, RDCS

The liver was subjectively normal in size, structure, and contour. The liver parenchyma was uniform and hypoechoic to the spleen with a mild coarse echotexture. The hepatic and portal vasculature were normal in appearance without signs of congestion.

HOSPITAL NAME

Rhode Island Animal
 Medical Center

The gallbladder was non distended in size with mild echogenic, nonmineralized gallbladder debris primarily in the caudal lumen and gallbladder neck. The cystic duct and common bile ducts were normal without evidence of dilation.

REFERRING VET

Rachel Rogoff, DVM

Gastrointestinal

INVOICE

50734

The stomach presented intact wall layering with a normal wall layer ratio. The lumen of the stomach was empty with no signs of ileus, obstruction or foreign material. The gastric body wall measured 0.25 cm width.

DATE

3-4-22

The small intestine presented intact wall layering with 1:3 muscularis/mucosa ratio. The lumen of the small intestine was empty with no signs of ileus, obstruction, or foreign material. The duodenum wall



PATIENT

Boots Rennick

measured 0.25 cm width. The jejunum wall measured 0.23 cm width. The ileocolic wall measured 0.28 cm width.

Normal visible colon wall layers were present with apparent formed feces in lumen.

SPECIES

Pancreas

Feline

The parenchyma of the left limb, body and right limb of the pancreas presented isoechoic to the adjacent omental fat. A normal curvilinear capsule contour of the pancreas was present. The visible pancreatic duct was normal. No signs of active inflammation or neoplastic disease was evident.

BREED

DSH

Free Abdomen

Intermittent, mildly prominent to enlarged colic lymph nodes were present. The lymph nodes were essentially isoechoic to adjacent omentum without evidence of peripheral inflammation and maintaining a normal width: length ratio (<0.5).

SEX

MN

No other evidence of additional or significant lymphadenopathy and no evidence peritoneal free fluid was present.

AGE

2 Years

ULTRASONOGRAPHIC FINDINGS

Primary

- Overtly normal gastrointestinal tract.
- Mild colic lymphadenopathy - subjectively benign, mild lymphoid hyperplasia or anagenic stimulation likely, no evidence of lymphatic, neoplastic, or inflammatory criteria.

WEIGHT

11 lbs

INTERPRETATION OF THE FINDINGS & FURTHER RECOMMENDATIONS

Overtly normal abdomen without evidence of significant visceral pathology as an obvious cause of the patient's previous weight loss or anemia.

CBC pathology review, recheck retroviral status, and/or infectious disease serology could be considered.

If recurrent weight loss, a GI panel to include PLI/TLI/Cobalamin/Folate as well as three view chest radiographs to rule out occult thoracic pathology is recommended.

INTERPRETED BY

R. McKenzie Daniel, DVM,
 DABVP (Canine and
 Feline)

IMAGING PERFORMED BY

Pamela Harrigan, RDMS

HOSPITAL NAME

Rhode Island Animal
 Medical Center

REFERRING VET

Rachel Rogoff, DVM

INVOICE

50734

DATE

3-4-22



PATIENT

Boots Rennick

SPECIES

Feline

BREED

DSH

SEX

MN

AGE

2 Years

WEIGHT

11 lbs

INTERPRETED BY

R. McKenzie Daniel, DVM,
 DABVP (Canine and
 Feline)

**IMAGING
 PERFORMED BY**

Pamela Harrigan, RDCS

HOSPITAL NAME

Rhode Island Animal
 Medical Center

REFERRING VET

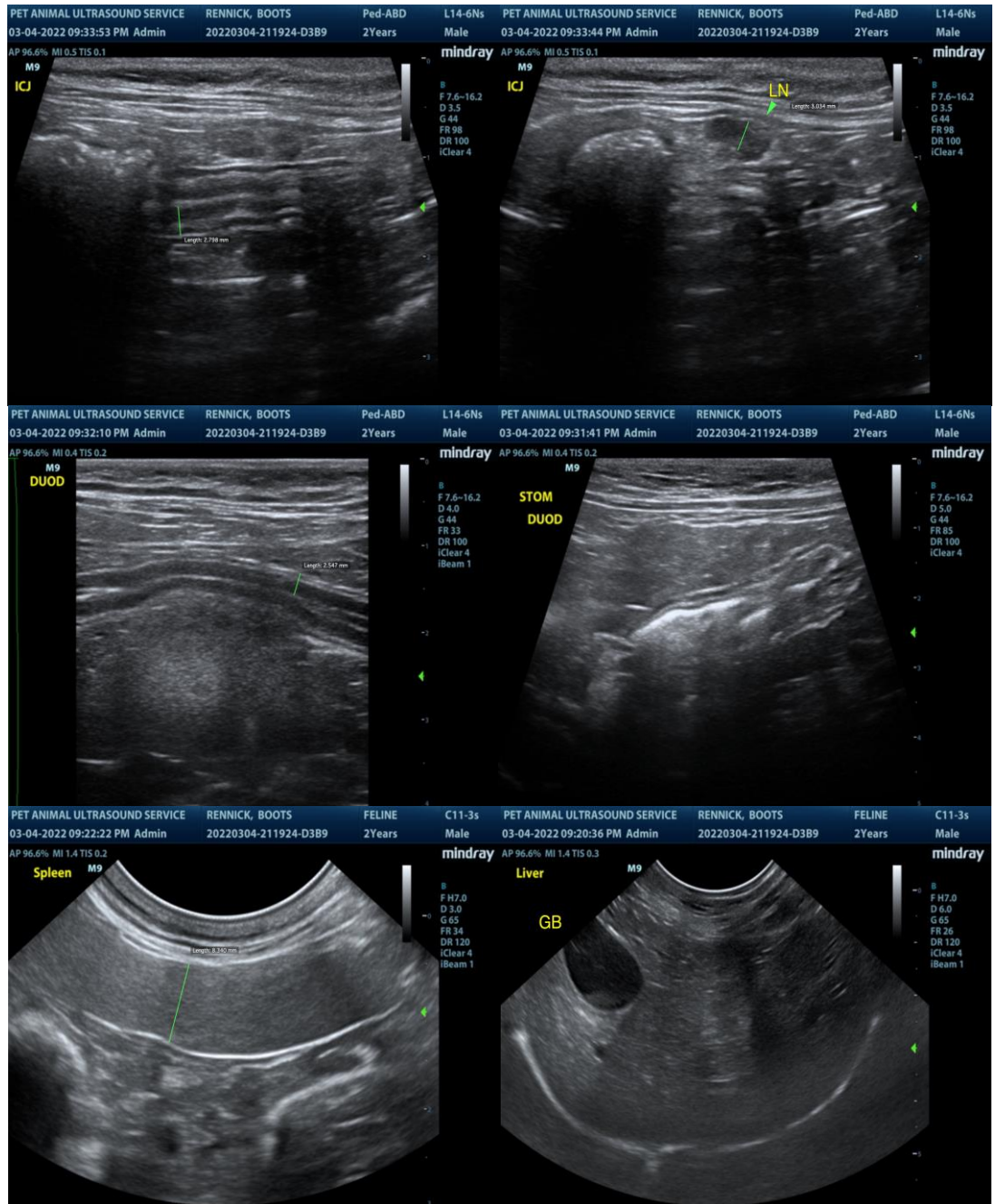
Rachel Rogoff, DVM

INVOICE

50734

DATE

3-4-22





PATIENT

Boots Rennick

SPECIES

Feline

BREED

DSH

SEX

MN

AGE

2 Years

WEIGHT

11 lbs

INTERPRETED BY

R. McKenzie Daniel, DVM,
 DABVP (Canine and
 Feline)

**IMAGING
 PERFORMED BY**

Pamela Harrigan, RDCS

HOSPITAL NAME

Rhode Island Animal
 Medical Center

REFERRING VET

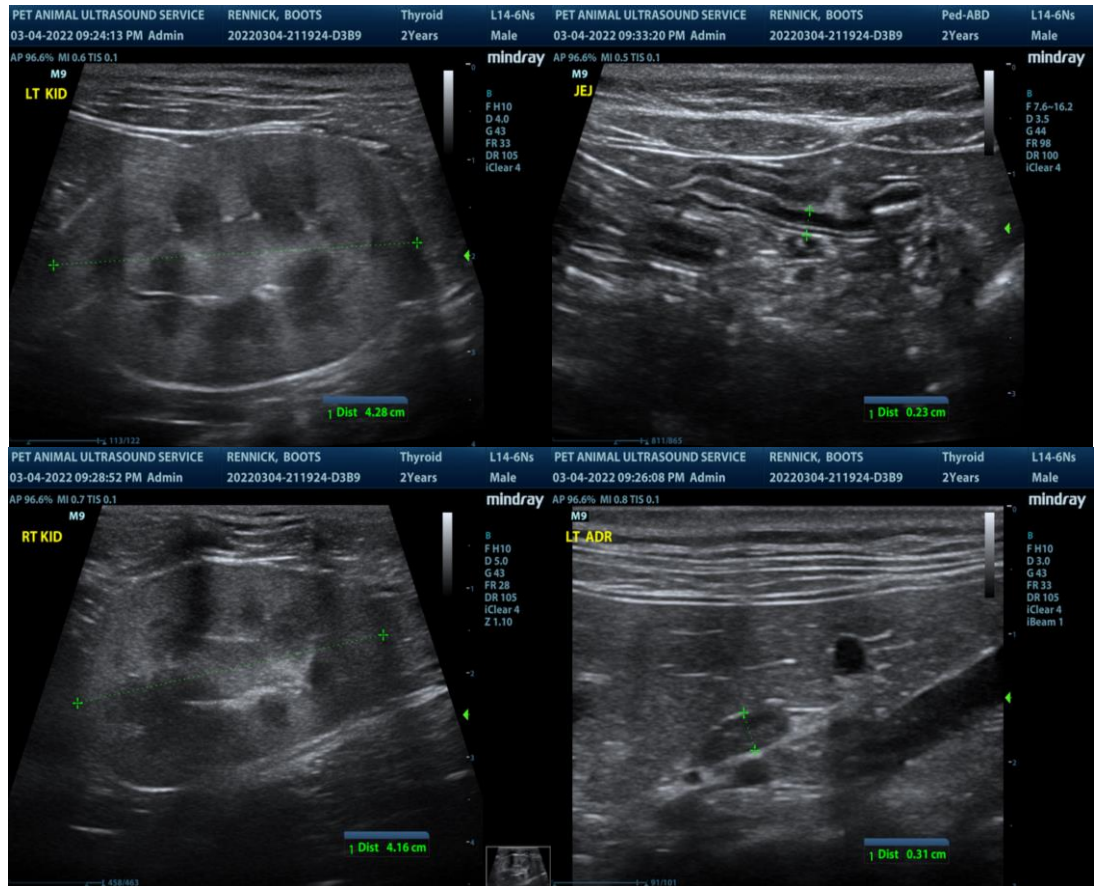
Rachel Rogoff, DVM

INVOICE

50734

DATE

3-4-22



The information and recommendations provided are based on the images presented by the referring veterinarian/sonographer. No evaluation can be communicated regarding pathology that was not visible in the image/video clips provided.

Thank you for this referral. If the clinical or image interpretation does not parallel your findings or if I can be of any further assistance please contact me.

R. McKenzie Daniel, DVM, DABVP (Canine / Feline Practice)
 info@SonoPath.com