



PATIENT	PRESENTING CLINICAL SIGNS
Cain Pagano	Hematuria, no current meds.
SPECIES	Abnormal PE/Chem/CBC/UA Results: cbc/chem-pending. U/A- Free catch, Dk yellow, cloudy, PH 6.5; Ketones 15 (glucose negative), Prot 30; USG >1.050; Rbc >50/hpf; wbc 3/hpf; Bld 250
Canine	ULTRASONOGRAPHIC EXAMINATION OF THE ABDOMEN
BREED	Urinary System
German Shepherd	The urinary bladder, trigone, cystourethral junction, and visible pelvic urethra to a depth of 5 cm exhibited normal thickness and tone. Anechoic urine was present in the lumen with no uroliths or sediment. The ureteral papillae were normal. The ureters were not visible which is normal. No evidence of inflammatory or neoplastic changes were noted.
SEX	Normal size and margination were present in the kidneys. A normal 1:3 cortex / medulla ratio and normal corticomedullary definition were maintained. The echogenicity of the cortex was similar to or slightly less than normal liver parenchyma while the medulla echogenicity was hypoechoic to the cortex with no evidence of pelvic dilation. The left kidney measured 7.4 cm in length. The right kidney measured 7.4 cm in length.
MI	The area of the aortic trifurcation was free of pathology.
AGE	The area of the iliac trifurcation was free of pathology including no evidence of medial, iliac or sublumbar lymphadenopathy.
6yr	The prostate was enlarged in size with intact, symmetrical capsule contour. The margins of the gland were intact and able to be differentiated from the surrounding tissue. The prostatic parenchyma was mildly echogenic to heteroechoic without parenchymal mineralization. The prostate measured 5.2 cm x 4.6 cm. Anechoic, thinly walled intraparenchymal cysts were present. An example measured 1.9 cm diameter.
WEIGHT	The bilateral testicles were sonographically unremarkable.
76.4lb	
INTERPRETED BY	Adrenal Glands
R. McKenzie Daniel, DVM, DABVP (Canine and Feline)	The left and right adrenal glands were not definitively visualized. No obvious pathology was present in the area of the bilateral adrenal glands.
IMAGING PERFORMED BY	Spleen
Shari Reffi CVT	The spleen exhibited a finely textured and homogenous parenchyma which was hyperechoic to the liver and renal cortical parenchyma. The capsule was smooth and regular without apparent expansion. The splenic vasculature at the hilus was normal in volume with no evidence of congestion or thrombosis. Acute to chronic inflammatory, neoplastic, or benign parenchyma changes were not noted.
HOSPITAL NAME	Liver/Gallbladder
Shohola Veterinary Hospital	The liver was subjectively normal in size, structure, and contour. The liver parenchyma was uniform and hypoechoic to the spleen with a mild coarse echotexture. The hepatic and portal vasculature were normal in appearance without signs of congestion. The gallbladder was non-distended in size with thin walls and primarily anechoic luminal content. The cystic and common bile ducts were normal.
REFERRING VET	Gastrointestinal
Dr. DeMeo	
INVOICE	
13358ag	
DATE	
03/31/2023	



PATIENT

Cain Pagano

The stomach presented intact wall layering with a normal wall layer ratio. The lumen of the stomach was empty with no signs of ileus, obstruction or foreign material.

SPECIES

Canine

The small intestine presented intact wall layering with 1:3 muscularis/mucosa ratio. The lumen of the small intestine was empty with no signs of ileus, obstruction or foreign material.

Normal visible colon wall layers were present with apparent formed feces in lumen.

Pancreas

BREED

German Shepherd

The parenchyma of the left limb, body and right limb of the pancreas presented isoechoic to the adjacent omental fat. A normal curvilinear capsule contour of the pancreas was present. The visible pancreatic duct was normal. No signs of active inflammation or neoplastic disease was evident.

SEX

MI

Free Abdomen

No omental masses, overt lymphadenopathy or peritoneal effusion was present.

ULTRASONOGRAPHIC FINDINGS

AGE

6yr

- Sonographically unremarkable urinary bladder and visible urethra.
- Benign prostatic hyperplasia with intraparenchymal cyst, potential for mild prostatitis or less likely emerging prostatic abscess.
- Normal bilateral kidneys-no evidence of pyelonephritis.

WEIGHT

76.4lb

INTERPRETATION OF THE FINDINGS & FURTHER RECOMMENDATIONS

A C/S on a sterile urine sample is recommended if not recently done. Prostatic sampling via prostatic wash or ultrasound guided FNA for cytology +/- C/S is required for further definition. No evidence of upper/lower urinary tract or prostatic neoplastic criteria. Non-visualized urethral pathology or uncommon condition such as idiopathic renal hematuria cannot be definitively excluded yet considered less likely.

Neutering or pending additional diagnostics, empirical therapy for prostatitis +/- off label finasteride with assessment of response and sonographic monitoring of the prostate could be considered.

INTERPRETED BY

R. McKenzie Daniel,
DVM, DABVP
(Canine and Feline)

IMAGING PERFORMED BY

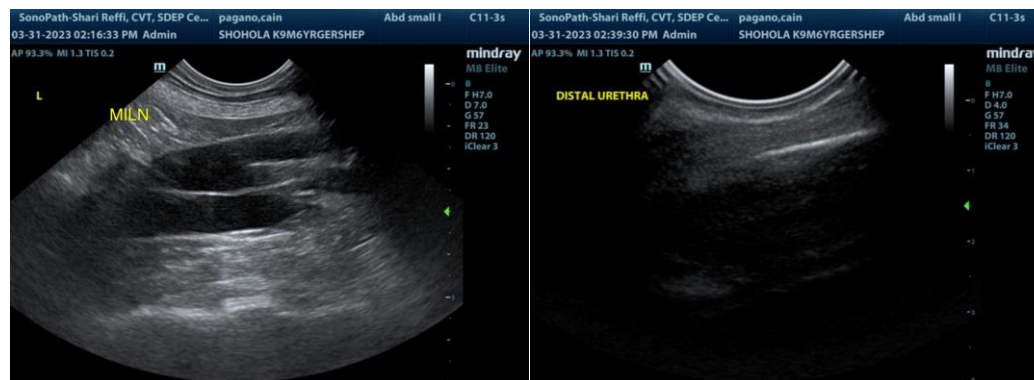
Shari Reffi CVT

HOSPITAL NAME

Shohola Veterinary
Hospital

REFERRING VET

Dr. DeMeo



INVOICE

13358ag

DATE

03/31/2023



PATIENT

Cain Pagano

SPECIES

Canine

BREED

German Shepherd

SEX

MI

AGE

6yr

WEIGHT

76.4lb

INTERPRETED BY

R. McKenzie Daniel,
DVM, DABVP
(Canine and Feline)

IMAGING PERFORMED BY

Shari Reffi CVT

HOSPITAL NAME

Shohola Veterinary
Hospital

REFERRING VET

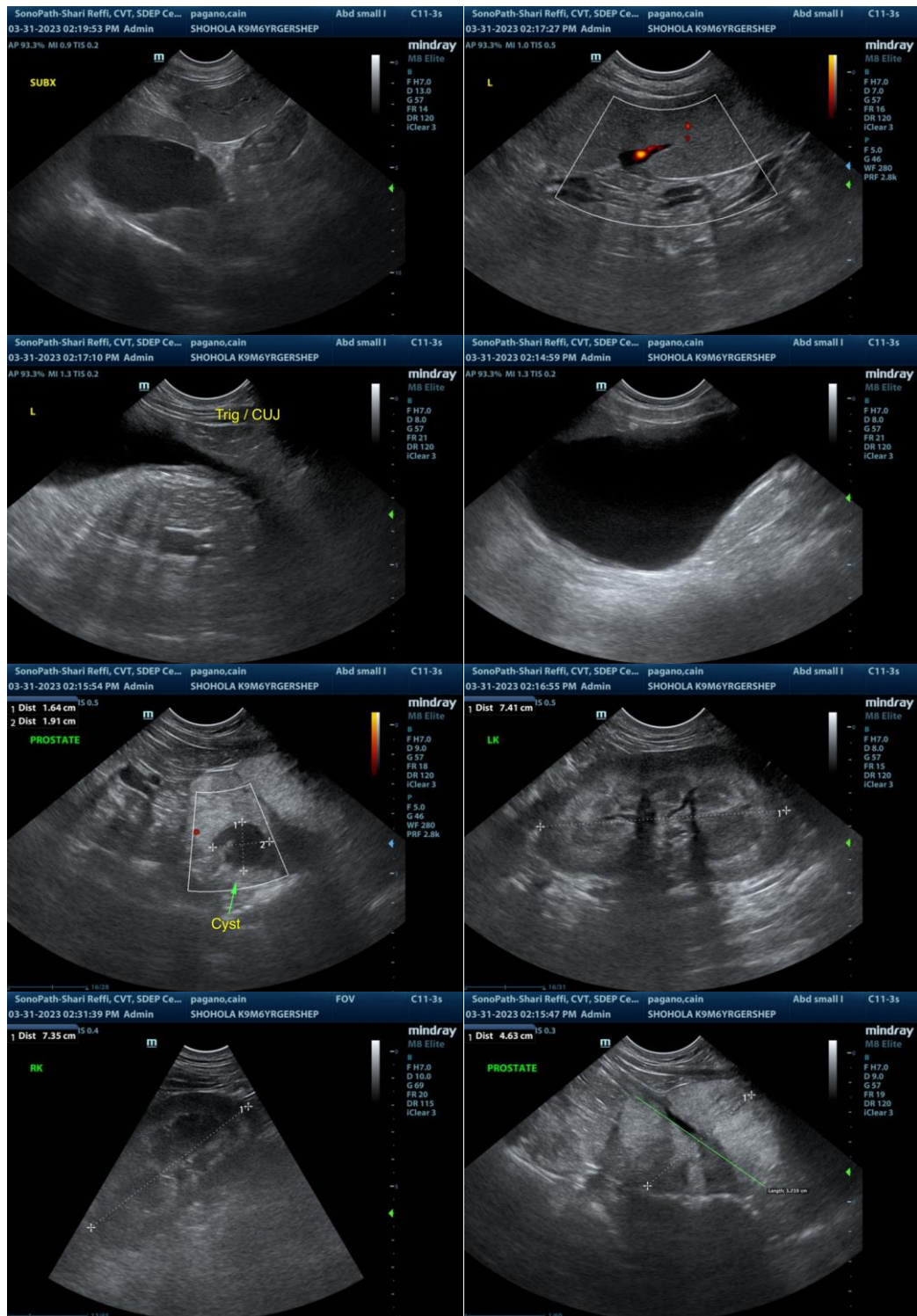
Dr. DeMeo

INVOICE

13358ag

DATE

03/31/2023



The information and recommendations provided are based on the images presented by the referring veterinarian/sonographer. No evaluation can be communicated regarding pathology that was not visible in the image/video clips provided.

Thank you for this referral. If the clinical or image interpretation does not parallel your findings or if I



PATIENT

can be of any further assistance, please contact me.

Cain Pagano

SPECIES

R. McKenzie Daniel, DVM, DABVP (Canine/Feline Practice)

mac.daniel@sonopath.com

Canine

BREED

German Shepherd

SEX

MI

AGE

6yr

WEIGHT

76.4lb

INTERPRETED BY

R. McKenzie Daniel,
DVM, DABVP
(Canine and Feline)

**IMAGING
PERFORMED BY**

Shari Reffi CVT

HOSPITAL NAME

Shohola Veterinary
Hospital

REFERRING VET

Dr. DeMeo

INVOICE

13358ag

DATE

03/31/2023