

PATIENT PRESENTING CLINICAL SIGNS

Queenie Teich

- Grade 2/6 HM noted on L side.
- Bilateral stage 2 MLP. Tibial thrust noted of L stifle. NWB lameness of LH. M1 sarcopenia of L hamstring.

SPECIES

Canine

- Current Medications Metacam suspension - 0.3ml by mouth once daily

ULTRASONOGRAPHIC EXAMINATION OF THE HEART

BREED

Chi Mix

SEX

FS

AGE

10yr

WEIGHT

4.37kg

CANINE CARDIAC PARAMETERS	MR VMAX (m/s)	TR VMAX (m/s)	LA/AO M-mode	LA/AO (Heart Base; Swe)	FS (%)	EF (%)	EPSS (cm)
NORMAL PARAMETER	4.5-5.5	<2.7	1.3	Up to 1.6	28-40	40-100	<0.6
PATIENT	5.5	<2.0	--	1.1	52	85	0.2
CANINE CARDIAC PARAMETERS	HR (BPM)	AV VMAX (m/s)	PV MAX (m/s)	BODY WEIGHT	LAD LA MAX 4 Chamber	LVIDd Avg; 2D and m-mode short axis (cm)	LVIDs Avg; 2D and m-mode short axis (cm)
NORMAL PARAMETER	50-100	0.7-1.7	0.7-1.6				
PATIENT	124	1.2	1.0	4.37kg	2.1	2.2	--

Cardiac Presentation

INTERPRETED BY

R. McKenzie Daniel, DVM, DABVP (Canine and Feline)

IMAGING PERFORMED BY

Kelly Reschny

HOSPITAL NAME
Beattie PH Stoney Creek

REFERRING VET

Song

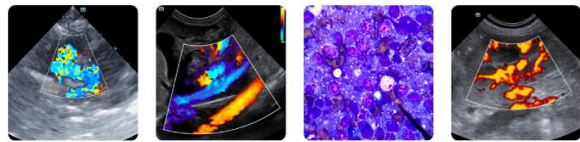
INVOICE
24352

DATE
03/30/2026

ULTRASONOGRAPHIC FINDINGS

Primary

- Chronic mitral valve disease (B1)



PATIENT

- Minor TV insufficiency- no clinical pulmonary hypertension

Queenie Teich

INTERPRETATION OF THE FINDINGS & FURTHER RECOMMENDATIONS

SPECIES

The cause of the murmur is subjective mild chronic degenerative valvular changes with secondary MR. No evidence of additional issues such as DCM criteria, LV systolic dysfunction or clinical pulmonary hypertension. The lack of left atrial enlargement implies that the risk of complication secondary to mitral valve insufficiency is relatively low at this time and, without current clinical signs, indicates that medical therapy is not required at this stage. Prognosis at this stage is variable and serial sonographic monitoring is recommended with a recheck echocardiogram in 6 months, sooner if clinical signs suggestive of heart disease develop.

Canine

BREED

Chi Mix

SEX

Anesthetic risk is considered low. Suggested anesthetic protocol may include opioid or Benzodiazepine pre-med, induction with Propofol or Alfaxalone, and appropriate gas anesthesia with avoidance of alpha 2 agonists.

FS

AGE

10yr

WEIGHT

4.37kg

INTERPRETED BY

R. McKenzie Daniel,
 DVM, DABVP
 (Canine and Feline)

IMAGING PERFORMED BY

Kelly Reschny

HOSPITAL NAME
 Beattie PH Stoney
 Creek

REFERRING VET

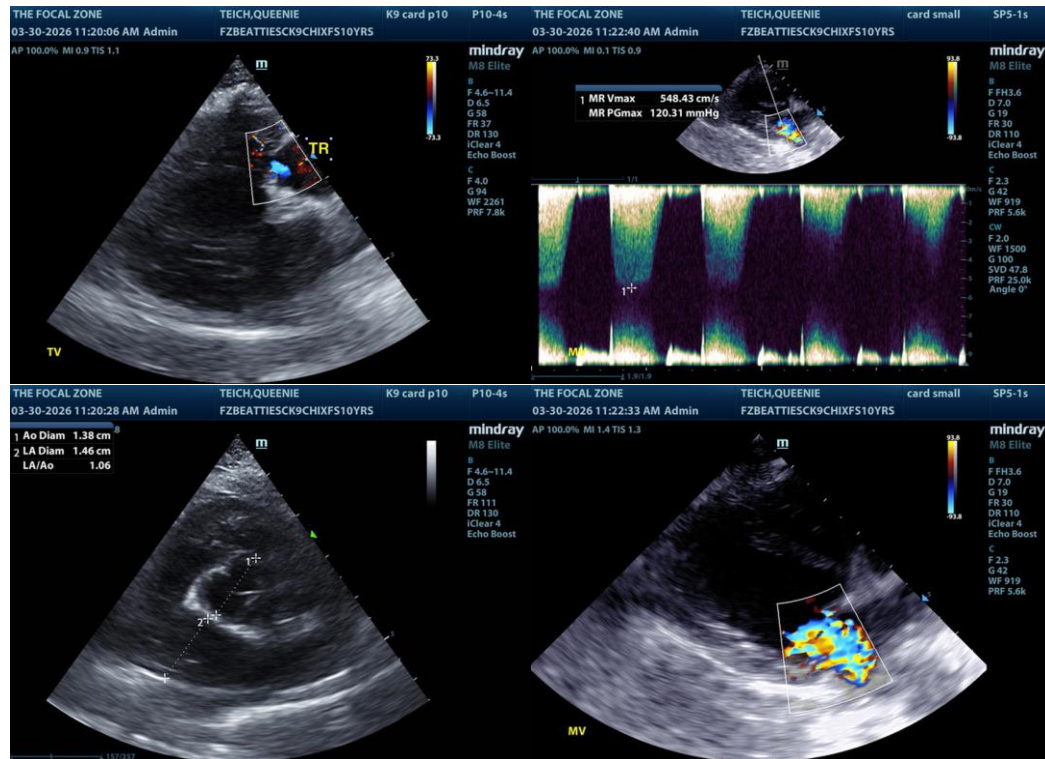
Song

INVOICE

24352

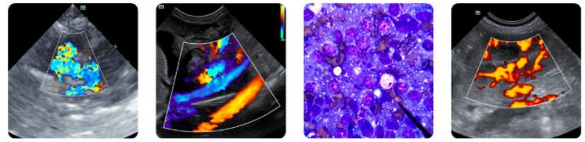
DATE

03/30/2026



The information and recommendations provided are based on the images presented by the referring veterinarian/sonographer. No evaluation can be communicated regarding pathology that was not visible in the image/video clips provided.

Thank you for this referral. If the clinical or image interpretation does not parallel your findings or if I can be of any further assistance, please contact me.



PATIENT

Queenie Teich

R. McKenzie Daniel, DVM, DABVP (Canine/Feline Practice)
info@sonopath.com

SPECIES

Canine

BREED

Chi Mix

SEX

FS

AGE

10yr

WEIGHT

4.37kg

INTERPRETED BY

R. McKenzie Daniel,
DVM, DABVP
(Canine and Feline)

**IMAGING
PERFORMED BY**

Kelly Reschny

HOSPITAL NAME

Beattie PH Stoney
Creek

REFERRING VET

Song

INVOICE

24352

DATE

03/30/2026