



PATIENT

Mick Ferris

PRESENTING CLINICAL SIGNS

- grade 3/6 murmur
- indoor/outdoor
- bravecto topical
- Abnormal PE/Chem/CBC/UA Results: Super chem, cbc, T4 no significant abnormalities

SPECIES

Feline

ULTRASONOGRAPHIC EXAMINATION OF THE HEART

BREED

DSH

SEX

MN

AGE

11yr

WEIGHT

10.6lb

FELINE CARDIAC PARAMETERS	BODY WEIGHT	HR (BPM)	IVSd (cm)	LVIDd (cm)	LVWd (cm)	FS (%)	EF (%)
NORMAL PARAMETER	-----	150-240	0.3-0.6	1.0-2.1	0.25-0.6	35-67	80-100
PATIENT	10.6lb	169	0.50	1.35	0.54	50	85
FELINE CARDIAC PARAMETERS	LA/AO M-Mode	LA/AO HEART BASE (Sisson)	LAD LA MAX 4 Chamber		LVOT VEL. (m/s)	RVOT VEL. (m/s)	IVRT (m/)
NORMAL PARAMETER	<1.5	1.6	0.7-1.7		<1.6	<1.3	40-60
PATIENT	--	1.0	1.5		--	1.0	NM

Sisson D et al. JVIM 1991; 5: 232, Jacobs et al. Am J Vet Res 1985; 46:1705

INTERPRETED BY

R. McKenzie Daniel, DVM, DABVP (Canine and Feline)

Cardiac Presentation

The echocardiogram in this patient demonstrated normal left atrial size based on 2 separate LA measurements. The cranial and caudal mitral valve leaflets presented normal linear structure and kinetics. No overt MR or SAM present on Doppler. The left ventricle presented normal thicknesses with linear contour and was not dilated nor restricted. The myocardium presented normal echogenicity without subjective evidence of significant fibrotic or ischemic disease. The contractility of the ventricular walls was adequate and in normal range for this patient evidenced by the fractional shortening measurement and subjective evaluation of the different regions and angles of the myocardium. The left ventricular outflow tract demonstrated normal laminar flow and subjective structural integrity. The right atrium and auricle revealed normal size, structure and content. No evidence of masses was noted or chamber overload. Tricuspid valvular assessment demonstrated adequate linear morphology and kinetics. No overt TR present on Doppler. The right ventricle was of normal size (1/3 diameter of LV), chordae structure, myocardial echogenicity and thickness. Pulmonic tract assessment revealed normal valve structure, laminar flow, and diameter (approx.1:1 pa/ao ratio). Normal measured RVOT velocity was present. No visible pericardial or free pleura fluid was noted or extra cardiac pathology in the visible planes. The cranial mediastinum and pericardial regions were free of masses in the visible window.

IMAGING PERFORMED BY

Chloe Lowe CVT

HOSPITAL NAME

American Animal Hospital Randolph

REFERRING VET

Dr Arculli

INVOICE
24355

DATE
03/30/2026



PATIENT ULTRASONOGRAPHIC FINDINGS

Mick Ferris **Primary**

- Normal cardiac structure/function

SPECIES

Feline

INTERPRETATION OF THE FINDINGS & FURTHER RECOMMENDATIONS

No evidence of clinical issues such as left or right heart chamber enlargement, LV systolic dysfunction, HCM criteria or other structural cardiomyopathy, arrhythmia or definitive significant valvular insufficiencies.

BREED

DSH

The definitive cause of the murmur was not identified. Assuming no volume changes such as dehydration or anemia, a benign flow murmur is probable. A small non-visualized flow abnormality is not excluded. Regardless of classification, the hemodynamic effects of the murmur are low. Monitoring of the heart murmur is recommended without indication for cardiac medications. Recheck echocardiogram is recommended in 6-12 months, sooner if murmur intensity increases or clinical signs arise.

SEX

MN

AGE

11yr

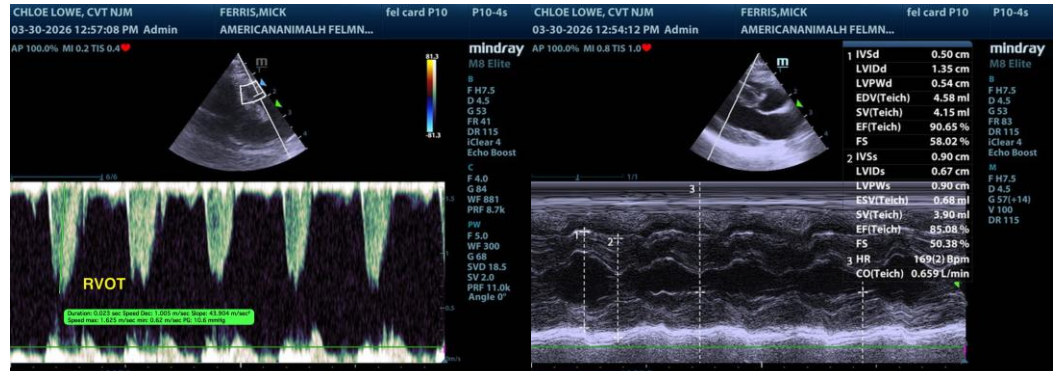
Anesthetic risk is considered low. Suggested anesthetic protocol may include opioid or Benzodiazepine pre-med, induction with Propofol or Alfaxalone, and appropriate gas anesthesia with avoidance of alpha 2 agonists.

WEIGHT

10.6lb

INTERPRETED BY

R. McKenzie Daniel,
 DVM, DABVP
 (Canine and Feline)

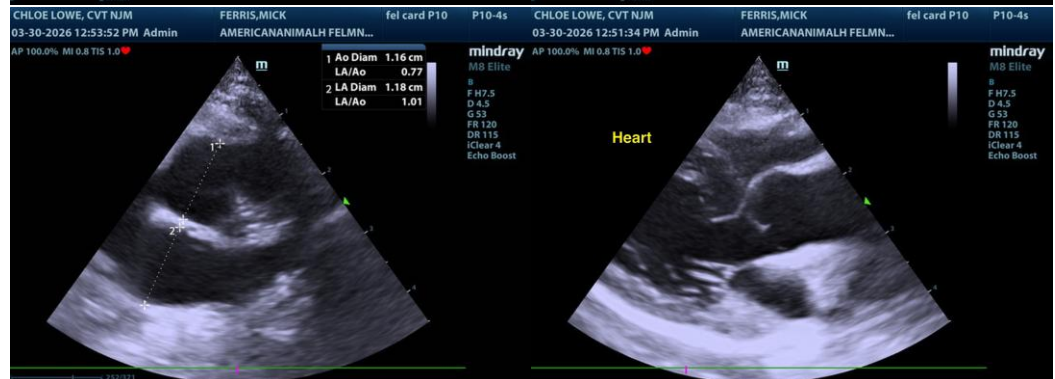


IMAGING PERFORMED BY

Chloe Lowe CVT

HOSPITAL NAME

American Animal
 Hospital Randolph



REFERRING VET

Dr Arculli

INVOICE
 24355

DATE
 03/30/2026



PATIENT

Mick Ferris

SPECIES

Feline

The information and recommendations provided are based on the images presented by the referring veterinarian/sonographer. No evaluation can be communicated regarding pathology that was not visible in the image/video clips provided.

BREED

DSH

Thank you for this referral. If the clinical or image interpretation does not parallel your findings or if I can be of any further assistance, please contact me.

SEX

MN

R. McKenzie Daniel, DVM, DABVP (Canine/Feline Practice)
info@sonopath.com

AGE

11yr

WEIGHT

10.6lb

INTERPRETED BY

R. McKenzie Daniel,
DVM, DABVP
(Canine and Feline)

**IMAGING
PERFORMED BY**

Chloe Lowe CVT

HOSPITAL NAME

American Animal
Hospital Randolph

REFERRING VET

Dr Arculli

**INVOICE
24355**

DATE
03/30/2026