



PATIENT

Marina Mahoney

SPECIES

Canine

BREED

GSD

SEX

SF

AGE

12

WEIGHT

56

INTERPRETED BY

R. McKenzie Daniel,
DVM, DABVP
(Canine and Feline)

IMAGING PERFORMED BY

Tasha

HOSPITAL NAME

Dillsburg VC

REFERRING VET

Dr. Crow

INVOICE

DATE

3/30/22

PRESENTING CLINICAL SIGNS

HX anal gland carcinoma-remove
Abnormal PE/Chem/CBC/UA Results: WNL

ULTRASONOGRAPHIC EXAMINATION OF THE HEART & ABDOMEN

CANINE CARDIAC PARAMETERS	MR VMAX (m/s)	TR VMAX (m/s)	LA/AO (Boon method)	LA/AO (Heart Base; Swe)	FS (%)	EF (%)	EPSS (cm)
NORMAL PARAMETER	4.5-5.5	<2.7	1.3	<1.6	28-40	40-100	<0.6
PATIENT				1.2	44.1	78.7	0.22
CANINE CARDIAC PARAMETERS	HR (BPM)	AV VMAX (m/s)	PV MAX (m/s)	BODY WEIGHT (kg)	LA 2D short axis Base view (cm)	LVIDd Avg; 2D and m-mode short axis (cm)	LVIDs Avg; 2D and m-mode short axis (cm)
NORMAL PARAMETER	50-100	0.7-1.7	0.7-1.6	BELOW	BELOW	BELOW	BELOW
PATIENT	NM	NM	NM		2.9	2.86	

Cardiac Presentation

The echocardiogram in this patient demonstrated normal **left atrial** size based on 3 separate methods of LA evaluation. The cranial and caudal **mitral** valve leaflets presented normal linear structure, extension in systole, and union in diastole with normal kinesis. The **left ventricle** presented thicknesses with linear contour and was not dilated nor restricted. The **myocardium** presented normal echogenicity without subjective evidence of significant fibrotic or ischemic disease. **Contractility** of the ventricular walls was adequate and in normal range for this patient evidenced by the fractional shortening measurement and subjective evaluation of the different regions of the myocardium. The **left ventricular outflow** tract demonstrated normal laminar flow and subjective structural integrity. The **right atrium** and auricle revealed normal size, structure and content. No evidence of masses was noted. **Tricuspid** valvular assessment demonstrated adequate linear morphology and kinesis. The **right ventricle** was of normal size (1/3 diameter of LV), chordae structure, myocardial echogenicity and thickness. **Pulmonary outflow** tract assessment revealed normal valve structure, laminar flow, and diameter (approx. 1:1 pa/ao ratio). No visible **pericardial** or free pleura fluid was noted. The cranial **mediastinum and pericardial and extra-cardiac regions** were free of masses in the visible window.

Urinary System

The urinary bladder, trigone, and cystourethral junction exhibited normal thickness and tone. Anechoic urine was present in the lumen with no uroliths or sediment. The ureteral papillae were normal. The ureters were not visible which is normal. No evidence of inflammatory or neoplastic changes was noted.



PATIENT	The area of the aortic trifurcation was free of pathology.
Marina Mahoney	
SPECIES	Normal size and margination were present in the kidneys. A normal 1:3 cortex / medulla ratio was maintained. The medulla and cortices were uniform in texture with some increased echogenicity and mild loss of corticomedullary symmetry and definition expected for the age of the patient. No evidence of pelvic dilation was present. The left kidney measured 6.4 cm in length. The right kidney measured 6.0 cm in length.
Canine	
BREED	
GSD	
SEX	
SF	
AGE	
12	
WEIGHT	
56	
INTERPRETED BY	
R. McKenzie Daniel, DVM, DABVP (Canine and Feline)	
IMAGING PERFORMED BY	
Tasha	
HOSPITAL NAME	
Dillsburg VC	
REFERRING VET	
Dr. Crow	
INVOICE	
DATE	
3/30/22	

Adrenal Glands

The left and right adrenal glands were not definitively visualized without evidence of pathology in the area of the left and right adrenal glands.

Spleen

The spleen exhibited a finely textured and homogenous parenchyma which was hyperechoic to the liver and renal cortical parenchyma. The capsule was smooth and regular without apparent expansion. The splenic vasculature at the hilus was normal in volume with no evidence of congestion or thrombosis. Acute to chronic inflammatory, neoplastic, or benign parenchyma changes were not noted.

Liver/ Gallbladder

The liver was subjectively normal in size, structure, and contour. The liver parenchyma was uniform and hypoechoic to the spleen with a mild coarse echotexture. The hepatic and portal vasculature were normal in appearance without signs of congestion. The gallbladder was non-distended in size with thin walls and primarily anechoic luminal content. The cystic and common bile ducts were normal.

Gastrointestinal

The stomach presented intact wall layering with a normal wall layer ratio. The lumen of the stomach was empty with no signs of ileus, obstruction, or foreign material.

The small intestine presented intact wall layering with 1:3 muscularis/mucosa ratio. The lumen of the small intestine was empty with no signs of ileus, obstruction, or foreign material.

Normal visible colon wall layers were present with apparent formed feces in lumen.

Pancreas

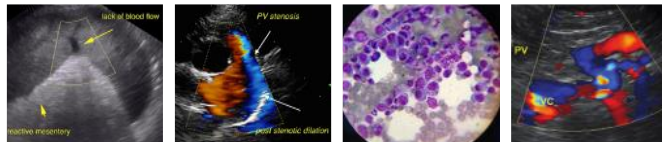
The parenchyma of the left limb, body, and right limb of the pancreas presented isoechoic to the adjacent omental fat. A normal curvilinear capsule contour of the pancreas was present. The visible pancreatic duct was normal. No signs of active inflammation or neoplastic disease were evident.

Free Abdomen

No overt lymphadenopathy or peritoneal effusion was present.

ULTRASONOGRAPHIC FINDINGS

- Sonographically unremarkable abdomen - no evidence of intra-abdominal or retroperitoneal metastasis
- Normal echocardiogram



PATIENT

Marina Mahoney

INTERPRETATION OF THE FINDINGS & FURTHER RECOMMENDATIONS

No evidence of cardiac or abdominal visceral pathology was present.

SPECIES

Canine

BREED

GSD

SEX

SF

AGE

12

WEIGHT

56

INTERPRETED BY

R. McKenzie Daniel,
DVM, DABVP
(Canine and Feline)

IMAGING PERFORMED BY

Tasha

HOSPITAL NAME

Dillsburg VC

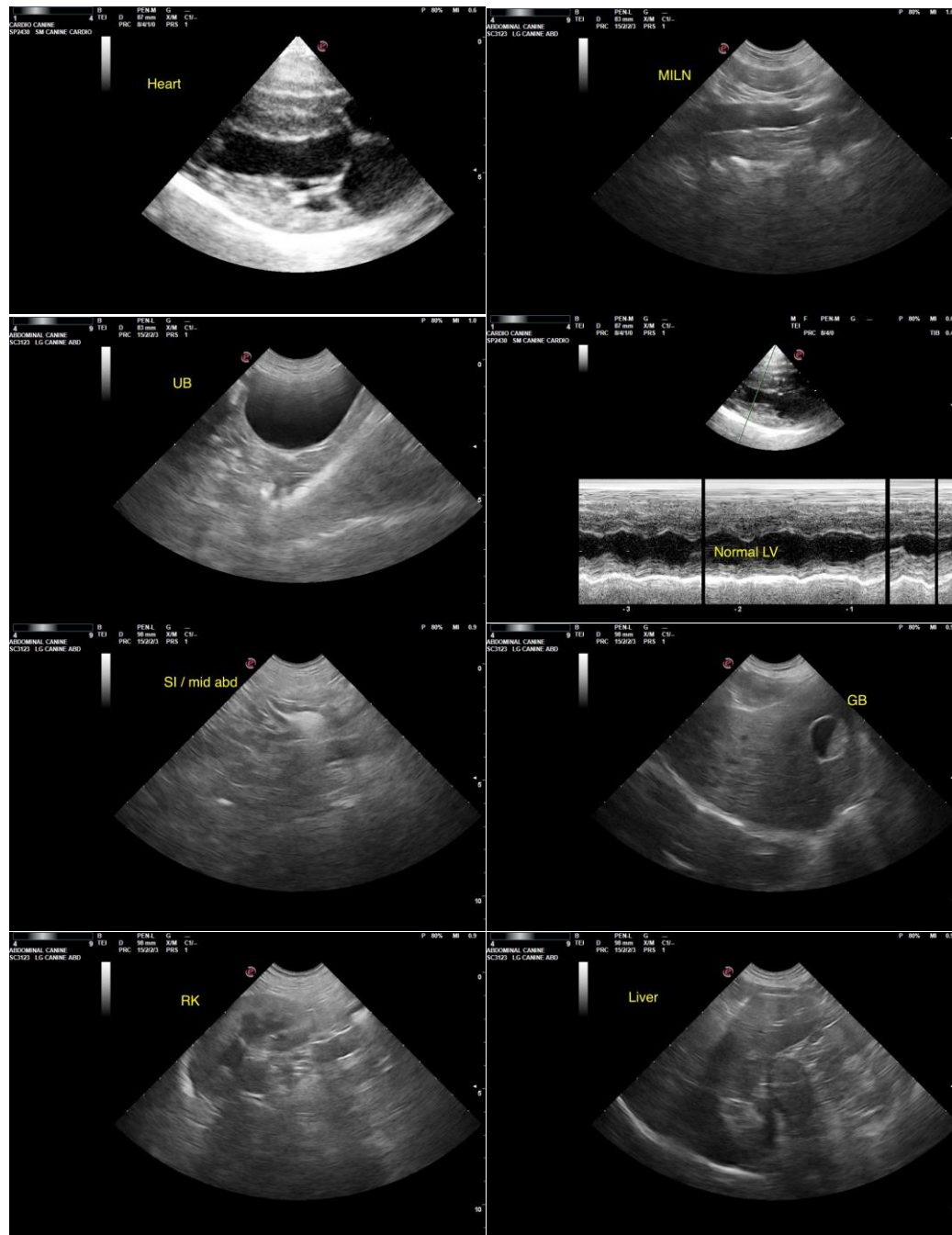
REFERRING VET

Dr. Crow

INVOICE

DATE

3/30/22





PATIENT

Marina Mahoney

SPECIES

Canine

BREED

GSD

SEX

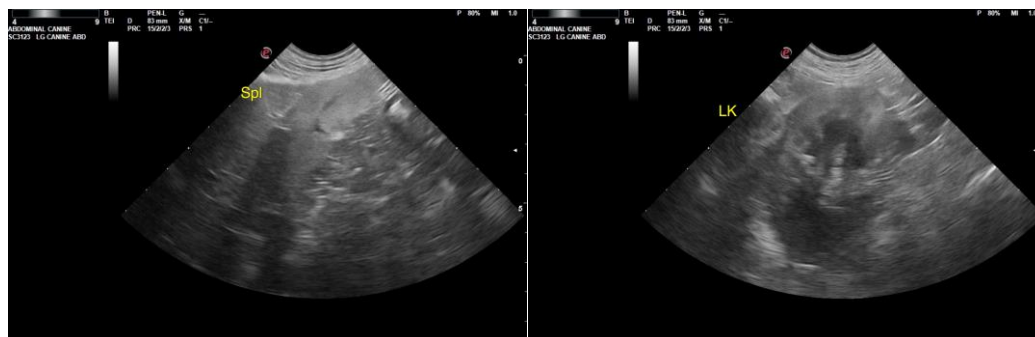SF

AGE

12

WEIGHT

56



The information and recommendations provided are based on the images presented by the referring veterinarian/sonographer. No evaluation can be communicated regarding pathology that was not visible in the image/video clips provided.

Thank you for this referral. If the clinical or image interpretation does not parallel your findings or if I can be of any further assistance please contact me.

INTERPRETED BY

R. McKenzie Daniel,
DVM, DABVP
(Canine and Feline)

R. McKenzie Daniel, DVM, DABVP (Canine / Feline Practice)
info@SonoPath.com

IMAGING PERFORMED BY

Tasha

HOSPITAL NAME

Dillsburg VC

REFERRING VET

Dr. Crow

INVOICE

DATE

3/30/22