



## PATIENT

Marzipan Gilman

## SPECIES

Feline

## BREED

DSH

## SEX

FS

## AGE

15yr

## WEIGHT

6.72lb

## PRESENTING CLINICAL SIGNS

Patient has a history of a persistent grade 2-3 parasternal heart murmur since 2023. No prior cardiac work up due to financial constraints. ProBNP WNL at 76 but has been trending upwards since 2023

Patient is here for a dental procedure with extractions

Abnormal PE/Chem/CBC/UA Results: CBC, Chem, T4, ProBNP WNL blood pressure 180 systolic

## PRE-ANESTHETIC ECHOCARDIOGRAM

Subjective non-thickened LV with myocardial remodeling. Adequate LV systolic function. Normal LA dimension. Overtly normal RA / RV. No evidence of overt cardiac tumors or visualized pericardial pathology / effusion.

## INTERPRETATION OF THE FINDINGS & FURTHER RECOMMENDATIONS

The hemodynamic effects of the non-specific reported heart murmur appear low, given lack of left or right heart chamber enlargement. Anesthetic risk is considered mild. However, judicious fluid administration is advised with careful RR/RE monitoring to screen for fluid overload given heart murmur. Monitoring of blood pressure, SpO2, CO2, and auscultation of heart and lungs during anesthesia should be done during every procedure. Suggested anesthetic protocol may include opioid or Benzodiazepine pre-med, induction with Propofol or Alfaxalone, and appropriate gas anesthesia with avoidance of alpha 2 agonists.

## INTERPRETED BY

R. McKenzie Daniel,  
DVM, DABVP  
(Canine and Feline)

## IMAGING PERFORMED BY

Dr. Andrea Nason

## HOSPITAL NAME

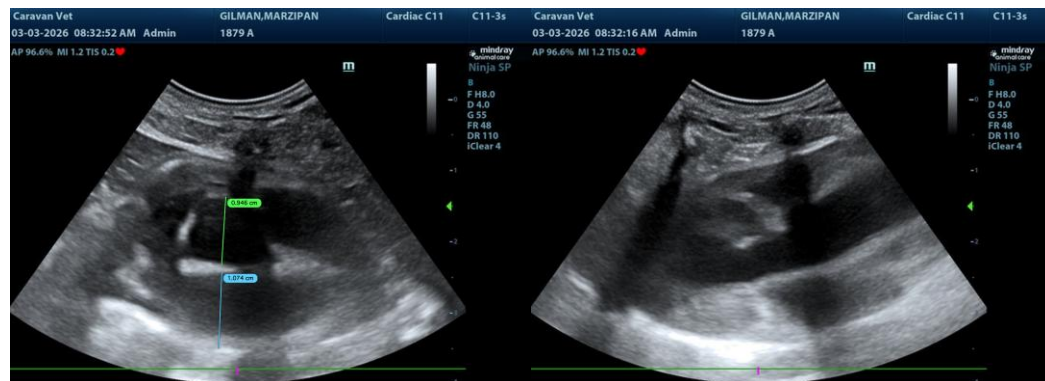
Caravan Vet

## REFERRING VET

Dr. Andrea Nason

INVOICE  
24088

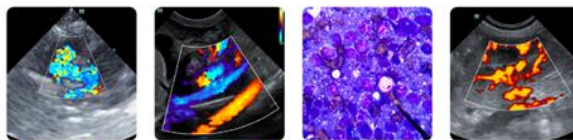
DATE  
03/03/2026



The information and recommendations provided are based on the images presented by the referring veterinarian/sonographer. No evaluation can be communicated regarding pathology that was not visible in the image/video clips provided.

Thank you for this referral. If the clinical or image interpretation does not parallel your findings or if I can be of any further assistance, please contact me.

R. McKenzie Daniel, DVM, DABVP (Canine/Feline Practice)  
[info@sonopath.com](mailto:info@sonopath.com)



## PATIENT

Marzipan Gilman

## SPECIES

Feline

## BREED

DSH

## SEX

FS

## AGE

15yr

## WEIGHT

6.72lb

## INTERPRETED BY

R. McKenzie Daniel,  
DVM, DABVP  
(Canine and Feline)

## IMAGING PERFORMED BY

Dr. Andrea Nason

## HOSPITAL NAME

Caravan Vet

## REFERRING VET

Dr. Andrea Nason

## INVOICE

24088

## DATE

03/03/2026