



**PATIENT**

Flower De Latorre

**SPECIES**

Canine

**BREED**

Chihuahua Mix

**SEX**

Spayed Female

**AGE**

9 Years

**WEIGHT**

Pending

**INTERPRETED BY**

R. McKenzie Daniel,  
DVM, DABVP (Canine /  
Feline Practice)

**IMAGING PERFORMED BY**

Shari Reffi, CVT

**HOSPITAL NAME**

Smithfield AH

**REFERRING VET**

Dr. Boe

**INVOICE**

36088

**DATE**

3/3/36

**PRESENTING CLINICAL SIGNS**

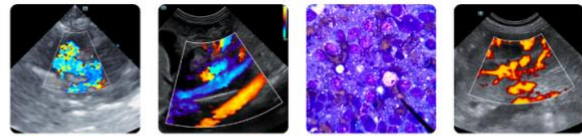
- Grade 3/6 heart murmur
- Wheezing
- Abnormal PE/Chem/CBC/UA Results: Mono-1.6; Plt-510; Pdw-6.9; K-3.4

• **ULTRASONOGRAPHIC EXAMINATION OF THE HEART**

<b>CANINE CARDIAC PARAMETERS</b>	<b>MR VMAX</b> (m/s)	<b>TR VMAX</b> (m/s)	<b>LA/AO</b> (M-Mode)	<b>LA/AO</b> (Heart Base; Swe)	<b>FS</b> (%)	<b>EF</b> (%)	<b>EPSS</b> (cm)
<b>NORMAL PARAMETER</b>	4.5-5.5	<2.7	1.3	Up to 1.6	28-40	40-100	<0.6
<b>PATIENT</b>	--	--	1.3	1.2	40	74	0.2
<b>CANINE CARDIAC PARAMETERS</b>	<b>HR</b> (BPM)	<b>AV VMAX</b> (m/s)	<b>PV MAX</b> (m/s)	<b>BODY WEIGHT</b> (kg)	<b>LAD</b> LA MAX 4 Chamber	<b>LVIDd</b> Avg; 2D and m-mode short axis (cm)	<b>LVIDs</b> Avg; 2D and m-mode short axis (cm)
<b>NORMAL PARAMETER</b>	50-100	0.7-1.7	0.7-1.6				
<b>PATIENT</b>	142	1.1	0.85	Pending	1.7	1.7	--

**Cardiac Presentation**

The echocardiogram in this patient demonstrated normal **left atrial** size based on 3 separate methods of LA evaluation. The cranial and caudal **mitral** valve leaflets presented normal linear structure, extension in systole, and union in diastole with normal kinesis. No overt significant MR on doppler. The **left ventricle** presented thicknesses with linear contour and was not dilated nor restricted. The **myocardium** presented normal echogenicity without subjective evidence of significant fibrotic or ischemic disease. **Contractility** of the ventricular walls was adequate and in normal range for this patient evidenced by the fractional shortening measurement and subjective evaluation of the different regions of the myocardium. The **left ventricular outflow** tract demonstrated normal laminar flow and subjective structural integrity. Normal measured LVOT velocity. The **right atrium** and auricle revealed normal size, structure and content. No evidence of masses was noted. **Tricuspid** valvular assessment demonstrated adequate linear morphology and kinesis. No evidence of TR. The **right ventricle** was of normal size (1/3 diameter of LV), chordae structure, myocardial echogenicity and thickness. **Pulmonary outflow** tract assessment revealed normal valve structure, laminar flow, and diameter (approx.1:1 pa/ao ratio). Normal measured RVOT velocity. No visible **pericardial** or free pleura fluid was noted. The cranial **mediastinum and pericardial and extra-cardiac regions** were free of masses in the visible window.



**PATIENT**

Flower De Latorre

**SPECIES**

Canine

**BREED**

Chihuahua Mix

**SEX**

Spayed Female

**AGE**

9 Years

**WEIGHT**

Pending

**INTERPRETED BY**

R. McKenzie Daniel,  
DVM, DABVP (Canine /  
Feline Practice)

**IMAGING  
PERFORMED BY**

Shari Reffi, CVT

**HOSPITAL NAME**

Smithfield AH

**REFERRING VET**

Dr. Boe

**INVOICE**

36088

**DATE**

3/3/36

**ULTRASONOGRAPHIC FINDINGS**

- Normal cardiac structure/function

**INTERPRETATION OF THE FINDINGS & FURTHER RECOMMENDATIONS**

No evidence of left or right heart chamber enlargement, LV systolic dysfunction, arrhythmia, clinical pulmonary hypertension, or definitive significant valvular insufficiencies. A non-obvious valvular insufficiency or flow murmur is possible. Regardless of classification, the hemodynamic effects of the murmur are low. Without evidence of left or right heart chamber enlargement, the respiratory signs in this patient are non-cardiogenic in origin. No indication for cardiac medication.

As needed respiratory support is recommended. Conservative monitoring of the reported murmur is indicated with recheck echo suggested in 6-12 months, sooner if increase in murmur intensity. No anesthetic contraindications.



**PATIENT**

Flower De Latorre

**SPECIES**

Canine

**BREED**

Chihuahua Mix

**SEX**

Spayed Female

**AGE**

9 Years

**WEIGHT**

Pending

**INTERPRETED BY**

R. McKenzie Daniel,  
 DVM, DABVP (Canine /  
 Feline Practice)

**IMAGING  
 PERFORMED BY**

Shari Reffi, CVT

**HOSPITAL NAME**

Smithfield AH

**REFERRING VET**

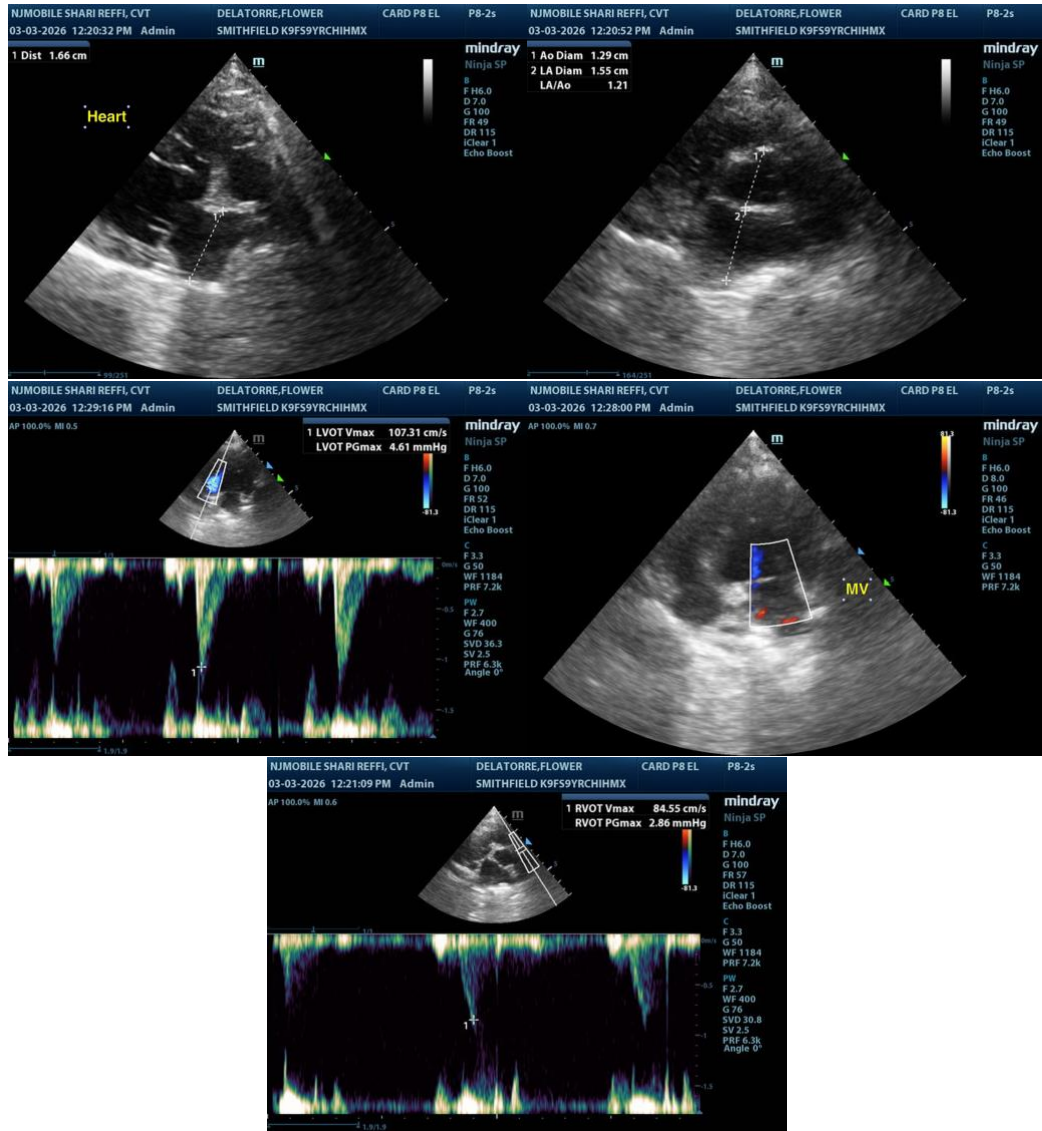
Dr. Boe

**INVOICE**

36088

**DATE**

3/3/36



The information and recommendations provided are based on the images presented by the referring veterinarian/sonographer. No evaluation can be communicated regarding pathology that was not visible in the image/video clips provided.

Thank you for this referral. If the clinical or image interpretation does not parallel your findings or if I can be of any further assistance please contact me.

**R. McKenzie Daniel, DVM, DABVP (Canine / Feline Practice)**

[info@SonoPath.com](mailto:info@SonoPath.com)