



**PATIENT**

Oliver Noonan

**PRESENTING CLINICAL SIGNS**

- 3 pound weight loss. ADR, hyporexia, vomiting. Did full bloodwork. ALB 2.1, SDMA 17.
- Sedated with butorphanol, alfaxalone

**SPECIES**

Feline

**ULTRASONOGRAPHIC EXAMINATION OF THE ABDOMEN**

**Urinary System**

The urinary bladder, trigone, cystourethral junction, and visible pelvic urethra exhibited normal thickness and tone. Anechoic urine was present in the lumen with no evidence of urine or lumen sediment, mineral, or calculi. The ureteral papillae were normal. The ureters were not visible which is normal. No evidence of inflammatory or neoplastic changes was noted.

**BREED**

DSH

Normal size and margination were present in the kidneys. A normal 1:3 cortex / medulla ratio was maintained. The medulla and cortices were uniform in texture with some increased echogenicity and mild loss of corticomedullary symmetry and definition expected for the age of the patient. No evidence of pelvic dilation was present. The left kidney measured 3.9 cm in length. The right kidney measured 4.2 cm in length.

**SEX**

MN

**AGE**

9yr

The area of the aortic trifurcation was free of pathology.

**Adrenal Glands**

The left adrenal gland was uniform in size and contour with a uniformly hypoechoic parenchyma. The left adrenal gland measured 0.46 cm width at the caudal pole. The right adrenal gland was uniform in size and contour with a uniformly hypoechoic parenchyma. The right adrenal gland measured 0.32 cm width at the caudal pole.

**WEIGHT**

10.2lb

**INTERPRETED BY**

R. McKenzie Daniel,  
DVM, DABVP  
(Canine and Feline)

**Spleen**

The spleen exhibited a finely textured and homogenous parenchyma which was hyperechoic to the liver and renal cortical parenchyma. The capsule was smooth and regular without apparent expansion. The splenic vasculature at the hilus was normal in volume with no evidence of congestion or thrombosis. Acute to chronic inflammatory, neoplastic, or benign parenchyma changes were not noted. The spleen measured 0.91 cm in width at the level of the mid spleen.

**IMAGING PERFORMED BY**

Pamela Harrigan,  
RDCS, Certified  
Veterinary  
Sonographer (IVUSS)

**Liver/Gallbladder**

The liver was subjectively normal in size, structure, and contour. The liver parenchyma was uniform and hypoechoic to the spleen with a mild coarse echotexture. Normal vascular volume. The hepatic and portal vasculature were normal in appearance without signs of congestion. The gallbladder was non-distended in size with thin walls and mild non-organized debris. The cystic and common bile ducts were normal.

**HOSPITAL NAME**

Norfolk County  
Veterinary Service

**Gastrointestinal**

The stomach presented intact wall layering with a normal wall layer ratio. The lumen of the stomach was empty with no signs of ileus, obstruction or foreign material.

**REFERRING VET**

Aurora Richards, DVM

Generalized thickened intestinal wall with altered to inverted wall layer ratio owing to generalized thickened muscularis layer. Segmental irregular jejunal mural mass exhibiting variable to significantly thickened wall, hypoechoic mural echogenicity, and loss of wall layering measuring ~ 6-7 cm length by

**INVOICE**  
24332

**DATE**

03/29/2026



**PATIENT**

Oliver Noonan

~ 3 cm diameter. Mild retained focally shadowing ingesta in the likely proximal jejunum without overt diffused obstructive pattern.

Normal visible colon wall layers were present with apparent formed feces in lumen.

**SPECIES**

Feline

**Pancreas**

The parenchyma of the left limb, body and right limb of the pancreas presented isoechoic to the adjacent omental fat. A normal curvilinear capsule contour of the pancreas was present. The visible pancreatic duct was normal. No signs of active inflammation or neoplastic disease was evident.

**BREED**

DSH

**Free Abdomen**

Regional non-homogenous hyperechoic peri intestinal omentum.

**SEX**

MN

Mild hypoechoic to swollen non-homogenous peri intestinal mesenteric lymph nodes and scant peri intestinal effusion.

**AGE**

9yr

**Primary**

- Diffuse infiltrative enteropathy with segmental jejunal mural mass
- Peri intestinal non-homogenous omentum and mild non-homogenous to swollen mesenteric lymphadenopathy
- Mild age-related renal changes
- Mild gallbladder debris

**WEIGHT**

10.2lb

**ULTRASONOGRAPHIC FINDINGS**

**INTERPRETATION OF THE FINDINGS & FURTHER RECOMMENDATIONS**

The jejunal mass and overall infiltrative enteropathy pattern is consistent with neoplastic criteria with suspect high grade intestinal round cell neoplasia such as lymphoma. Assuming normal clotting status, FNA cytology of the jejunal mass is warranted for further assessment with oncology or surgical consultation. Three view chest radiographs are recommended if not done to assess for occult thoracic pathology.

Potential for focal shadowing intestinal content or foreign material proximal to the jejunal mural mass not definitively excluded.

Gastrointestinal support and monitoring of intestinal content pending additional diagnostics is recommended.

**INTERPRETED BY**

R. McKenzie Daniel,  
DVM, DABVP  
(Canine and Feline)

**IMAGING PERFORMED BY**

Pamela Harrigan,  
RDCS, Certified  
Veterinary  
Sonographer (IVUSS)

**HOSPITAL NAME**

Norfolk County  
Veterinary Service

**REFERRING VET**

Aurora Richards, DVM

**INVOICE**

24332

**DATE**

03/29/2026



**PATIENT**

Oliver Noonan

**SPECIES**

Feline

**BREED**

DSH

**SEX**

MN

**AGE**

9yr

**WEIGHT**

10.2lb

**INTERPRETED BY**

R. McKenzie Daniel,  
DVM, DABVP  
(Canine and Feline)

**IMAGING PERFORMED BY**

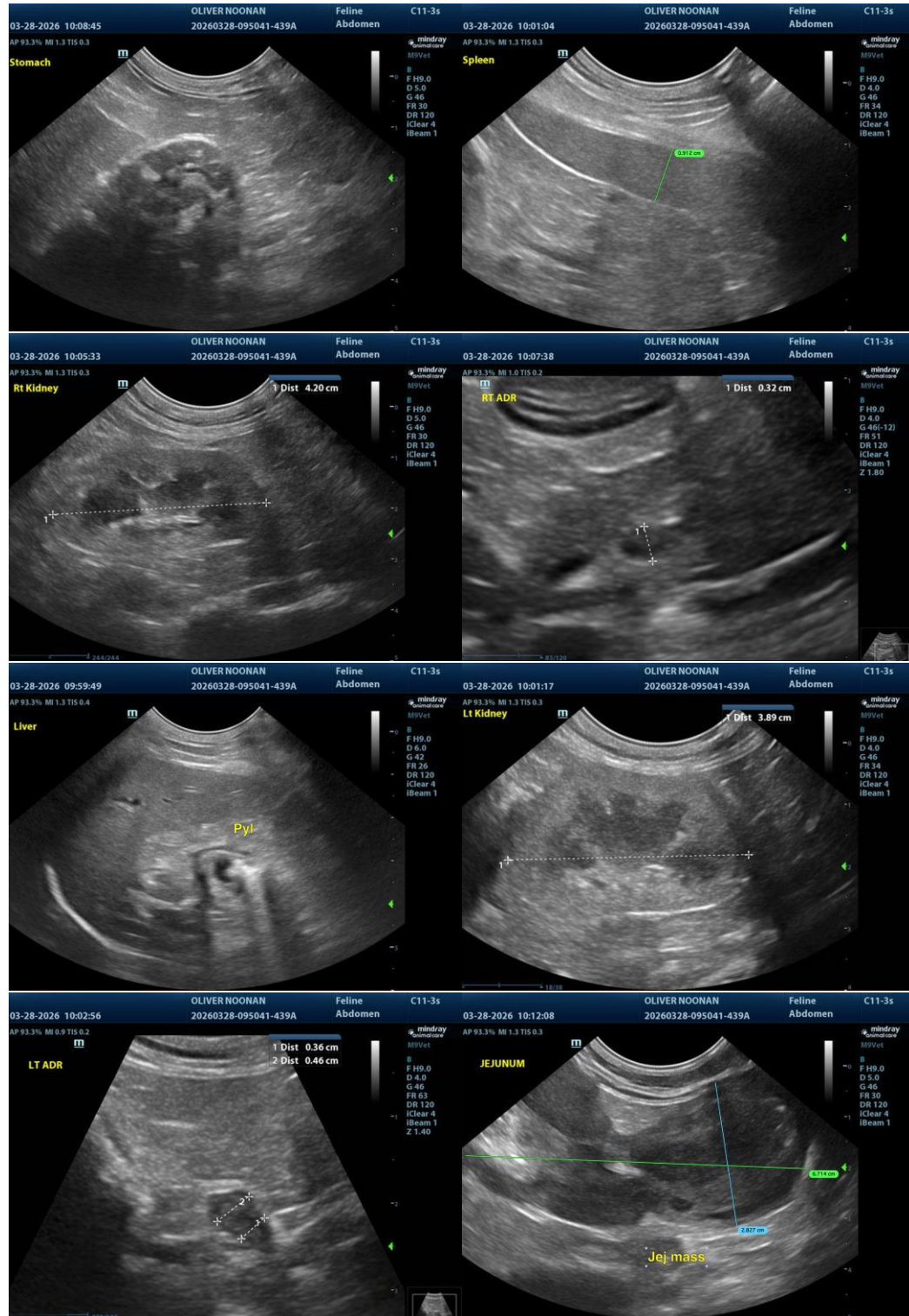
Pamela Harrigan,  
RDCS, Certified  
Veterinary  
Sonographer (IVUSS)

**HOSPITAL NAME**

Norfolk County  
Veterinary Service

**REFERRING VET**

Aurora Richards, DVM

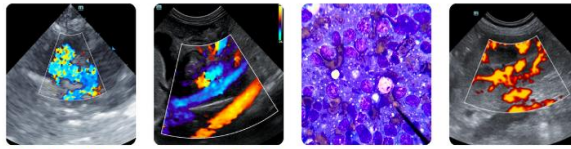


**INVOICE**

24332

**DATE**

03/29/2026



**PATIENT**

Oliver Noonan

**SPECIES**

Feline

**BREED**

DSH

**SEX**

MN

**AGE**

9yr

**WEIGHT**

10.2lb

**INTERPRETED BY**

R. McKenzie Daniel,  
DVM, DABVP  
(Canine and Feline)

**IMAGING PERFORMED BY**

Pamela Harrigan,  
RDCS, Certified  
Veterinary  
Sonographer (IVUSS)

**HOSPITAL NAME**

Norfolk County  
Veterinary Service

**REFERRING VET**

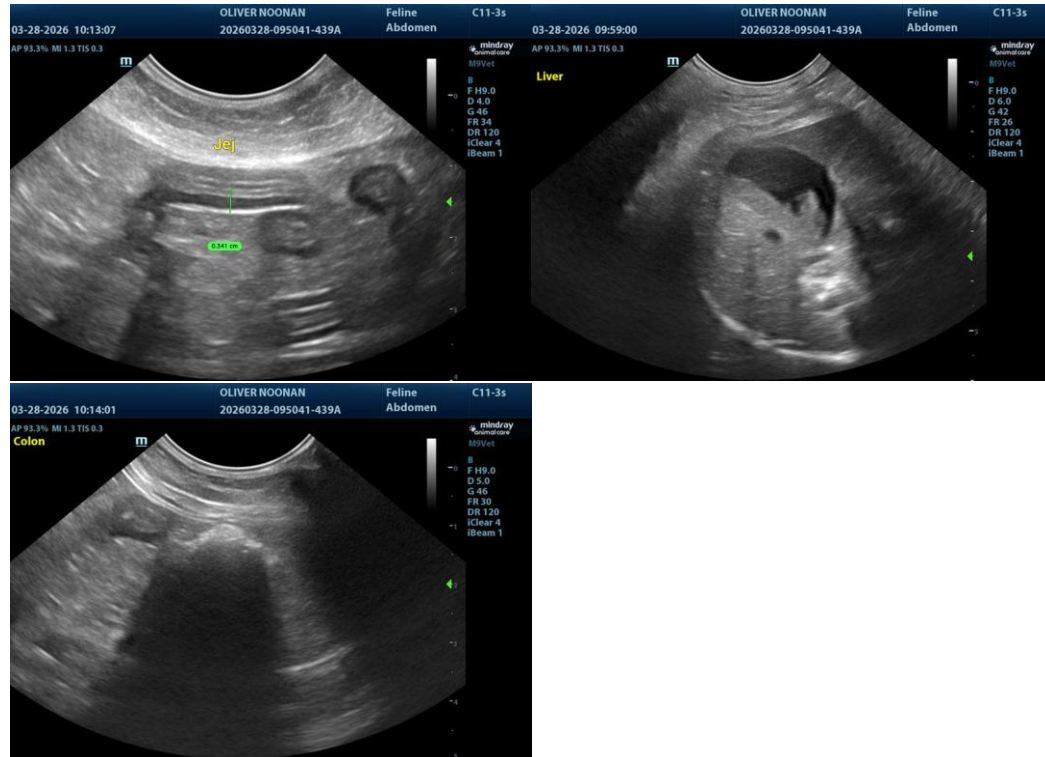
Aurora Richards, DVM

**INVOICE**

24332

**DATE**

03/29/2026



The information and recommendations provided are based on the images presented by the referring veterinarian/sonographer. No evaluation can be communicated regarding pathology that was not visible in the image/video clips provided.

Thank you for this referral. If the clinical or image interpretation does not parallel your findings or if I can be of any further assistance, please contact me.

R. McKenzie Daniel, DVM, DABVP (Canine/Feline Practice)  
[info@sonopath.com](mailto:info@sonopath.com)