

PATIENT PRESENTING CLINICAL SIGNS

Cece Kametz Increased vomiting

SPECIES ULTRASONOGRAPHIC EXAMINATION OF THE ABDOMEN

Feline **Urinary System**

The urinary bladder, trigone, cystourethral junction, and visible pelvic urethra to a depth of 2.0 cm exhibited normal thickness and tone. Anechoic urine was present in the lumen with no uroliths or sediment. The ureteral papillae were normal. The ureters were not visible which is normal. No evidence of inflammatory or neoplastic changes were noted.

BREED

DSH

SEX

Spayed Female

Normal size and margination were present in the kidneys. A normal 1:3 cortex / medulla ratio and normal corticomedullary definition were maintained. The echogenicity of the cortex was similar to or slightly less than normal liver parenchyma while the medulla echogenicity was hypoechoic to the cortex with no evidence of pelvic dilation. The left kidney measured 3.7 cm. The right kidney measured 4.2 cm.

AGE

2014

Adrenal Glands

The adrenal glands were uniform in size and contour with a uniformly hypoechoic parenchyma. The left adrenal gland measured 0.46 cm. The right adrenal gland measured 0.50 cm.

WEIGHT

18.2 Pounds

Spleen

The spleen exhibited a finely textured and homogenous parenchyma which was hyperechoic to the liver and renal cortical parenchyma. The spleen measured 0.9 cm in width at the level of the hilus. The capsule was smooth and regular without apparent expansion. The splenic vasculature at the hilus was normal in volume with no evidence of congestion or thrombosis. Acute to chronic inflammatory, neoplastic, or benign parenchyma changes were not noted.

INTERPRETED BY

R. McKenzie
 Daniel, DVM,
 DABVP

Liver

The liver was subjectively normal in size, structure, and contour. The liver parenchyma was uniform and hypoechoic to the spleen with a mild coarse echotexture. The hepatic and portal vasculature were normal in appearance without signs of congestion. The gallbladder was non-distended in size with thin walls and primarily anechoic luminal content. The cystic and common bile ducts were normal.

IMAGING PERFORMED BY

abekah Jakum, CVT
 ARDMS/RVT

Gastrointestinal

The stomach presented intact to potentially mild prominent wall layering. Subtle increased gastric mural echogenicity present in the ventral gastric body wall. No evidence of loss of gastric wall layering, as well as no evidence of retained ingesta, fluid or foreign material. Gastric body wall subjectively measured 0.35 cm in wall width. Very minor retained anechoic pyloric fluid.

HOSPITAL NAME

Alburtis AH

REFERRING VET

Dr. Smith

The small intestine presented intact wall layering with 1:3 muscularis/mucosa ratio. The lumen of the small intestine was empty with no signs of ileus, obstruction or foreign material. Duodenum wall measured 0.22 cm. Jejunum wall measured 0.20 cm.

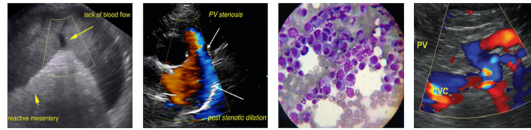
INVOICE

36531

No overt pathology in the area of the ileocolic junction. Normal visible colon wall layers were present with apparent formed feces in lumen.

DATE

3/29/22



PATIENT

Pancreas

Cece Kametz

The pancreas was normal in size and contour with heterogeneous to mildly echogenic parenchyma compared to adjacent omentum. Subjective mild pancreatic capsule asymmetry. No signs of active inflammation or neoplasia.

SPECIES

Feline

Free Abdomen

Subtle evidence of peripancreatic to perigastric reactive mesentery, primarily around the pancreas base and pylorus.

BREED

DSH

ULTRASONOGRAPHIC FINDINGS

SEX

Spayed Female

- Possible mild gastritis
- Sonographically unremarkable small bowel
- Mildly echogenic to heterogeneous pancreas – potential low-grade/chronic pancreatitis

INTERPRETATION OF THE FINDINGS & FURTHER RECOMMENDATIONS

AGE

2014

Overall, no overt evidence of significant visceral (specifically gastrointestinal or pancreatic) pathology. Potential for mild gastritis with secondary mild increased mural echogenicity versus gastric fat deposition sometimes seen in cats. Potential for low-grade to chronic pancreatitis would be suspected if evidence of cranial abdominal or subxiphoid discomfort on palpation.

WEIGHT

18.2 Pounds

Potential for low-grade inflammatory enteropathy, which may present sonographically normal, or possible masking of intestinal mural changes secondary to current Prednisolone, cannot be excluded. Dietary indiscretion/food intolerance, or occult parasitism (even with negative fecal testing) could be playing a role in this patient's vomiting.

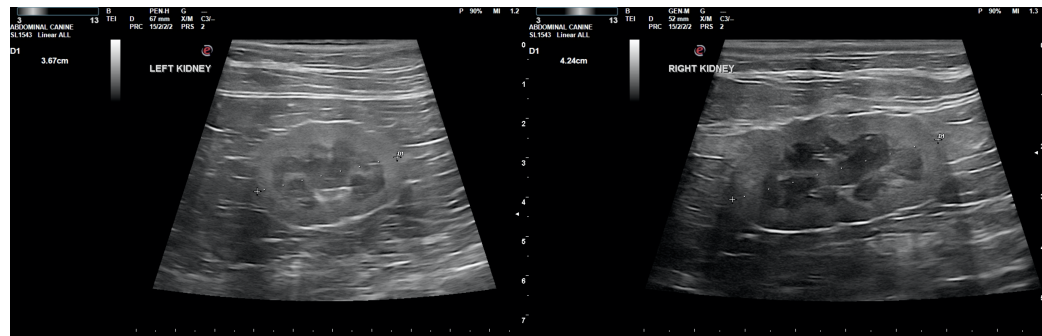
INTERPRETED BY

R. McKenzie
Daniel, DVM,
DABVP

Further assessment may include GI panel to include PLI, TLI, cobalamin and folate. Empirically, hydrolyzed diet trial, as needed gastrointestinal support +/- conservative therapy for low-grade to chronic pancreatitis may prove beneficial.

IMAGING PERFORMED BY

abekah Jakum, CVT
ARDMS/RVT



HOSPITAL NAME

Alburtis AH

REFERRING VET

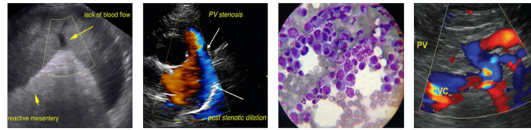
Dr. Smith

INVOICE

36531

DATE

3/29/22



PATIENT

Cece Kametz

SPECIES

Feline

BREED

DSH

SEX

Spayed Female

AGE

2014

WEIGHT

18.2 Pounds

INTERPRETED BY

R. McKenzie
Daniel, DVM,
DABVP

IMAGING PERFORMED BY

abekah Jakum, CVT
ARDMS/RVT

HOSPITAL NAME

Alburtis AH

REFERRING VET

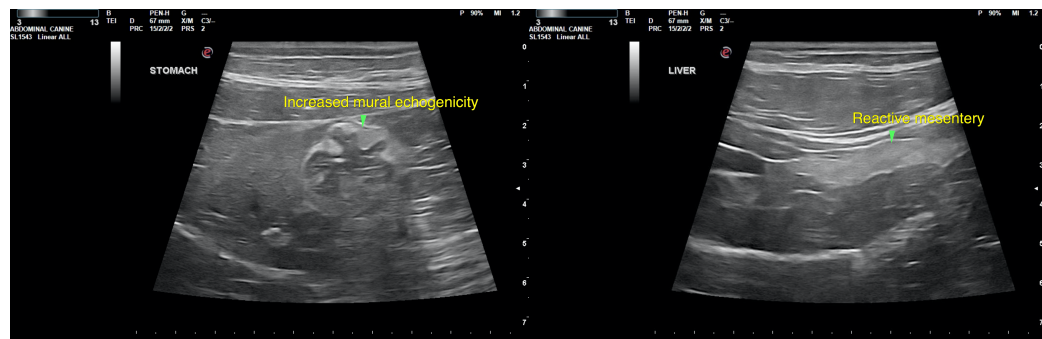
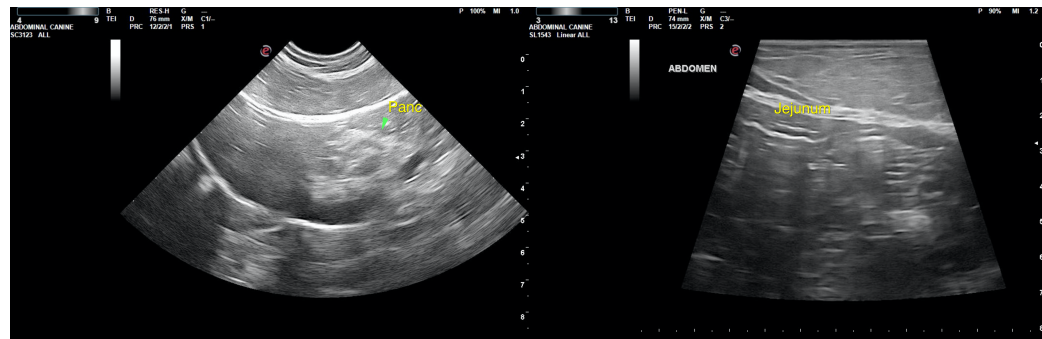
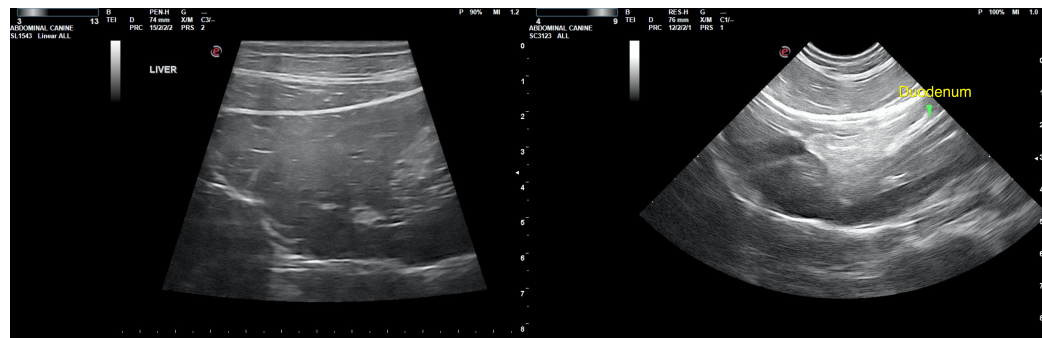
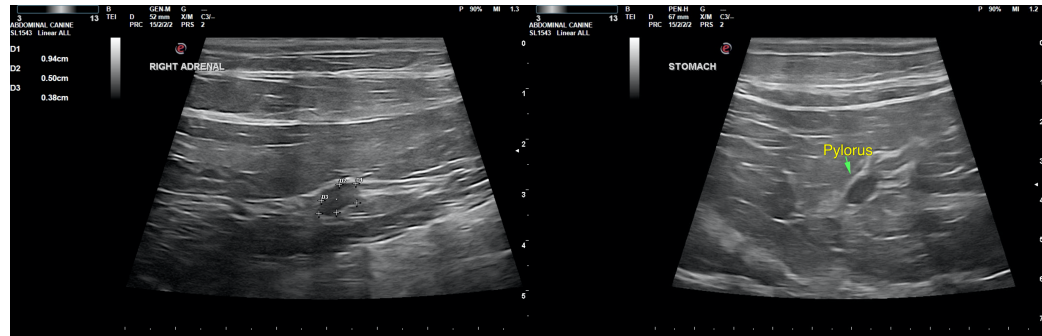
Dr. Smith

INVOICE

36531

DATE

3/29/22



The information and recommendations provided are based on the images presented by the referring veterinarian/sonographer. No evaluation can be communicated regarding pathology that was not visible in the image/video clips provided.

Thank you for this referral. If the clinical or image interpretation does not parallel your findings or if I can be of any further assistance please contact me.

R. McKenzie Daniel, DVM, DABVP (Canine / Feline Practice) info@SonoPath.com