



PATIENT

Jolene Oliver

SPECIES

Canine

BREED

Mixed

SEX

FS

AGE

8yr

WEIGHT

60.00

INTERPRETED BY

R. McKenzie Daniel,
DVM, DABVP
(Canine and Feline)

IMAGING PERFORMED BY

Marco Litchfield

HOSPITAL NAME

Sova Animal Hospital

REFERRING VET

Dr Dodson

INVOICE 24312

DATE
03/27/2026

PRESENTING CLINICAL SIGNS

Owner wants to screen before dental procedure

Abnormal PE/Chem/CBC/UA Results: No issues or concerns per owner just wants pet screened before procedure

ULTRASONOGRAPHIC EXAMINATION OF THE ABDOMEN

Urinary System

The urinary bladder, trigone, cystourethral junction, and visible pelvic urethra to a depth of 3 cm exhibited normal thickness and tone. Anechoic urine was present in the lumen with no evidence of urine/lumen sediment, mineral, or calculi. The ureteral papillae were normal. The ureters were not visible which is normal. No evidence of inflammatory or neoplastic changes was noted.

Normal size and margination were present in the kidneys. A normal 1:3 cortex / medulla ratio and normal corticomedullary definition were maintained. The echogenicity of the cortex was similar to or slightly less than normal liver parenchyma while the medulla echogenicity was hypoechoic to the cortex with no evidence of pelvic dilation. The left kidney measured 6.2 cm in length. The right kidney measured 7.1 cm in length.

The area of the aortic trifurcation was free of pathology.

Adrenal Glands

The left adrenal gland was uniform in size and contour with a uniformly hypoechoic parenchyma. The left adrenal gland measured 0.60 cm width at the caudal pole. The right adrenal gland was uniform in size and contour with a uniformly hypoechoic parenchyma. The right adrenal gland measured 0.60 cm width at the caudal pole.

Spleen

The spleen exhibited a finely textured and homogenous parenchyma which was hyperechoic to the liver and renal cortical parenchyma. The capsule was smooth and regular without apparent expansion. The splenic vasculature at the hilus was normal in volume with no evidence of congestion or thrombosis. Acute to chronic inflammatory, neoplastic, or benign parenchyma changes were not noted.

Liver/Gallbladder

The liver was subjectively normal in size, structure, and contour. The liver parenchyma was uniform and hypoechoic to the spleen with a mild coarse echotexture. Normal vascular volume. The hepatic and portal vasculature were normal in appearance without signs of congestion. The gallbladder was non-distended in size with thin walls and mild gravity dependent non-organized debris. The cystic and common bile ducts were normal.

Gastrointestinal

The stomach presented intact wall layering with a normal wall layer ratio. The lumen of the stomach was empty with no signs of ileus, obstruction or foreign material.

The small intestine presented intact wall layering with 1:3 muscularis/mucosa ratio. The lumen of the small intestine was empty with no signs of mechanical/metabolic ileus, obstruction or foreign material.



PATIENT

Normal visible colon wall layers were present with apparent formed feces in lumen.

Jolene Oliver

Pancreas

The parenchyma of the left limb, body and right limb of the pancreas presented isoechoic to the adjacent omental fat. A normal curvilinear capsule contour of the pancreas was present. The visible pancreatic duct was normal. No signs of active inflammation or neoplastic disease was evident.

SPECIES

Canine

Free Abdomen

BREED

No omental masses, overt lymphadenopathy or peritoneal effusion was present.

Mixed

ULTRASONOGRAPHIC FINDINGS

Primary

SEX

- Sonographically unremarkable abdomen
- Mild non-organized gallbladder debris

FS

AGE

INTERPRETATION OF THE FINDINGS & FURTHER RECOMMENDATIONS

8yr

No evidence of visceral pathology. Ursodiol trial could be considered if evidence of cholestasis.

WEIGHT

60.00

INTERPRETED BY

R. McKenzie Daniel,
DVM, DABVP
(Canine and Feline)

IMAGING PERFORMED BY

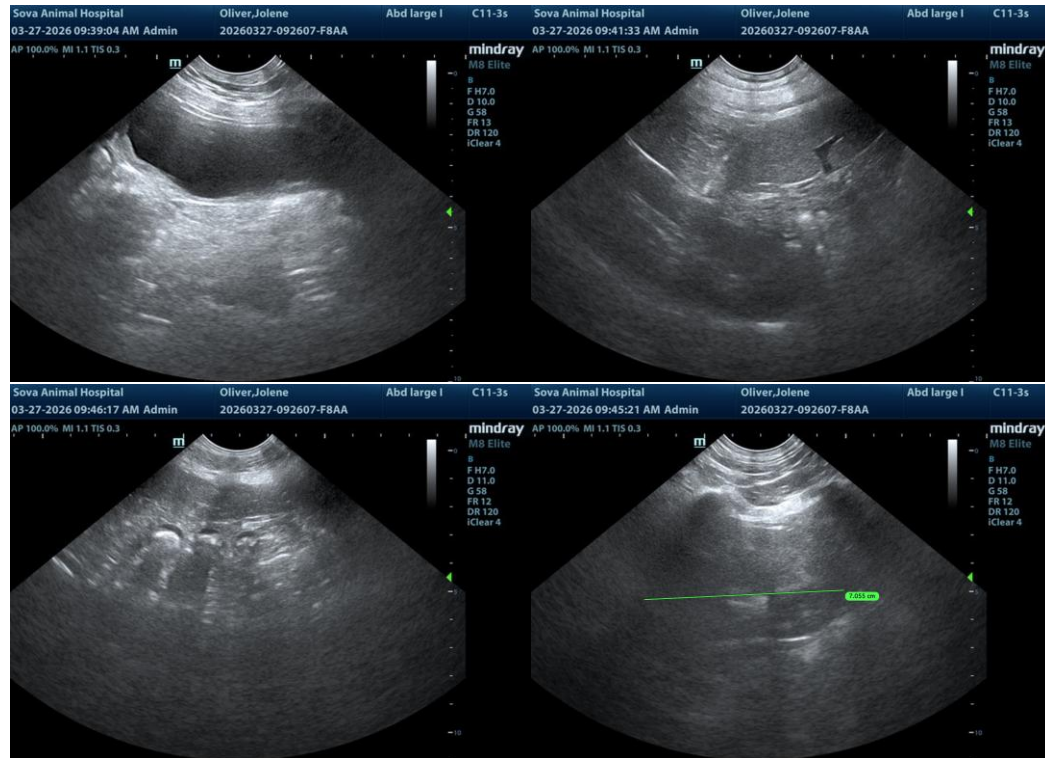
Marco Litchfield

HOSPITAL NAME

Sova Animal Hospital

REFERRING VET

Dr Dodson



INVOICE
24312

DATE
03/27/2026



PATIENT

Jolene Oliver

SPECIES

Canine

BREED

Mixed

SEX

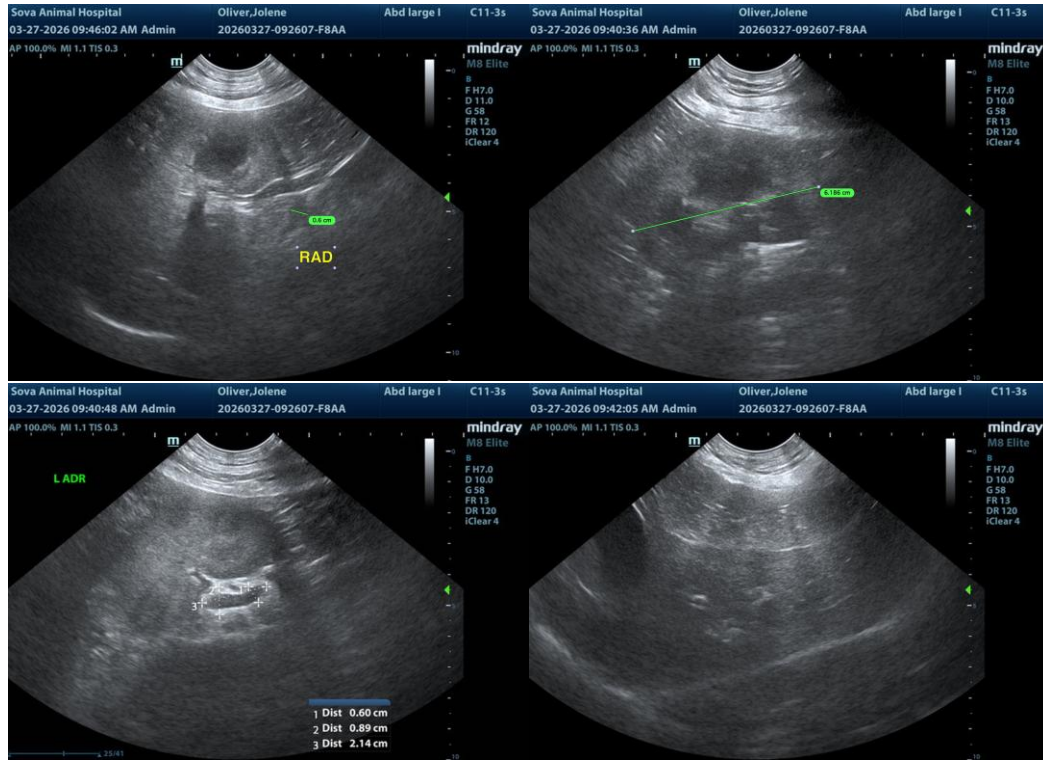
FS

AGE

8yr

WEIGHT

60.00



INTERPRETED BY

R. McKenzie Daniel,
DVM, DABVP
(Canine and Feline)

IMAGING PERFORMED BY

Marco Litchfield

HOSPITAL NAME

Sova Animal Hospital

REFERRING VET

Dr Dodson

INVOICE
24312

DATE
03/27/2026

The information and recommendations provided are based on the images presented by the referring veterinarian/sonographer. No evaluation can be communicated regarding pathology that was not visible in the image/video clips provided.

Thank you for this referral. If the clinical or image interpretation does not parallel your findings or if I can be of any further assistance, please contact me.

R. McKenzie Daniel, DVM, DABVP (Canine/Feline Practice)
info@sonopath.com