



PATIENT

JR Melchione

SPECIES

Feline

BREED

Maine Coon

SEX

MN

AGE

7yr

WEIGHT

13.2lb

INTERPRETED BY

R. McKenzie Daniel,
DVM, DABVP
(Canine and Feline)

IMAGING PERFORMED BY

Shari Reffi CVT

HOSPITAL NAME

Animal Hospital of
Sussex County

REFERRING VET

Dr. Catania

INVOICE

13283ag

DATE

03/27/2023

PRESENTING CLINICAL SIGNS

General malaise, hx of prev. dx HCM. TFAST revealed pericardial effusion. Current meds: Pimobendan 1.25mg sid; Benazepril 5mg sid, just started Furosemide 12.5mg q12h.

Abnormal PE/Chem/CBC/UA Results: cbc-nsf, Ca 14 -hypercalcemia of malignancy panel.

ULTRASONOGRAPHIC EXAMINATION OF THE HEART

Cardiac Presentation

The left ventricular wall exhibited increased septal and free wall thickness with alinear myocardial contour and regions of asymmetry. Subjective subtle diffuse hyperechoic endocardium which may suggest myocardial fibrosis and mildly prominent papillary muscles were present. LV systolic function appears to be adequate. Normal LV volume was present. The left atrium was mildly dilated and bulbous in appearance. No overt evidence of LA spontaneous contrast, smoke or formed thrombus. LA/AO heart base measured 2.6. LA diameter measured 2.6. Subjective normal RA/RV. Blood flow through the RVOT appeared to be normal to mildly subnormal in measured velocity. RVOT velocity measured 0.70 m/s. Scant to minor pericardial effusion was present. No obvious cardiac tumors.

ULTRASONOGRAPHIC FINDINGS

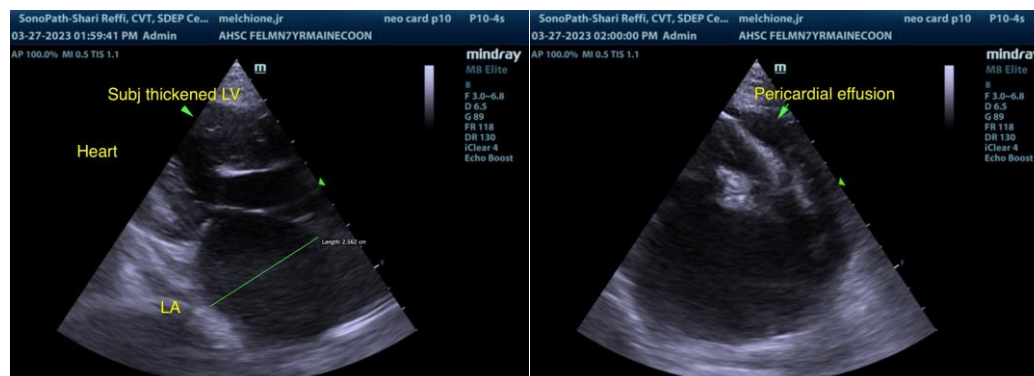
- Thickened to remodeled LV with possible mild LV fibrosis.
- Moderate LA enlargement.
- Scant to mild volume pericardial effusion.

INTERPRETATION OF THE FINDINGS & FURTHER RECOMMENDATIONS

The thickened remodeled LV may be consistent with the previous diagnosis of HCM which would be a rule out diagnosis assuming the patient is euthyroid and normotensive. The degree of left atrial dilation and scant pericardial effusion is consistent with CHF.

Hospitalization with stabilization including injectable diuretic therapy and O2 therapy is recommended. Once patient is stable, Lasix 1-2 mg/kg PO BID, clopidogrel 75 mg tab ¼ tab PO SID and current off label Pimobendan at current dose would be reasonable. Monitoring of renal parameters, systemic BP +/- ECG if evidence of arrhythmia is recommended.

This patient is at significantly increased risk for continued episodes of CHF, malignant arrhythmia and/or thrombus formation. An extremely guarded prognosis is indicated although assessment of clinical response to initiation of diuretic therapy is recommended. Recheck echocardiogram is suggested in 3-4 months, sooner if clinically indicated.





PATIENT

JR Melchione

SPECIES

Feline

BREED

Maine Coon

SEX

MN

AGE

7yr

WEIGHT

13.2lb

INTERPRETED BY

R. McKenzie Daniel,
DVM, DABVP
(Canine and Feline)

IMAGING PERFORMED BY

Shari Reffi CVT

HOSPITAL NAME

Animal Hospital of
Sussex County

REFERRING VET

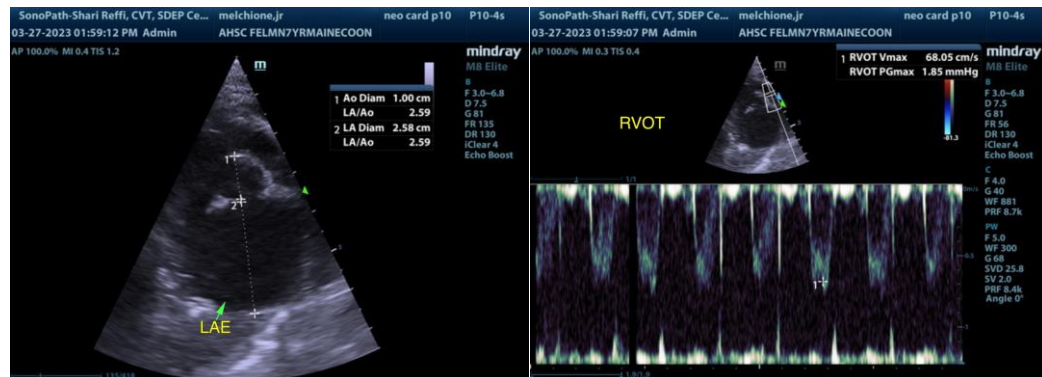
Dr. Catania

INVOICE

13283ag

DATE

03/27/2023



The information and recommendations provided are based on the images presented by the referring veterinarian/sonographer. No evaluation can be communicated regarding pathology that was not visible in the image/video clips provided.

Thank you for this referral. If the clinical or image interpretation does not parallel your findings or if I can be of any further assistance, please contact me.

R. McKenzie Daniel, DVM, DABVP (Canine/Feline Practice)
mac.daniel@sonopath.com