

PATIENT

Titus Roth

SPECIES

Canine

BREED

Pitbull

SEX

Neutered Male

AGE

2017

WEIGHT

64.1

INTERPRETED BY

R. McKenzie Daniel,
DVM, DABVP (Canine
/ Feline Practice)

**IMAGING
PERFORMED BY**

Rebekah Jakum, CVT,
ARDMS/RVT

HOSPITAL NAME

Lehigh Valley Animal
Hospital

REFERRING VET

Dr. Hersh

INVOICE

14660

DATE

03/26/26

PRESENTING CLINICAL SIGNS

- Seizures
- Elevated liver values
- PU/PD ~2 months
- Medication: hepatosupport, Keppra

ULTRASONOGRAPHIC EXAMINATION OF THE ABDOMEN

Urinary System

The urinary bladder was normal in size and tone. Mild generalized thickened urinary bladder wall exhibiting symmetrical luminal surface and homogenous mural echogenicity. No masses were evident. No evidence of mineral or calculi.

The area of the residual prostate appeared normal and free of pathology.

The area of the aortic trifurcation was free of pathology.

Normal size and margination was present in the kidneys. A normal 1:3 cortex / medulla ratio was maintained. The medulla and cortices were uniform in texture with some increased echogenicity and mild loss of corticomedullary symmetry and definition expected for the age of the patient. No evidence of pelvic dilation was present. The left kidney measured 6.8 cm in length. The right kidney measured 6.9 cm in length.

Adrenal Glands

The left adrenal gland was uniform in size and contour with a uniformly hypoechoic parenchyma. The left adrenal gland measured 0.56 cm width at the caudal pole.

The right adrenal gland was uniform in size and contour with a uniformly hypoechoic parenchyma. The right adrenal gland measured 0.59 cm width at the caudal pole.

Spleen

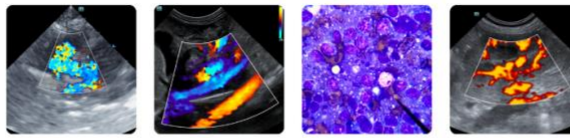
The spleen exhibited a finely textured and homogenous parenchyma which was hyperechoic to the liver and renal cortical parenchyma. The capsule was smooth and regular without apparent expansion. The splenic vasculature at the hilus was normal in volume with no evidence of congestion or thrombosis. Acute to chronic inflammatory, neoplastic, or benign parenchyma changes were not noted.

Liver & Gallbladder

The liver presented mildly enlarged in size. The parenchyma of the liver was subjectively normal in echogenicity compared to the spleen and renal cortices. The liver parenchyma was uniform with a mildly coarse echotexture. The capsule of the liver was symmetrically rounded to mildly swollen in margination. The hepatic and portal vasculature were normal in appearance without signs of congestion.

The gallbladder was non-distended in size with thin walls and primarily anechoic luminal content. The cystic and common bile ducts were normal.

Gastrointestinal



PATIENT

Titus Roth

The stomach presented intact wall layering with a normal wall layer ratio. The lumen of the stomach was empty with no signs of ileus, obstruction or foreign material.

SPECIES

Canine

The small intestine presented intact wall layering with 1:3 muscularis/mucosa ratio. The lumen of the small intestine was empty with no signs of ileus, obstruction or foreign material.

Normal visible colon wall layers were present with apparent formed feces in lumen.

BREED

Pitbull

Pancreas

The parenchyma of the left limb, body and right limb of the pancreas presented isoechoic to the adjacent omental fat. A normal curvilinear capsule contour of the pancreas was present. The visible pancreatic duct was normal. No signs of active inflammation or neoplastic disease was evident.

SEX

Neutered Male

Free Abdomen

No overt lymphadenopathy or peritoneal effusion was present.

AGE

2017

ULTRASONOGRAPHIC FINDINGS

- Hepatopathy exhibiting normal vascular volume.
- Normal gallbladder.
- Mild age-related kidneys.
- Normal adrenal glands.

WEIGHT

64.1

INTERPRETATION OF THE FINDINGS & FURTHER RECOMMENDATIONS

INTERPRETED BY

R. McKenzie Daniel,
DVM, DABVP (Canine
/ Feline Practice)

The appearance of the liver was nonspecific but most consistent with benign hepatopathy. Considerations for the liver may include benign vacuolar / cholestatic hepatopathy, inflammatory/infectious/immune mediated disease, hyperplasia, hematopoiesis, toxic hepatopathy (i.e. copper), other with neoplasia thought less likely. No overt evidence of intrahepatic or extrahepatic macroscopic shunt. Ultrasound guided FNA of the liver using a 25-gauge needle and assuming normal coagulation parameters would be warranted for screening cytology. Hepatosupportive medications such as Denamarin or Vitamin E as well as Ursodiol due to its antioxidant and immunomodulatory effects within the liver would be warranted, although these medications may not result in decreased hepatic enzyme levels. Leptospirosis titers / PCR may be considered if clinically indicated. Core or surgical biopsy likely required for definitive diagnosis.

IMAGING PERFORMED BY

Rebekah Jakum, CVT,
ARDMS/RVT

HOSPITAL NAME

Lehigh Valley Animal
Hospital

No evidence of adrenal pathology as an obvious contributing factor. If clinical suspicion for Cushing's syndrome despite lack of adrenal pathology, adrenal screening could be considered.

REFERRING VET

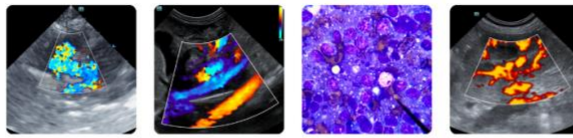
Dr. Hersh

INVOICE

14660

DATE

03/26/26



PATIENT

Titus Roth

SPECIES

Canine

BREED

Pitbull

SEX

Neutered Male

AGE

2017

WEIGHT

64.1

INTERPRETED BY

R. McKenzie Daniel,
 DVM, DABVP (Canine
 / Feline Practice)

IMAGING PERFORMED BY

Rebekah Jakum, CVT,
 ARDMS/RVT

HOSPITAL NAME

Lehigh Valley Animal
 Hospital

REFERRING VET

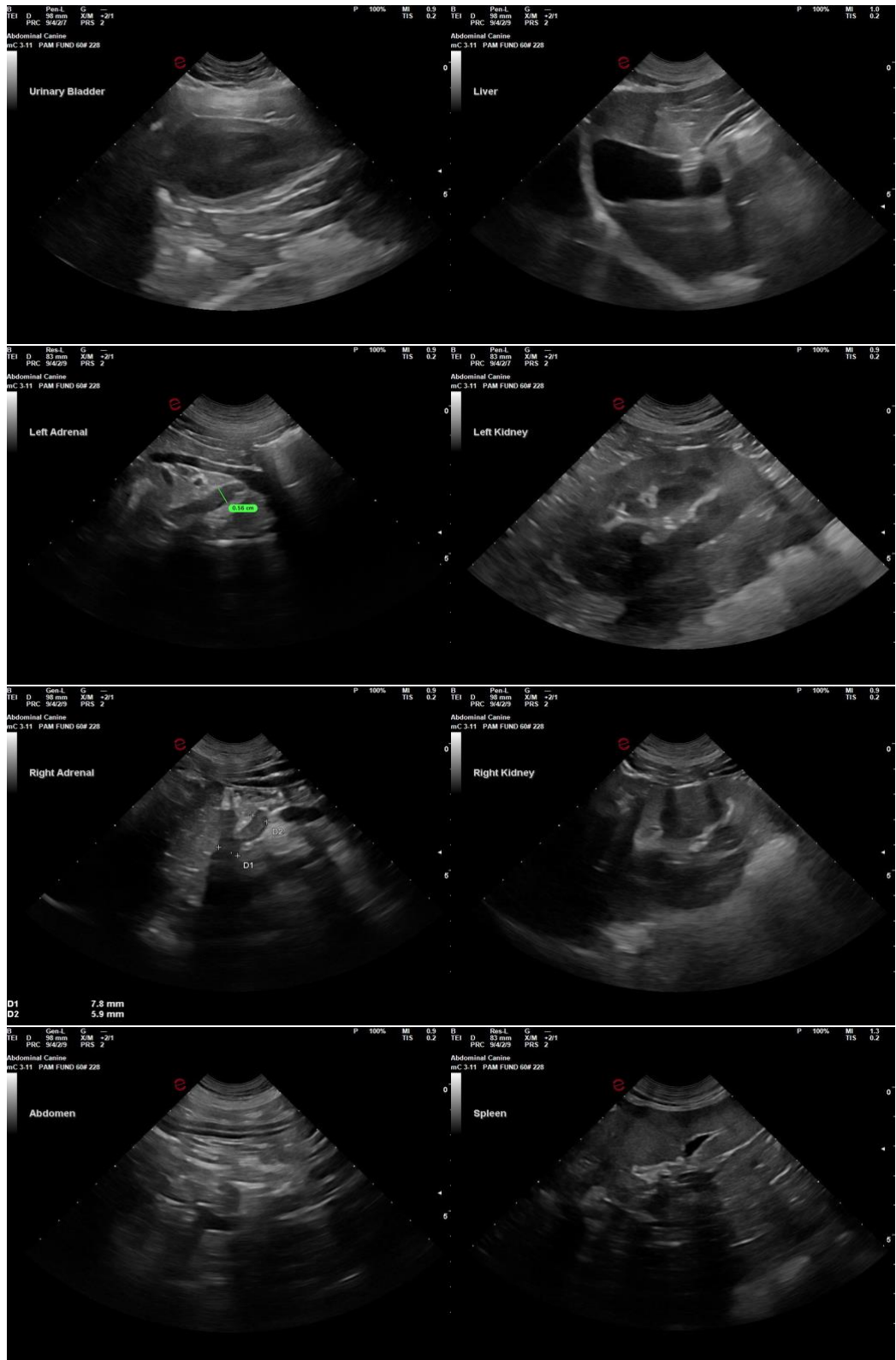
Dr. Hersh

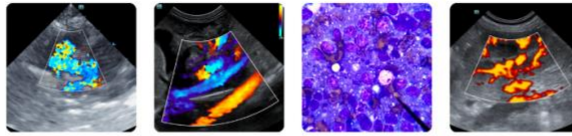
INVOICE

14660

DATE

03/26/26





PATIENT

Titus Roth

SPECIES

Canine

BREED

Pitbull

SEX

Neutered Male

AGE

2017

WEIGHT

64.1

INTERPRETED BY

R. McKenzie Daniel,
DVM, DABVP (Canine
/ Feline Practice)

**IMAGING
PERFORMED BY**

Rebekah Jakum, CVT,
ARDMS/RVT

HOSPITAL NAME

Lehigh Valley Animal
Hospital

REFERRING VET

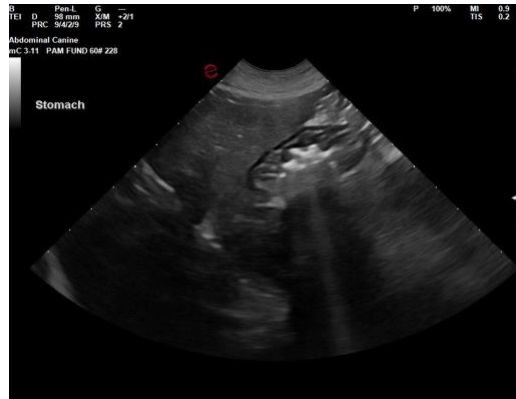Dr. Hersh

INVOICE

14660

DATE

03/26/26



The information and recommendations provided are based on the images presented by the referring veterinarian/sonographer. No evaluation can be communicated regarding pathology that was not visible in the image/video clips provided.

Thank you for this referral. If the clinical or image interpretation does not parallel your findings or if I can be of any further assistance, please contact me.

R. McKenzie Daniel, DVM, DABVP (Canine / Feline Practice)

info@SonoPath.com