

## PATIENT

Rylee Gillingham

## SPECIES

Canine

## BREED

Chihuahua

## SEX

Spayed Female

## AGE

12 yrs

## WEIGHT

10.6 lbs.

## INTERPRETED BY

R. McKenzie Daniel,  
DVM, DABVP  
(Canine and Feline)

## IMAGING PERFORMED BY

Trish Turner CVT

## HOSPITAL NAME

Straley Veterinary  
Associates

## REFERRING VET

Robert Mason DVM

## INVOICE

10734

## DATE

3/26/26

## PRESENTING CLINICAL SIGNS

History:

- new client
- history of heart murmur, not given past vet records
- bleeding from mouth, oral nasal fistulas, needs oral treatment
- no medications

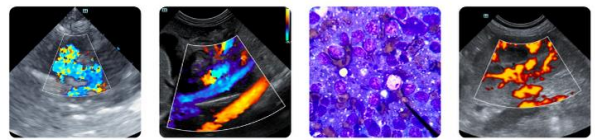
Abnormal PE/Chem/CBC/UA Results: doppler blood pressure in clinic 180-190 chest rads done but not assessed yet

## ULTRASONOGRAPHIC EXAMINATION OF THE HEART

CANINE CARDIAC PARAMETERS	MR VMAX (m/s)	TR VMAX (m/s)	LA/AO (M-Mode)	LA/AO (Heart Base; Swe)	FS (%)	EF (%)	EPSS (cm)
NORMAL PARAMETER	4.5-5.5	<2.7	1.3	Up to 1.6	28-40	40-100	<0.6
PATIENT	-	-	-	-	48	81	0.2
CANINE CARDIAC PARAMETERS	HR (BPM)	AV VMAX (m/s)	PV MAX (m/s)	BODY WEIGHT	LAD LA MAX 4 Chamber	LVIDd Avg; 2D and m-mode short axis (cm)	LVIDs Avg; 2D and m-mode short axis (cm)
NORMAL PARAMETER	50-100	0.7-1.7	0.7-1.6				
PATIENT	NM	NM	NM	10.6 lbs	2.9	2.7	-

## Cardiac Presentation

The echocardiogram in this patient demonstrated normal **left atrial** size based on 2 different LA measurement methods. The cranial and caudal **mitral** valve leaflets presented thickening consistent with endocardiosis. Doppler revealed moderate eccentric MR. The **left ventricle** presented thicknesses with linear contour and was not dilated nor restricted. The **myocardium** presented normal echogenicity without subjective evidence of significant fibrotic or ischemic disease. **Contractility** of the ventricular walls was adequate and in normal range for this patient evidenced by the fractional shortening measurement and subjective evaluation of the different regions of the myocardium. The **left ventricular outflow** tract demonstrated normal laminar flow and subjective structural integrity. Minor aortic valve insufficiency was noted on Doppler. The **right atrium** and auricle revealed normal size, structure and content. No evidence of masses was noted or chamber overload. **Tricuspid** valvular assessment demonstrated adequate linear morphology. The **right ventricle** was of normal size (1/3 diameter of LV), chordae structure, myocardial echogenicity and



## PATIENT

Rylee Gillingham

## SPECIES

Canine

## BREED

Chihuahua

## SEX

Spayed Female

## AGE

12 yrs

## WEIGHT

10.6 lbs.

## INTERPRETED BY

R. McKenzie Daniel,  
DVM, DABVP  
(Canine and Feline)

## IMAGING PERFORMED BY

Trish Turner CVT

## HOSPITAL NAME

Straley Veterinary  
Associates

## REFERRING VET

Robert Mason DVM

## INVOICE

10734

## DATE

3/26/26

thickness. **Pulmonic** tract assessment revealed normal valve structure, laminar flow, and diameter (approx. 1:1 pa/ao ratio). No visible **pericardial** or free pleura fluid was noted. No echographically detectable evidence of cardiac / pericardial tumors was visible.

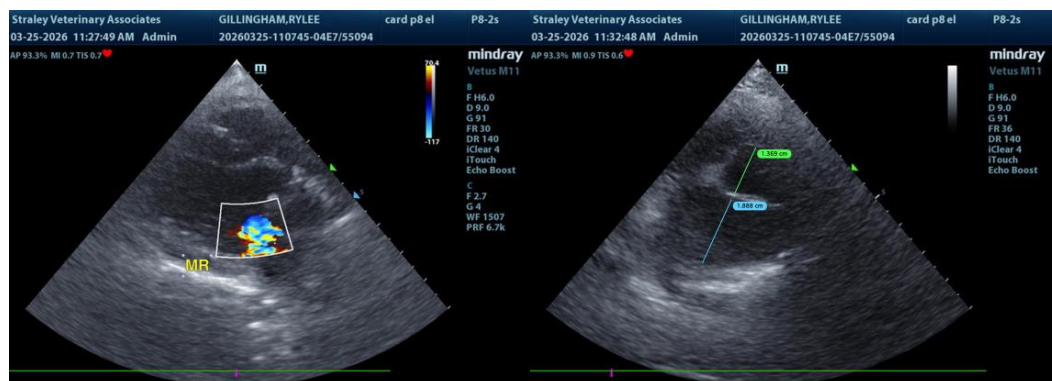
## ULTRASONOGRAPHIC FINDINGS

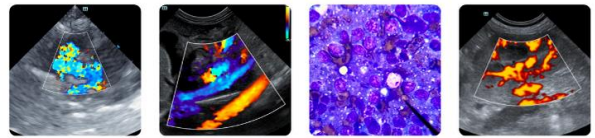
- Chronic mitral valve disease (B1)
- Minor aortic valve insufficiency

## INTERPRETATION OF THE FINDINGS & FURTHER RECOMMENDATIONS

The cause of the murmur is chronic degenerative valvular changes with secondary eccentric mitral valve insufficiency. The lack of left atrial enlargement implies that the risk of complication secondary to mitral valve insufficiency is low at this time and, without current clinical signs, indicates that medical therapy is not required. Prognosis is considered variable and sonographic monitoring is recommended. Recheck echocardiogram is suggested in 6-12 months, sooner if clinical signs arise. Monitoring of systemic BP for evidence of hypertension, given minor aortic valve insufficiency, is recommended. Anesthetic risk is considered mild.

Suggested anesthetic protocol may include opioid or Benzodiazepine pre-med, induction with Propofol or Alfaxalone, and appropriate gas anesthesia with avoidance of alpha 2 agonists.





## PATIENT

Rylee Gillingham

## SPECIES

Canine

## BREED

Chihuahua

## SEX

Spayed Female

## AGE

12 yrs

## WEIGHT

10.6 lbs.

## INTERPRETED BY

R. McKenzie Daniel,  
DVM, DABVP  
(Canine and Feline)

## IMAGING PERFORMED BY

Trish Turner CVT

## HOSPITAL NAME

Straley Veterinary  
Associates

## REFERRING VET

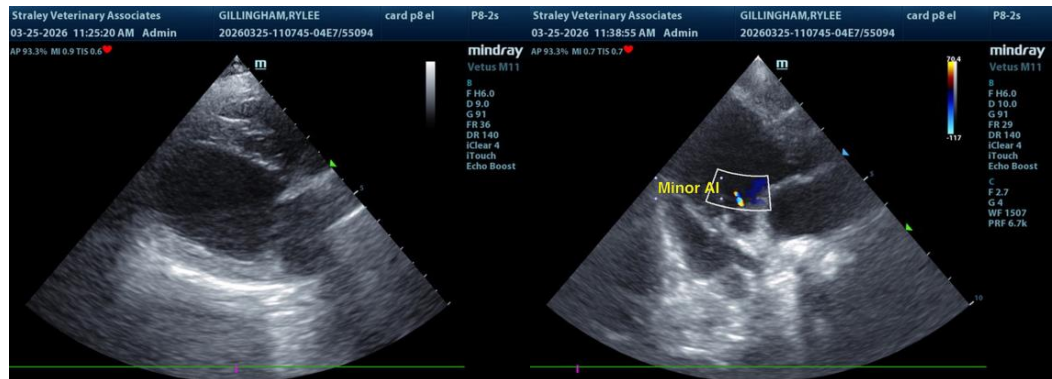
Robert Mason DVM

## INVOICE

10734

## DATE

3/26/26



The information and recommendations provided are based on the images presented by the referring veterinarian/sonographer. No evaluation can be communicated regarding pathology that was not visible in the image/video clips provided.

Thank you for this referral. If the clinical or image interpretation does not parallel your findings or if I can be of any further assistance please contact me.

R. McKenzie Daniel, DVM, DABVP (Canine/Feline Practice)  
[info@sonopath.com](mailto:info@sonopath.com)