



PATIENT

Lola Ballester

SPECIES

Canine

BREED

Pomeranian

SEX

FS

AGE

6 years, 10 months

WEIGHT

13.6 lbs.

INTERPRETED BY

R. McKenzie Daniel,
 DVM, DABVP
 (Canine and Feline)

IMAGING PERFORMED BY

Kerri Becker

HOSPITAL NAME

Ramapo Valley AH

REFERRING VET

Dr. Katara

INVOICE

10732

DATE

3/26/26

PRESENTING CLINICAL SIGNS

History:

- New murmur wants COHAT grade 4-5/6 systolic

Abnormal PE/Chem/CBC/UA Results: ca-11.5

ULTRASONOGRAPHIC EXAMINATION OF THE HEART

CANINE CARDIAC PARAMETERS	MR VMAX (m/s)	TR VMAX (m/s)	LA/AO (M-Mode)	LA/AO (Heart Base; Swe)	FS (%)	EF (%)	EPSS (cm)
NORMAL PARAMETER	4.5-5.5	<2.7	1.3	Up to 1.6	28-40	40-100	<0.6
PATIENT	-	-	-	-	43	76	0.1
CANINE CARDIAC PARAMETERS	HR (BPM)	AV VMAX (m/s)	PV MAX (m/s)	BODY WEIGHT	LAD LA MAX4 Chamber	LVIDd Avg; 2D and m-mode short axis (cm)	LVIDs Avg; 2D and m-mode short axis (cm)
NORMAL PARAMETER	50-100	0.7-1.7	0.7-1.6				
PATIENT	244	1.6	1.0	13.6 lbs.	3.0	2.6	-

Cardiac Presentation

The echocardiogram in this patient demonstrated mild increased **left atrial** size based on 2 different LA measurement methods. Minor interatrial septal deviation was noted. The cranial and caudal **mitral** valve leaflets presented thickening consistent with endocardiosis. Doppler indicated Moderate eccentric MR. Borderline increased LV dimension was present. The **myocardium** presented normal echogenicity without subjective evidence of significant fibrotic or ischemic disease. **Contractility** of the ventricular walls was adequate and in normal range for this patient evidenced by the fractional shortening measurement and subjective evaluation of the different regions of the myocardium. The **left ventricular outflow** tract demonstrated normal laminar flow and subjective structural integrity. The **right atrium** and auricle revealed normal size, structure and content. No evidence of masses was noted or chamber overload. **Tricuspid** valvular assessment demonstrated adequate linear morphology. Mild TR was noted on Doppler. The **right ventricle** was of normal size (1/3 diameter of LV), chordae structure, myocardial echogenicity and thickness. **Pulmonic** tract assessment revealed normal valve structure, laminar flow, and diameter (approx.1:1 pa/ao ratio). No visible **pericardial** or free pleura fluid was noted. No echographically detectable evidence of cardiac / pericardial tumors was visible.



PATIENT

Lola Ballester

SPECIES

Canine

BREED

Pomeranian

SEX

FS

AGE

6 years, 10 months

WEIGHT

13.6 lbs.

INTERPRETED BY

R. McKenzie Daniel,
 DVM, DABVP
 (Canine and Feline)

IMAGING PERFORMED BY

Kerri Becker

HOSPITAL NAME

Ramapo Valley AH

REFERRING VET

Dr. Katara

INVOICE

10732

DATE

3/26/26

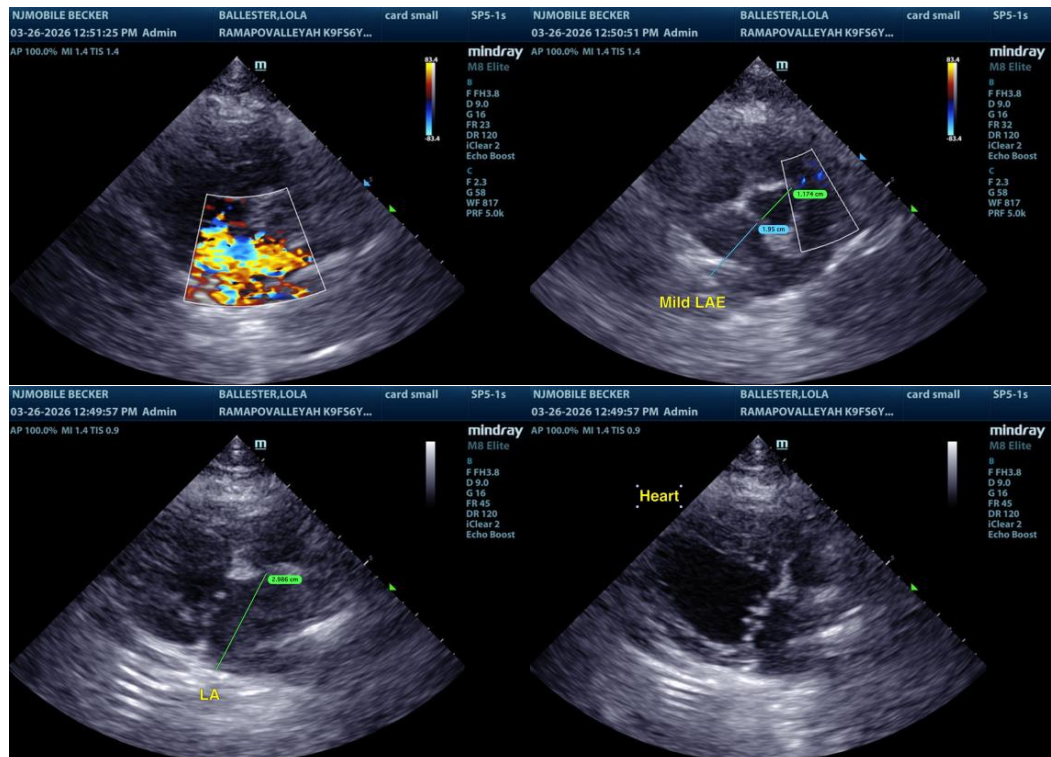
ULTRASONOGRAPHIC FINDINGS

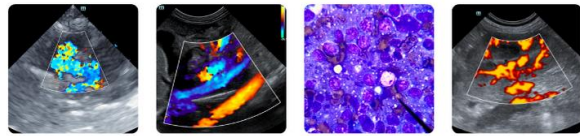
- Chronic mitral valve disease (ACVIM mild B2)
- Mild TV insufficiency – no evidence of clinical pulmonary hypertension

INTERPRETATION OF THE FINDINGS & FURTHER RECOMMENDATIONS

The cause of the murmur is chronic degenerative valvular changes with secondary eccentric mitral valve insufficiency. The left atrial enlargement implies that the risk of complications secondary to mitral valve insufficiency is elevated, yet overall the heart appears stable. No other clinical issues such as LV systolic dysfunction or clinical pulmonary hypertension. Pimobendan 0.3 mg/kg BID is recommended. No overt indication for additional medication. Prognosis is considered variable and sonographic monitoring is recommended. Recheck echocardiogram is suggested in 6 months, sooner if clinical signs arise. Anesthetic risk is considered mild, yet likely mildly reduced once on Pimobendan for 3-5 days. The following anesthetic protocol is suggested with clinical monitoring and appropriate to judicious IV fluid administration.

Suggested anesthetic protocol may include opioid or Benzodiazepine pre-med, induction with Propofol or Alfaxalone, and appropriate gas anesthesia with avoidance of alpha 2 agonists.





PATIENT

Lola Ballester

SPECIES

Canine

BREED

Pomeranian

SEX

FS

AGE

6 years, 10 months

WEIGHT

13.6 lbs.

INTERPRETED BY

R. McKenzie Daniel,
DVM, DABVP
(Canine and Feline)

IMAGING PERFORMED BY

Kerri Becker

HOSPITAL NAME

Ramapo Valley AH

REFERRING VET

Dr. Katara

INVOICE

10732

DATE

3/26/26

The information and recommendations provided are based on the images presented by the referring veterinarian/sonographer. No evaluation can be communicated regarding pathology that was not visible in the image/video clips provided.

Thank you for this referral. If the clinical or image interpretation does not parallel your findings or if I can be of any further assistance, please contact me.

R. McKenzie Daniel, DVM, DABVP (Canine / Feline Practice)
info@sonopath.com