



PATIENT PRESENTING CLINICAL SIGNS

Mia Deuries

History:

SPECIES

Canine

- V+ not eating- possible pancreatic issues
- Tense abd.

BREED

Yorkie

Abnormal PE/Chem/CBC/UA Results: cPL-abnormal chol-350 alt-163 alp-189 neu-14.47 lymp-0.79 eos-0.03 plt-46 pct-0.04

SEX

Female Spayed

AGE

15y 10m

WEIGHT

5.5 lbs

ULTRASONOGRAPHIC EXAMINATION OF THE HEART & ABDOMEN

CANINE CARDIAC PARAMETERS	MR VMAX (m/s)	TR VMAX (m/s)	LA/AO (M-Mode)	LA/AO (Heart Base; Swe)	FS (%)	EF (%)	EPSS (cm)
NORMAL PARAMETER	4.5-5.5	<2.7	1.3	Up to 1.6	28-40	40-100	<0.6
PATIENT	--	2.0	--	NM	45	78	0.2
CANINE CARDIAC PARAMETERS	HR (BPM)	AV VMAX (m/s)	PV MAX (m/s)	BODY WEIGHT (kg)	LAD LA MAX 4 Chamber	LVIDd Avg; 2D and m-mode short axis (cm)	LVIDs Avg; 2D and m-mode short axis (cm)
NORMAL PARAMETER	50-100	0.7-1.7	0.7-1.6				
PATIENT	NM	1.0	0.7	--	1.8	1.6	--

INTERPRETED BY

R. McKenzie Daniel, DVM, DABVP (Canine and Feline)

IMAGING PERFORMED BY

Kerri Becker

HOSPITAL NAME

Newton VH

REFERRING VET

Dr. Timony

INVOICE

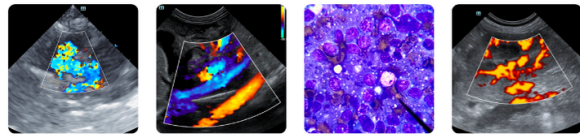
13320

DATE

3/25/26

Cardiac Presentation

The echocardiogram in this patient demonstrated normal **left atrial** size based on 3 different LA measurement methods. The cranial and caudal **mitral** valve leaflets presented thickening consistent with endocardiosis. Doppler indicated mild eccentric MR. The **left ventricle** presented thicknesses with linear contour and was not dilated nor restricted. The **myocardium** presented normal echogenicity without subjective evidence of significant fibrotic or ischemic disease. **Contractility** of the ventricular walls was adequate and in normal range for this patient evidenced by the fractional shortening measurement and subjective evaluation of the different regions of the myocardium. The **left ventricular outflow** tract demonstrated normal laminar flow and subjective structural integrity. The **right atrium** and auricle revealed normal size, structure and content. No evidence of masses was noted or chamber overload. **Tricuspid** valvular assessment demonstrated mildly thickened TR noted on doppler. Measured TR velocity 2.0 m/s.. The **right ventricle** was of normal size (1/3 diameter of LV), chordae structure, myocardial echogenicity and thickness. **Pulmonic** tract assessment revealed normal valve structure, laminar flow, and diameter (approx.1:1 pa/ao ratio). No visible **pericardial** or free



PATIENT

Mia Deuries

pleura fluid was noted. No echographically detectable evidence of cardiac / pericardial tumors was visible.

SPECIES

Canine

Urinary System

The urinary bladder, trigone, cystourethral junction, and visible pelvic urethra exhibited normal thickness and tone. Anechoic urine was present in the lumen with no uroliths or sediment. The ureteral papillae were normal. The ureters were not visible which is normal. No evidence of inflammatory or neoplastic changes were noted.

BREED

Yorkie

Normal size and margination was present in the kidneys. A normal 1:3 cortex / medulla ratio was maintained. The medulla and cortices were uniform in texture with some increased echogenicity and moderate loss of corticomedullary symmetry and definition expected for the age of the patient. Minor pyelectasia was present. The left kidney measured 3.3 cm in length. The right kidney measured 3.5 cm in length.

SEX

Female Spayed

AGE

15y 10m

Adrenal Glands

The left adrenal gland was mildly enlarged in size. Mild parenchyma heterogeneity and mild capsule asymmetry was present without suspicion for overt neoplasia. The left adrenal gland measured 0.65 cm width in the caudal pole. The right adrenal gland was indistinctly visualized exhibiting subjective normal size measuring 0.41 cm width at the caudal pole.

WEIGHT

5.5 lbs

Spleen

The spleen exhibited a finely textured and homogenous parenchyma which was hyperechoic to the liver and renal cortical parenchyma. The capsule was smooth and regular without apparent expansion. The splenic vasculature at the hilus was normal in volume with no evidence of congestion or thrombosis. Acute to chronic inflammatory, neoplastic, or benign parenchyma changes were not noted.

INTERPRETED BY

R. McKenzie Daniel,
DVM, DABVP
(Canine and Feline)

Liver

The liver presented borderline mildly enlarged in size. The parenchyma of the liver was subjectively normal in echogenicity compared to the spleen and renal cortices. The liver parenchyma was uniform with a mildly coarse echotexture. The capsule of the liver was symmetrically rounded to mildly swollen in margination. The hepatic and portal vasculature were normal in appearance without signs of congestion. The gallbladder was non distended in size with mild, congealed, non-organized, echogenic, nonmineralized biliary sludge. The cystic duct and common bile ducts were normal without evidence of dilation.

**IMAGING
PERFORMED BY**

Kerri Becker

HOSPITAL NAME

Newton VH

REFERRING VET

Dr. Timony

Gastrointestinal

The stomach exhibited a thickened wall with intact wall layering was maintained and distinct. The stomach contained a mild amount of anechoic fluid.

INVOICE

13320

The small intestine presented intact wall layering with mildly thickened duodenum wall and mild, non-obstructive upper duodenal ileus. No evidence of additional small intestinal ileus or obstructive pattern.

DATE

3/25/26

Normal visible colon wall layers were present with apparent formed feces in lumen.

Pancreas



PATIENT

Mia Deuries

SPECIES

Canine

BREED

Yorkie

SEX

Female Spayed

AGE

15y 10m

WEIGHT

5.5 lbs

INTERPRETED BY

R. McKenzie Daniel,
 DVM, DABVP
 (Canine and Feline)

IMAGING PERFORMED BY

Kerri Becker

HOSPITAL NAME

Newton VH

REFERRING VET

Dr. Timony

INVOICE

13320

DATE

3/25/26

The left limb, right limb, and base of the pancreas presented hypoechoic to heterogeneous echogenicity compared to adjacent omental fat. Mild asymmetrical capsule margination was present with mild variable parenchymal swelling and minor peripancreatic to right cranial abdomen effusion. Regional peripancreatic hyperechoic omentum.

Free Abdomen

No overt lymphadenopathy or peritoneal effusion was present.

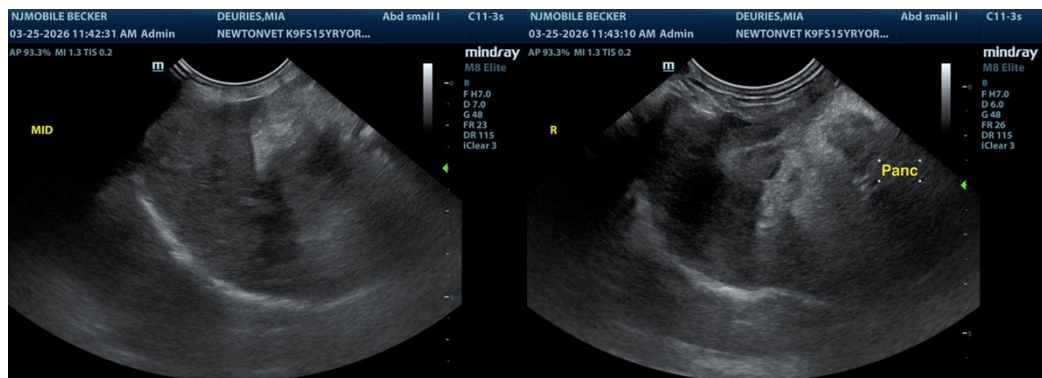
ULTRASONOGRAPHIC FINDINGS

- Mitral valve insufficiency (B1)
- Mild TV insufficiency – no evidence of clinical pulmonary hypertension
- Pancreatitis with peripancreatic reactive/inflamed omentum, minor effusion
- Hypomotile gastroduodenitis
- Mild hepatomegaly
- Non-organized gallbladder debris (non-mucocele)
- Chronic renal changes with minor pyelectasia
- Mild left adrenomegaly

INTERPRETATION OF THE FINDINGS & FURTHER RECOMMENDATIONS

The primary cause of the patient's clinical signs is pancreatitis with associated upper gastrointestinal inflammation and probable associated or secondary reactive vacuolar or possible inflammatory hepatopathy. Potential for pancreatic neoplasia thought less likely. Hospitalization with empirical therapy for pancreatitis and concurrent gastrointestinal support with clinical and as needed sonographic monitoring if progressive gastrointestinal signs, hepatopathy or cholestasis is recommended.

No indication for cardiac medication at this stage. Anesthetic risk is considered low. If required, the following protocol is suggested. Suggested anesthetic protocol may include opioid or Benzodiazepine pre-med, induction with Propofol or Alfaxalone, and appropriate gas anesthesia with avoidance of alpha 2 agonists.





PATIENT

Mia Deuries

SPECIES

Canine

BREED

Yorkie

SEX

Female Spayed

AGE

15y 10m

WEIGHT

5.5 lbs

INTERPRETED BY

R. McKenzie Daniel,
 DVM, DABVP
 (Canine and Feline)

IMAGING PERFORMED BY

Kerri Becker

HOSPITAL NAME

Newton VH

REFERRING VET

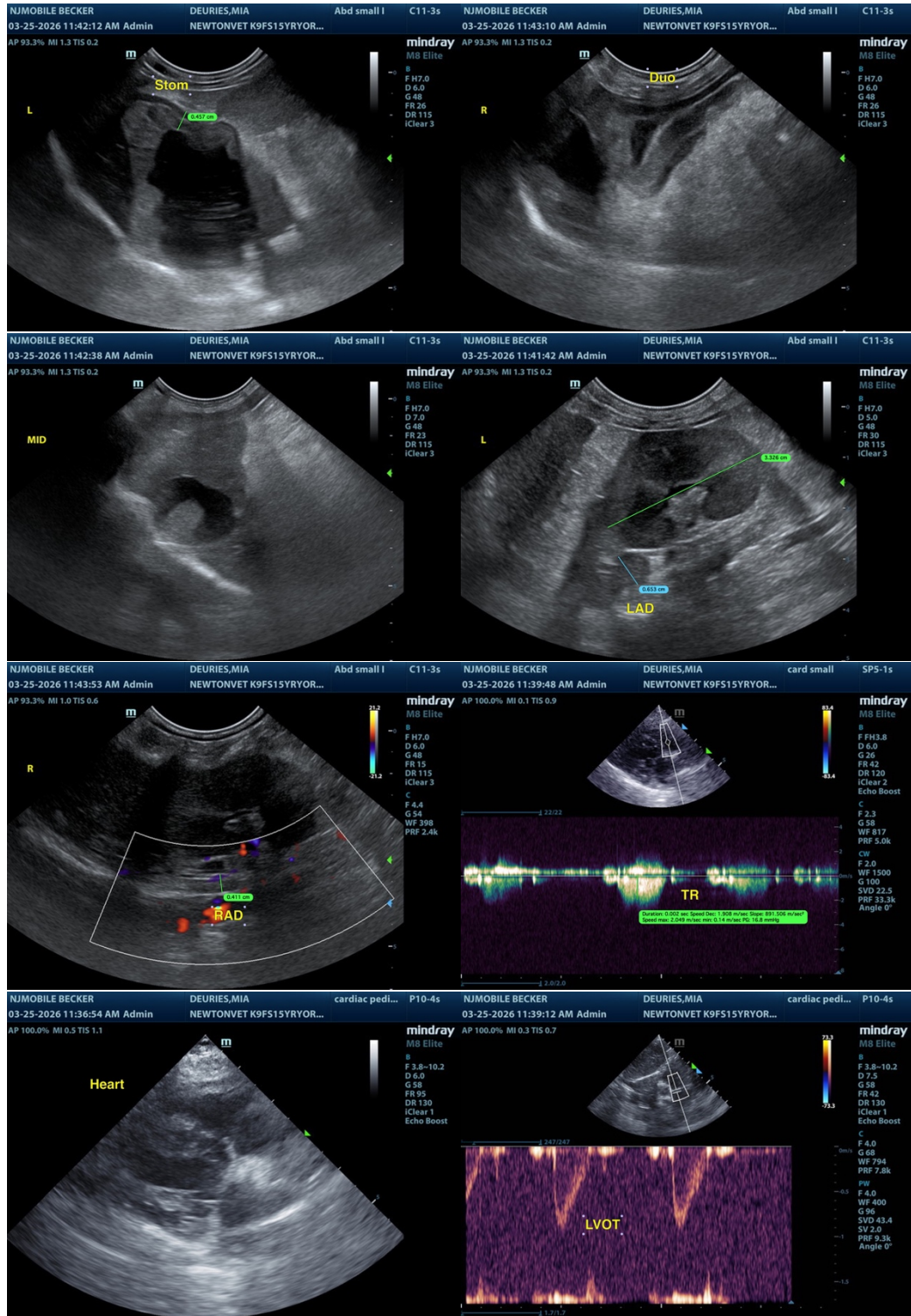
Dr. Timony

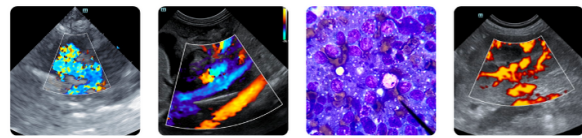
INVOICE

13320

DATE

3/25/26





PATIENT

Mia Deuries

SPECIES

Canine

BREED

Yorkie

SEX

Female Spayed

AGE

15y 10m

WEIGHT

5.5 lbs

INTERPRETED BY

R. McKenzie Daniel,
 DVM, DABVP
 (Canine and Feline)

IMAGING PERFORMED BY

Kerri Becker

HOSPITAL NAME

Newton VH

REFERRING VET

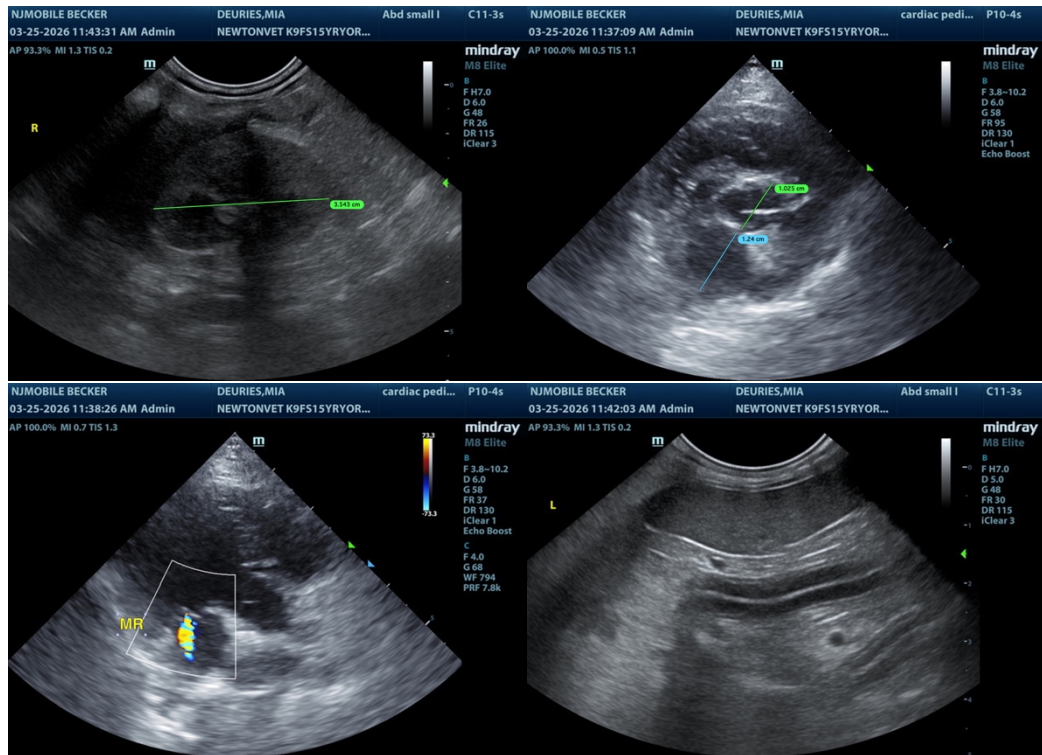
Dr. Timony

INVOICE

13320

DATE

3/25/26



The information and recommendations provided are based on the images presented by the referring veterinarian/sonographer. No evaluation can be communicated regarding pathology that was not visible in the image/video clips provided.

Thank you for this referral. If the clinical or image interpretation does not parallel your findings or if I can be of any further assistance, please contact me.

R. McKenzie Daniel, DVM, DABVP (Canine / Feline Practice)

info@sonopath.com