



**PATIENT**

Butch Waruch

**SPECIES**

Canine

**BREED**

Spaniel

**SEX**

MN

**AGE**

12 years, 5 months

**WEIGHT**

27.7 lbs.

**INTERPRETED BY**

R. McKenzie Daniel,  
DVM, DABVP  
(Canine and Feline)

**IMAGING PERFORMED BY**

Chloe Lowe, CVT

**HOSPITAL NAME**

Rondout Valley  
Veterinary Associates

**REFERRING VET**

Dr. Laux

**INVOICE**

10722

**DATE**

3/25/26

**PRESENTING CLINICAL SIGNS**

History:

- grade 4 right and left cardiac murmur.
- murmur heard on physical exam and looking for more information

Abnormal PE/Chem/CBC/UA Results: WNL

**ULTRASONOGRAPHIC EXAMINATION OF THE HEART**

CANINE CARDIAC PARAMETERS	MR VMAX (m/s)	TR VMAX (m/s)	LA/AO (M-Mode)	LA/AO (Heart Base; Swe)	FS (%)	EF (%)	EPSS (cm)
NORMAL PARAMETER	4.5-5.5	<2.7	1.3	Up to 1.6	28-40	40-100	<0.6
PATIENT	-	-	-	1.7	53	85	0.2
CANINE CARDIAC PARAMETERS	HR (BPM)	AV VMAX (m/s)	PV MAX (m/s)	BODY WEIGHT	LAD LA MAX 4 Chamber	LVIDd Avg; 2D and m-mode short axis (cm)	LVIDs Avg; 2D and m-mode short axis (cm)
NORMAL PARAMETER	50-100	0.7-1.7	0.7-1.6				
PATIENT	157	1.6	1.0	27.7 lbs	3.9	3.4	-

**Cardiac Presentation**

The echocardiogram in this patient demonstrated mild increased **left atrial** size based on 2 different LA measurement methods. The cranial and caudal **mitral** valve leaflets presented thickening consistent with endocardiosis. Mild valve prolapse was noted. Doppler indicated measurable eccentric MR (MR velocity 5.2 m/s). The **left ventricle** presented thicknesses with linear contour and was not dilated nor restricted. The **myocardium** presented normal echogenicity without subjective evidence of significant fibrotic or ischemic disease. **Contractility** of the ventricular walls was adequate and in normal range for this patient evidenced by the fractional shortening measurement and subjective evaluation of the different regions of the myocardium. The **left ventricular outflow** tract demonstrated normal laminar flow and subjective structural integrity. The **right atrium** and auricle revealed normal size, structure and content. No evidence of masses was noted or chamber overload. **Tricuspid** valvular assessment demonstrated adequate linear morphology. The **right ventricle** was of normal size (1/3 diameter of LV), chordae structure, myocardial echogenicity and thickness. **Pulmonic** tract assessment revealed normal valve structure, laminar flow, and diameter (approx. 1:1 pa/ao ratio). No visible **pericardial** or free pleura fluid was noted. No echographically detectable evidence of cardiac / pericardial tumors was visible.



**PATIENT**

Butch Waruch

**SPECIES**

Canine

**BREED**

Spaniel

**SEX**

MN

**AGE**

12 years, 5 months

**WEIGHT**

27.7 lbs.

**INTERPRETED BY**

R. McKenzie Daniel,  
 DVM, DABVP  
 (Canine and Feline)

**IMAGING PERFORMED BY**

Chloe Lowe, CVT

**HOSPITAL NAME**

Rondout Valley  
 Veterinary Associates

**REFERRING VET**

Dr. Laux

**INVOICE**

10722

**DATE**

3/25/26

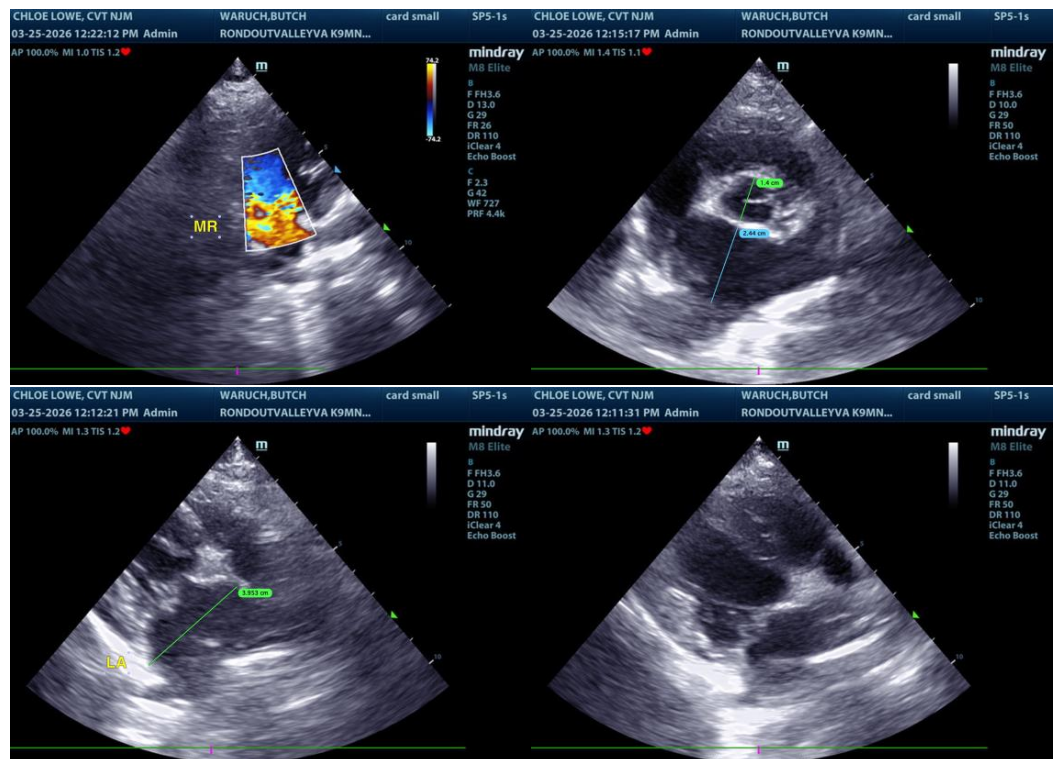
**ULTRASONOGRAPHIC FINDINGS**

- Chronic mitral valve disease with mild valve prolapse (ACVIM mild B2)

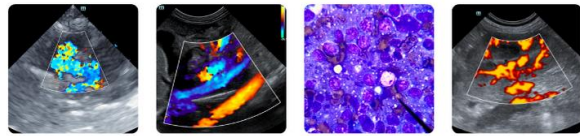
**INTERPRETATION OF THE FINDINGS & FURTHER RECOMMENDATIONS**

The cause of the murmur is chronic degenerative valvular changes with secondary eccentric mitral valve insufficiency. The left atrial enlargement implies that the risk of complication secondary to mitral valve insufficiency is elevated, yet overall the heart appears stable. No other clinical issues such as LV systolic dysfunction or clinical pulmonary hypertension. Pimobendan 0.3 mg/kg BID is recommended. No overt indication for additional medication. Prognosis is considered variable and sonographic monitoring is recommended. Recheck echocardiogram is suggested in 6 months, sooner if clinical signs arise. Anesthetic risk is considered mild. If required, the following protocol is recommended.

Suggested anesthetic protocol may include opioid or Benzodiazepine pre-med, induction with Propofol or Alfaxalone, and appropriate gas anesthesia with avoidance of alpha 2 agonists.



The information and recommendations provided are based on the images presented by the referring veterinarian/sonographer. No evaluation can be communicated regarding pathology that was not visible in the image/video clips provided.



**PATIENT**

Butch Waruch

Thank you for this referral. If the clinical or image interpretation does not parallel your findings or if I can be of any further assistance, please contact me.

**SPECIES**

Canine

**R. McKenzie Daniel, DVM, DABVP (Canine / Feline Practice)**  
[info@sonopath.com](mailto:info@sonopath.com)

**BREED**

Spaniel

**SEX**

MN

**AGE**

12 years, 5 months

**WEIGHT**

27.7 lbs.

**INTERPRETED BY**

R. McKenzie Daniel,  
DVM, DABVP  
(Canine and Feline)

**IMAGING PERFORMED BY**

Chloe Lowe, CVT

**HOSPITAL NAME**

Rondout Valley  
Veterinary Associates

**REFERRING VET**

Dr. Laux

**INVOICE**

10722

**DATE**

3/25/26