



PATIENT

Bryce Mayhood

SPECIES

Canine

BREED

Whippet

SEX

Neutered Male

AGE

11 Years 3 Months

WEIGHT

54 pounds

INTERPRETED BY

R. McKenzie Daniel,
DVM, DABVP (Canine
/ Feline Practice)

IMAGING PERFORMED BY

Kerri Becker

HOSPITAL NAME

Newton Veterinary
Hospital

REFERRING VET

Dr. Wyman-Greenwald

INVOICE

14603

DATE

03/25/26

PRESENTING CLINICAL SIGNS

- Grade 2/6 systolic hm, asymptomatic but is scheduled for dental under anesthesia.

ULTRASONOGRAPHIC EXAMINATION OF THE HEART

CANINE CARDIAC PARAMETERS	MR VMAX (m/s)	TR VMAX (m/s)	LA/AO (M-Mode)	LA/AO (Heart Base; Swe)	FS (%)	EF (%)	EPSS (cm)
NORMAL PARAMETER	4.5-5.5	<2.7	1.3	Up to 1.6	28-40	40-100	<0.6
PATIENT	--	--	NM	1.3	40	74	0.1
CANINE CARDIAC PARAMETERS	HR (BPM)	AV VMAX (m/s)	PV MAX (m/s)	BODY WEIGHT (lbs)	LAD LA MAX 4 Chamber	LVIDd Avg; 2D and m-mode short axis (cm)	LVIDs Avg; 2D and m-mode short axis (cm)
NORMAL PARAMETER	50-100	0.7-1.7	0.7-1.6				
PATIENT	134	1.2	1.5	54.0	3.2	3.2	--

Cardiac Presentation

The echocardiogram in this patient demonstrated normal **left atrial** size based on 2 different LA measurement methods. The cranial and caudal **mitral** valve leaflets presented mild thickening consistent with mild endocardiosis. Doppler revealed mild eccentric MR. The **left ventricle** presented thicknesses with linear contour and was not dilated nor restricted. The **myocardium** presented normal echogenicity without subjective evidence of significant fibrotic or ischemic disease. **Contractility** of the ventricular walls was adequate and in normal range for this patient evidenced by the fractional shortening measurement and subjective evaluation of the different regions of the myocardium. The **left ventricular outflow** tract demonstrated normal laminar flow and subjective structural integrity. The **right atrium** and auricle revealed normal size, structure and content. No evidence of masses was noted or chamber overload. **Tricuspid** valvular assessment demonstrated adequate linear morphology. The **right ventricle** was of normal size (1/3 diameter of LV), chordae structure, myocardial echogenicity and thickness. **Pulmonic** tract assessment revealed normal valve structure, laminar flow, and diameter (approx.1:1 pa/ao ratio). Minor pulmonic insufficiency on doppler. No visible **pericardial** or free pleura fluid was noted. No echographically detectable evidence of cardiac / pericardial tumors was visible.

ULTRASONOGRAPHIC FINDINGS

- Compensated mitral valve insufficiency (B1).
- Minor pulmonic valve insufficiency- not hemodynamically significant.



PATIENT

Bryce Mayhood

SPECIES

Canine

BREED

Whippet

SEX

Neutered Male

AGE

11 Years 3 Months

WEIGHT

54 pounds

INTERPRETED BY

R. McKenzie Daniel,
 DVM, DABVP (Canine / Feline Practice)

IMAGING PERFORMED BY

Kerri Becker

HOSPITAL NAME

Newton Veterinary Hospital

REFERRING VET

Dr. Wyman-Greenwald

INVOICE

14603

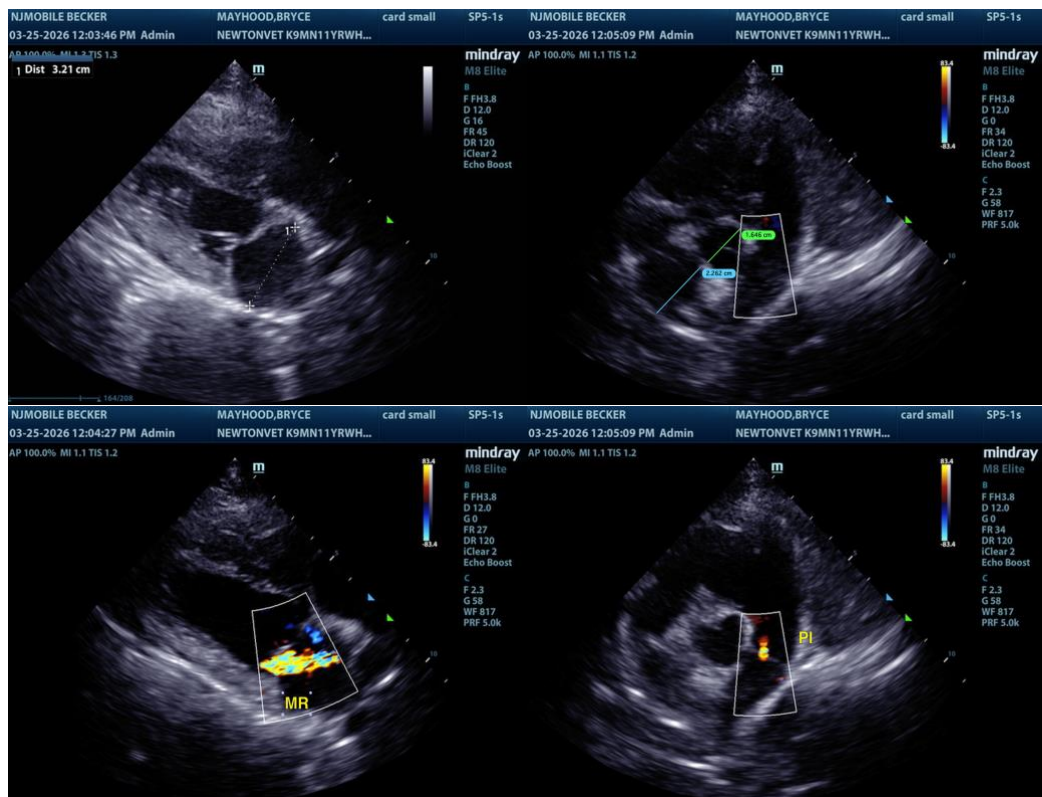
DATE

03/25/26

INTERPRETATION OF THE FINDINGS & FURTHER RECOMMENDATIONS

The cause of the murmur is chronic degenerative valvular changes with secondary eccentric mitral valve insufficiency. The lack of left atrial enlargement implies that the risk of complication secondary to mitral valve insufficiency is low at this time and, without current clinical signs, indicates that medical therapy is not required. Prognosis is considered variable and sonographic monitoring is recommended. Recheck echo cardiogram is suggested in 6-12 months, sooner if clinical signs arise.

No anesthetic contraindications. Suggested anesthetic protocol may include opioid or Benzodiazepine pre-med, induction with Propofol or Alfaxalone, and appropriate gas anesthesia with avoidance of alpha 2 agonists.



The information and recommendations provided are based on the images presented by the referring veterinarian/sonographer. No evaluation can be communicated regarding pathology that was not visible in the image/video clips provided.

Thank you for this referral. If the clinical or image interpretation does not parallel your findings or if I can be of any further assistance, please contact me.

R. McKenzie Daniel, DVM, DABVP (Canine / Feline Practice)

info@SonoPath.com