



PATIENT PRESENTING CLINICAL SIGNS

Teddy Antunes

SPECIES

Canine

BREED

Bichon Frise Mix

SEX

MN

AGE

18 y

WEIGHT

13.6 lbs.

INTERPRETED BY

R. McKenzie Daniel,
DVM, DABVP
(Canine and Feline)

IMAGING PERFORMED BY

Vincent Ravancho, CVT

HOSPITAL NAME

Whippany VH

REFERRING VET

Dr. Enoch

INVOICE

10706

DATE

3/24/26

History:

- L-Sided Grade II/VI Heart murmur
- Pre-dental workup - severe dental disease
- Current medications - gabapentin 60 mg PO BID, Clindamycin 75 mg PO BID, NG+ for prevention.

Abnormal PE/Chem/CBC/UA Results: SDMA 20, BUN 50, ALP 244 U/A - pH 5.5, trace protein, 1+ blood (cysto), USG 1.016

ULTRASONOGRAPHIC EXAMINATION OF THE HEART

CANINE CARDIAC PARAMETERS	MR VMAX (m/s)	TR VMAX (m/s)	LA/AO (M-Mode)	LA/AO (Heart Base; Swe)	FS (%)	EF (%)	EPSS (cm)
NORMAL PARAMETER	4.5-5.5	<2.7	1.3	Up to 1.6	28-40	40-100	<0.6
PATIENT	5.4	2.7 MAX	-	1.1	40	75	0.2
CANINE CARDIAC PARAMETERS	HR (BPM)	AV VMAX (m/s)	PV MAX (m/s)	BODY WEIGHT	LAD LA MAX4 Chamber	LVIDd Avg; 2D and m-mode short axis (cm)	LVIDs Avg; 2D and m-mode short axis (cm)
NORMAL PARAMETER	50-100	0.7-1.7	0.7-1.6				
PATIENT	133	1.2	1.0	13.6 lbs.	3.0	2.6	-

Cardiac Presentation

The echocardiogram in this patient demonstrated normal **left atrial** size based on 2 different LA measurement methods. The cranial and caudal **mitral** valve leaflets presented thickening consistent with endocardiosis. Doppler indicated measurable moderate eccentric MR (MR velocity 5.4 m/s). The **left ventricle** presented thicknesses with linear contour and was not dilated nor restricted. The **myocardium** presented normal echogenicity without subjective evidence of significant fibrotic or ischemic disease. **Contractility** of the ventricular walls was adequate and in normal range for this patient evidenced by the fractional shortening measurement and subjective evaluation of the different regions of the myocardium. The **left ventricular outflow** tract demonstrated normal laminar flow and subjective structural integrity. The **right atrium** and auricle revealed normal size, structure and content. No evidence of masses was noted or chamber overload. **Tricuspid** valvular assessment demonstrated mild thickening with mild TR on Doppler (measured TR velocity 2.7 m/s MAX). The **right ventricle** was of normal size (1/3 diameter of LV), chordae structure, myocardial echogenicity and thickness. **Pulmonic** tract assessment revealed normal valve structure, laminar flow, and diameter (approx.1:1 pa/ao ratio). No visible **pericardial** or free pleura fluid was noted. No echographically detectable evidence of cardiac / pericardial tumors was visible.



PATIENT

Teddy Antunes

SPECIES

Canine

BREED

Bichon Frise Mix

SEX

MN

AGE

18 y

WEIGHT

13.6 lbs.

INTERPRETED BY

R. McKenzie Daniel,
DVM, DABVP
(Canine and Feline)

IMAGING PERFORMED BY

Vincent Ravancho, CVT

HOSPITAL NAME

Whippany VH

REFERRING VET

Dr. Enoch

INVOICE

10706

DATE

3/24/26

ULTRASONOGRAPHIC FINDINGS

- Chronic mitral valve disease (B1)
- TV insufficiency - no evidence of clinical pulmonary hypertension

INTERPRETATION OF THE FINDINGS & FURTHER RECOMMENDATIONS

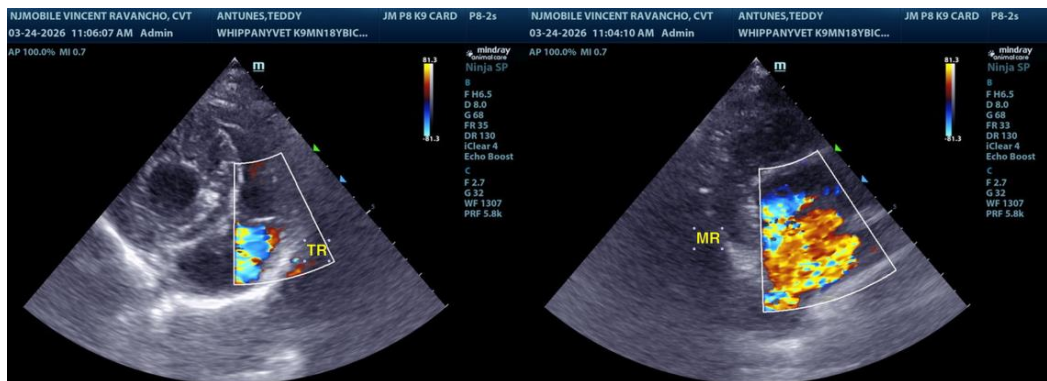
The cause of the murmur is chronic degenerative valvular changes with secondary eccentric mitral valve insufficiency. The lack of left atrial enlargement implies that the risk of complication secondary to mitral valve insufficiency is low at this time and, without current clinical signs, indicates that medical therapy is not required. Prognosis is considered variable and sonographic monitoring is recommended. Recheck echocardiogram is suggested in 6-12 months, sooner if clinical signs arise.

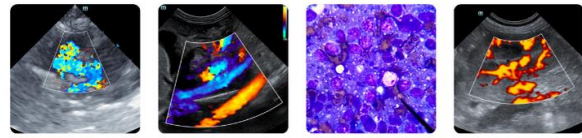
Anesthetic risk is considered normal to mild: No gross abnormalities noted on SDEP^R Screening Echo to contraindicate anesthesia. Minimal to no left atrial enlargement noted on images presented.

1. However, judicious fluid administration is advised with careful RR/RE monitoring to screen for fluid overload.

Monitoring of blood pressure, SpO₂, CO₂, and auscultation of heart and lungs during anesthesia should be done during every procedure.

Suggested anesthetic protocol may include opioid or Benzodiazepine pre-med, induction with Propofol or Alfaxalone, and appropriate gas anesthesia with avoidance of alpha 2 agonists.





PATIENT

Teddy Antunes

SPECIES

Canine

BREED

Bichon Frise Mix

SEX

MN

AGE

18 y

WEIGHT

13.6 lbs.

INTERPRETED BY

R. McKenzie Daniel,
DVM, DABVP
(Canine and Feline)

IMAGING PERFORMED BY

Vincent Ravancho, CVT

HOSPITAL NAME

Whippany VH

REFERRING VET

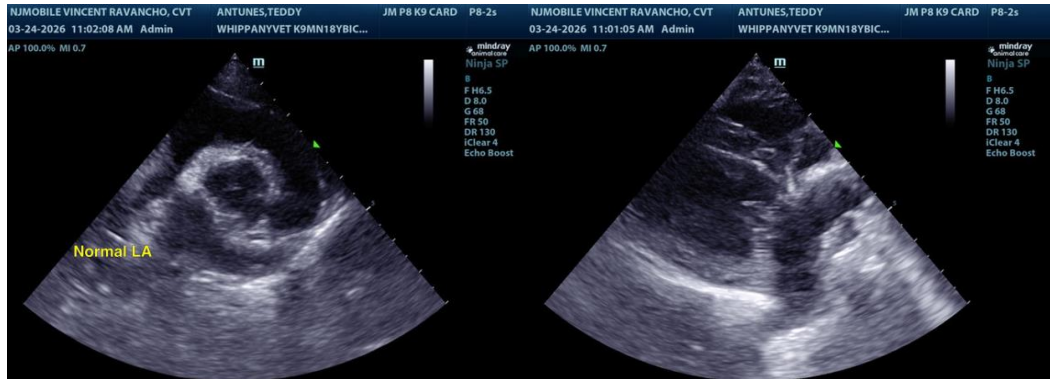
Dr. Enoch

INVOICE

10706

DATE

3/24/26



The information and recommendations provided are based on the images presented by the referring veterinarian/sonographer. No evaluation can be communicated regarding pathology that was not visible in the image/video clips provided.

Thank you for this referral. If the clinical or image interpretation does not parallel your findings or if I can be of any further assistance, please contact me.

R. McKenzie Daniel, DVM, DABVP (Canine / Feline Practice)
info@sonopath.com