



PATIENT

Teak Dubiel

SPECIES

Canine

BREED

Chihuahua Mix

SEX

Female Spayed

AGE

6y

WEIGHT

16 lbs

INTERPRETED BY

R. McKenzie Daniel,
DVM, DABVP
(Canine and Feline)

IMAGING PERFORMED BY

Chloe Lowe, CVT

HOSPITAL NAME

Loving Care VH

REFERRING VET

Dr. Steele

INVOICE

13309

DATE

3/24/26

PRESENTING CLINICAL SIGNS

History:

- PU/PD

Abnormal PE/Chem/CBC/UA Results: UA: Glucose 1+, crystals 2+ USG 1.033

ULTRASONOGRAPHIC EXAMINATION OF THE ABDOMEN

Urinary System

The urinary bladder, trigone, cystourethral junction, and visible pelvic urethra to a depth of 3.0 cm exhibited normal thickness and tone. Anechoic urine was present in the lumen with no uroliths or sediment. The ureteral papillae were normal. The ureters were not visible which is normal. No evidence of inflammatory or neoplastic changes were noted.

Normal size and margination was present in the kidneys. A normal 1:3 cortex / medulla ratio and normal corticomedullary definition were maintained. The echogenicity of the cortex was similar to or slightly less than normal liver parenchyma while the medulla echogenicity was hypoechoic to the cortex with no evidence of pelvic dilation. The left kidney measured 4.1 cm in length. The right kidney measured 4.3 cm in length.

Adrenal Glands

The left adrenal gland was uniform in size and contour with a uniformly hypoechoic parenchyma. The left adrenal gland measured 0.44 cm width at the caudal pole. The right adrenal gland was uniform in size and contour with a uniformly hypoechoic parenchyma. The right adrenal gland measured 0. The stomach presented intact wall layering with a normal wall layer ratio. The lumen of the stomach contained echogenic, non-shadowing ingesta without signs of obstruction or foreign material 0.46 cm width at the caudal pole.

Spleen

The spleen exhibited a finely textured and homogenous parenchyma which was hyperechoic to the liver and renal cortical parenchyma. The capsule was smooth and regular without apparent expansion. The splenic vasculature at the hilus was normal in volume with no evidence of congestion or thrombosis. Acute to chronic inflammatory, neoplastic, or benign parenchyma changes were not noted.

Liver

The liver presented mildly enlarged in size with normal hepatic vasculature volume. The parenchyma of the liver was subjectively normal in echogenicity compared to the spleen and renal cortices. The liver parenchyma was uniform with a mildly coarse echotexture. The capsule of the liver was symmetrically rounded to mildly swollen in margination. The hepatic and portal vasculature were normal in appearance without signs of congestion. The gallbladder was non distended in size with mild, non-organized, echogenic, nonmineralized biliary sludge. The cystic duct and common bile ducts were normal without evidence of dilation.



PATIENT

Gastrointestinal

Teak Dubiel

The stomach presented intact wall layering with a normal wall layer ratio. The lumen of the stomach contained mild, echogenic, non-shadowing ingesta/chyme

SPECIES

Canine

The small intestine presented intact wall layering with 1:3 muscularis/mucosa ratio. The lumen of the small intestine was empty with no signs of ileus, obstruction or foreign material.

BREED

Chihuahua Mix

Normal visible colon wall layers were present with apparent formed feces in lumen.

SEX

Female Spayed

Pancreas

The parenchyma of the left limb, body and right limb of the pancreas presented isoechoic to the adjacent omental fat. A normal curvilinear capsule contour of the pancreas was present. The visible pancreatic duct was normal. No signs of active inflammation or neoplastic disease was evident.

AGE

6y

Free Abdomen

No overt lymphadenopathy or peritoneal effusion was present.

WEIGHT

16 lbs

ULTRASONOGRAPHIC FINDINGS

- Mild hepatomegaly
- Mild gallbladder debris (non-mucocele)
- Normal bilateral kidneys/adrenal glands

INTERPRETED BY

R. McKenzie Daniel,
 DVM, DABVP
 (Canine and Feline)

INTERPRETATION OF THE FINDINGS & FURTHER RECOMMENDATIONS

No evidence of visceral pathology as an obvious cause of the patient's clinical signs consistent with Cushing's Syndrome despite lack of adrenal pathology. Further assessment may include, if clinically applicable, bile acid profile and leptospirosis titer/PCR.

IMAGING PERFORMED BY

Chloe Lowe, CVT

HOSPITAL NAME

Loving Care VH

REFERRING VET

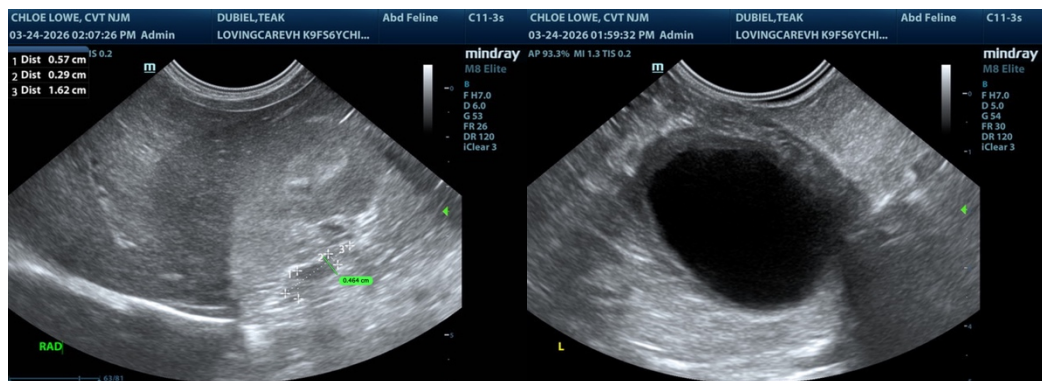
Dr. Steele

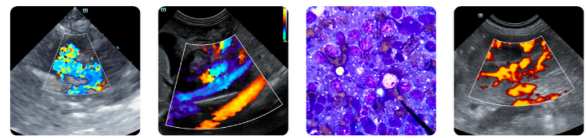
INVOICE

13309

DATE

3/24/26





PATIENT

Teak Dubiel

SPECIES

Canine

BREED

Chihuahua Mix

SEX

Female Spayed

AGE

6y

WEIGHT

16 lbs

INTERPRETED BY

R. McKenzie Daniel,
 DVM, DABVP
 (Canine and Feline)

IMAGING PERFORMED BY

Chloe Lowe, CVT

HOSPITAL NAME

Loving Care VH

REFERRING VET

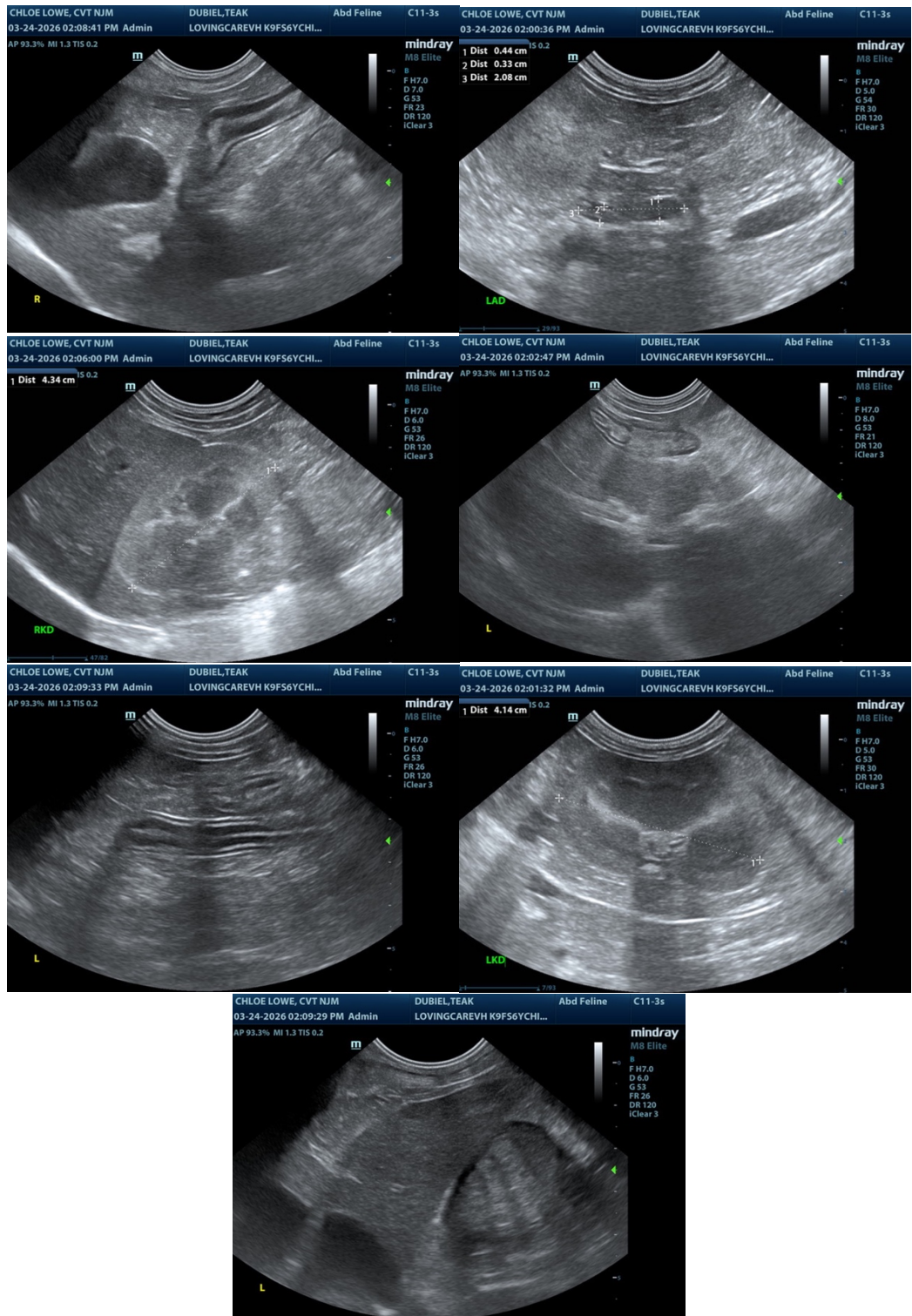
Dr. Steele

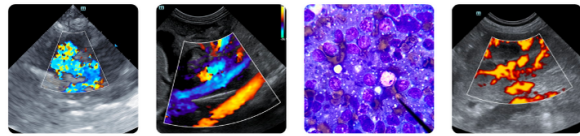
INVOICE

13309

DATE

3/24/26





PATIENT

Teak Dubiel

SPECIES

Canine

BREED

Chihuahua Mix

SEX

Female Spayed

AGE

6y

WEIGHT

16 lbs

INTERPRETED BY

R. McKenzie Daniel,
DVM, DABVP
(Canine and Feline)

IMAGING PERFORMED BY

Chloe Lowe, CVT

HOSPITAL NAME

Loving Care VH

REFERRING VET

Dr. Steele

INVOICE

13309

DATE

3/24/26

The information and recommendations provided are based on the images presented by the referring veterinarian/sonographer. No evaluation can be communicated regarding pathology that was not visible in the image/video clips provided.

Thank you for this referral. If the clinical or image interpretation does not parallel your findings or if I can be of any further assistance, please contact me.

R. McKenzie Daniel, DVM, DABVP (Canine / Feline Practice)

info@sonopath.com