SonoPath
Clinical Sonography & Telecytology
EDUCATIONAL TELECONSULTATION SERVICES™

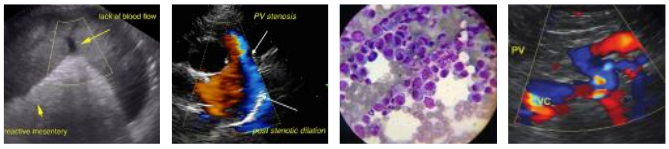


SonoPath.com™
1-800-838-4268 info@sonopath.com

**PATIENT**
Phillip Cross

**SPECIES**
Feline

**BREED**
DLH

**SEX**
MN

**AGE**
12 years

**WEIGHT**
5 kg

**INTERPRETED BY**
R. McKenzie Daniel, DVM, DABVP (Canine and Feline)

**IMAGING PERFORMED BY**
Dr. Callihan/Pacific Crest Mobile Veterinary Service

**HOSPITAL NAME**
Pacific Crest Mobile Veterinary Service

**REFERRING VET**
Dr Groff/Chuckanut Feline Center

**INVOICE**
16455

**DATE**
3/24/23

## PRESENTING CLINICAL SIGNS

Long term diabetic, recently uncontrolled. Melena. Generally grouchy with housemates past few months (uncharacteristic for him; weakness in the hindlimb; diabetic, Lantus insulin 4 IU SQ BID CBC: normal Chem: -glucose 363 -Cr 2.5 -BUN 44 -K 2.7 -GGT 6 -isosthenuria

## ULTRASONOGRAPHIC EXAMINATION OF THE ABDOMEN

### *Urinary System*

The urinary bladder, trigone, cystourethral junction, and visible pelvic urethra to a depth of 2.0 cm exhibited normal thickness and tone. Anechoic urine was present in the lumen with no uroliths or sediment. The ureteral papillae were normal. The ureters were not visible which is normal. No evidence of inflammatory or neoplastic changes was noted.

The area of the aortic trifurcation was free of pathology.

Normal size and margination were present in the kidneys. A normal 1:3 cortex / medulla ratio was maintained. The medulla and cortices were uniform in texture with some increased echogenicity and moderate loss of corticomedullary symmetry and definition expected for the age of the patient. No evidence of pelvic dilation was present. The left kidney measured 4.3 cm in length. The right kidney measured 4.5 cm in length.

### *Adrenal Glands*

The bilateral adrenal glands were mildly prominent in size with normal contour. Pinpoint areas of mineralization were present without capsular distortion or overt tumors. This is an age-related finding and not pathological. The left adrenal gland measured 0.5 width and the right adrenal gland measured 0.53 width.

### *Spleen*

The spleen exhibited a finely textured and homogenous parenchyma which was hyperechoic to the liver and renal cortical parenchyma. The capsule was smooth and regular without apparent expansion. The splenic vasculature at the hilus was normal in volume with no evidence of congestion or thrombosis. Acute to chronic inflammatory, neoplastic, or benign parenchyma changes were not noted.

### *Liver/ Gallbladder*

The liver presented mild to moderate enlarged in size. The parenchyma of the liver was subjectively normal in echogenicity compared to the spleen and renal cortices. The liver parenchyma was uniform with a mildly coarse echotexture. The capsule of the liver was symmetrically rounded to mildly swollen in margination. The hepatic and portal vasculature were normal in appearance without signs of congestion. The gallbladder was non-distended in size containing primarily anechoic content with mild, echogenic, nonorganized gallbladder debris. The cystic and common bile ducts were normal. No evidence of post hepatic obstructive criteria was noted.

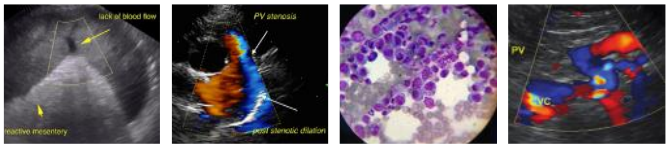


SonoPath.com™
1-800-838-4268 info@sonopath.com

**PATIENT**
Phillip Cross

**SPECIES**
Feline

**BREED**
DLH

**SEX**
MN

**AGE**
12 years

**WEIGHT**
5 kg

**INTERPRETED BY**
R. McKenzie Daniel, DVM, DABVP (Canine and Feline)

**IMAGING PERFORMED BY**
Dr. Callihan/Pacific Crest Mobile Veterinary Service

**HOSPITAL NAME**
Pacific Crest Mobile Veterinary Service

**REFERRING VET**
Dr Groff/Chuckanut Feline Center

**INVOICE**
16455

**DATE**
3/24/23

### *Gastrointestinal*

The stomach presented intact wall layering with a normal wall layer ratio. The lumen of the stomach was empty with no signs of ileus, obstruction, or foreign material.

The small intestine presented generalized intact segmental to generalized prominent wall layering. The duodenum wall measured 0.30 cm width. The jejunum wall measured 0.30 cm width. The ileocolic wall measured up to 0.50 cm width. No evidence of loss of intestinal wall layering, intestinal masses, or obstructive criteria.

Normal visible colon wall layers were present with semi-formed fecal matter.

### *Pancreas*

Generalized, variable to irregular, enlarged pancreas was present with capsule asymmetrical exhibiting nonhomogeneous, mildly hypoechoic, cystic pancreatic parenchyma compared to adjacent omentum.

### *Free Abdomen*

Intermittent mesenteric nodes were present. The lymph nodes were essentially isoechoic to adjacent omentum without evidence of peripheral inflammation and maintaining a normal width: length ratio (<0.5). Intermittent small pocket of scant peritoneal free fluid was noted. Generalized mild hyperechoic omentum was present. No omental masses were noted.

## ULTRASONOGRAPHIC FINDINGS

- Diabetic hepatomegaly pattern
- Mild gallbladder debris - no evidence of post hepatic obstruction
- Chronic renal changes
- Prominent irregular nonhomogeneous to cystic pancreas - subjective chronic active pancreatitis pattern
- Possible chronic enteropathy with associated subjective benign / reactive mesenteric lymphadenopathy
- Bilateral dystrophic adrenal mineralization - normal age-related finding in a cat
- Scant peritoneal effusion

## INTERPRETATION OF THE FINDINGS & FURTHER RECOMMENDATIONS

Further renal staging to include urine C/S and protein: creatinine ratio on sterile urine sample may be considered. A GI panel to include PLI/TLI/Cobalamin/Folate is warranted for further clarification of suspected chronic active pancreatitis and/or intestinal disease. Potential Triad Disease could be considered in this patient if evidence of hepatic inflammation.

SonoPath
Clinical Sonography & Telecytology
EDUCATIONAL TELECONSULTATION SERVICES™

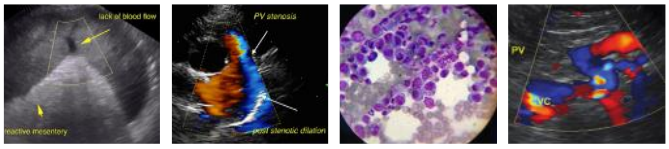

SonoPath.com™
1-800-838-4268 info@sonopath.com

**PATIENT**

Phillip Cross

**SPECIES**

Feline

**BREED**

DLH

**SEX**

MN

**AGE**

12 years

**WEIGHT**

5 kg

**INTERPRETED BY**

R. McKenzie Daniel, DVM, DABVP (Canine and Feline)

**IMAGING PERFORMED BY**

Dr. Callihan/Pacific Crest Mobile Veterinary Service

**HOSPITAL NAME**

Pacific Crest Mobile Veterinary Service

**REFERRING VET**

Dr Groff/Chuckanut Feline Center

**INVOICE**

16455

**DATE**

3/24/23

Potential Causes of Diabetic Dysregulation
This is a suggestive checkoff list when faced with an unregulated diabetic patient:

UTI
Dietary indiscretion/intolerance
Pancreatitis
Hyperthyroidism/hypothyroidism
Exogenous steroids (including topical eye meds)
Cushing's
Acromegaly
Owner compliance
Insulin quality issues
Antibodies to insulin
Underlying Neoplasia
Diffuse liver disease

For an additional charge, internal medicine consult can be utilized through Sonopath.com. You can select the internal medicine drop down at http://spa.sonopath.com/.

One of the world's top internists & SonoPath associate Dr. Remo Lobetti BVSc, MMedVet, PhD, DECVIM can evaluate your case through SonoPath. https://sonopath.com/resources/sonopath-services/internal-medicine-teleconsultation-services

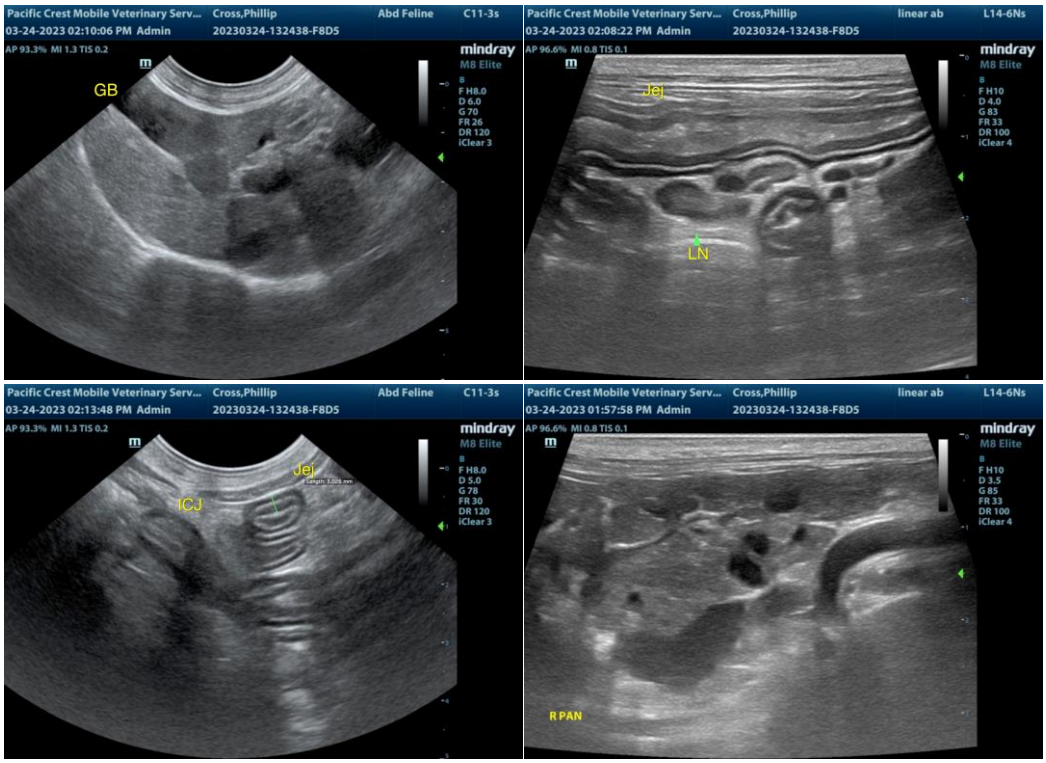

# SonoPath

*Clinical Sonography & Telecytology*

EDUCATIONAL TELECONSULTATION SERVICES™

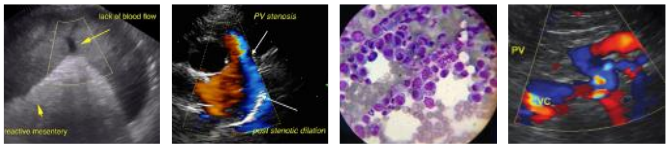


SonoPath.com™
1-800-838-4268 info@sonopath.com

**PATIENT**

Phillip Cross

**SPECIES**

Feline

**BREED**

DLH

**SEX**

MN

**AGE**

12 years

**WEIGHT**

5 kg

**INTERPRETED BY**

R. McKenzie Daniel, DVM, DABVP (Canine and Feline)

**IMAGING PERFORMED BY**

Dr. Callihan/Pacific Crest Mobile Veterinary Service

**HOSPITAL NAME**

Pacific Crest Mobile Veterinary Service

**REFERRING VET**

Dr Groff/Chuckanut Feline Center

**INVOICE**

16455

**DATE**

3/24/23

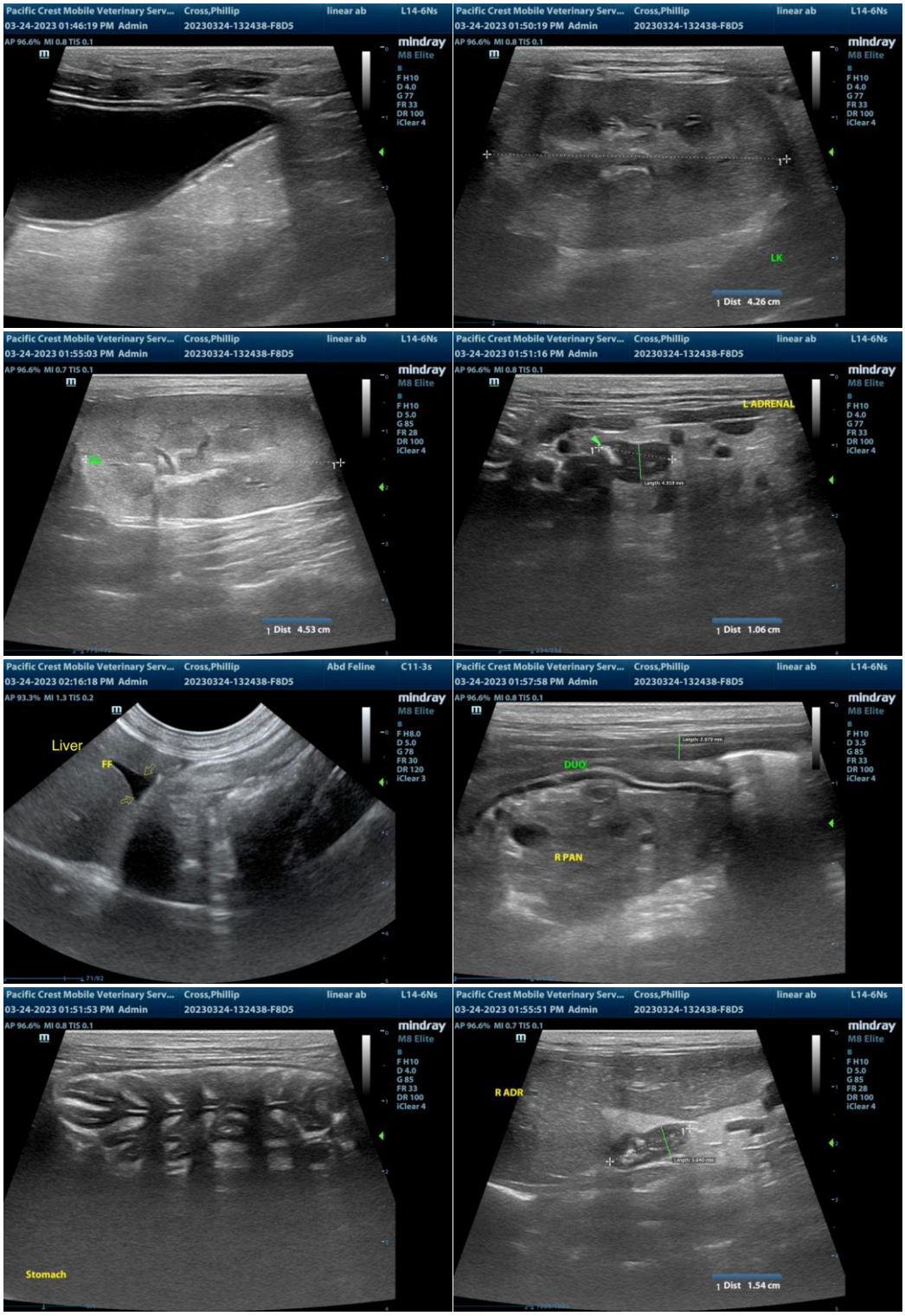


**The information and recommendations provided are based on the images presented by the referring veterinarian/sonographer. No evaluation can be communicated regarding pathology that was not visible in the image/video clips provided.**

SonoPath
Clinical Sonography & Telecytology
EDUCATIONAL TELECONSULTATION SERVICES™

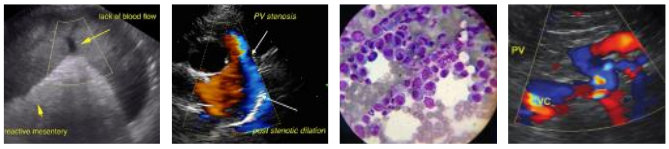


SonoPath.com™
1-800-838-4268 info@sonopath.com

**PATIENT**

Phillip Cross

**SPECIES**

Feline

**BREED**

DLH

**SEX**

MN

**AGE**

12 years

**WEIGHT**

5 kg

**INTERPRETED BY**

R. McKenzie Daniel, DVM, DABVP (Canine and Feline)

**IMAGING PERFORMED BY**

Dr. Callihan/Pacific Crest Mobile Veterinary Service

**HOSPITAL NAME**

Pacific Crest Mobile Veterinary Service

**REFERRING VET**

Dr Groff/Chuckanut Feline Center

**INVOICE**

16455

**DATE**

3/24/23

Thank you for this referral. If the clinical or image interpretation does not parallel your findings or if I can be of any further assistance please contact me.

**R. McKenzie Daniel, DVM, DABVP (Canine / Feline Practice)**
**info@SonoPath.com**