



PATIENT PRESENTING CLINICAL SIGNS

Shiloh Yoo History: P was coughing on and off for a few weeks, especially after becoming excited. Dr. says heart murmur worsened- heart seems enlarged, too. Normal daily habits (e/d/u/d). Dr. requests second opinion to evaluate heart activity.

SPECIES

Canine

ULTRASONOGRAPHIC EXAMINATION OF THE HEART

BREED

Maltese

SEX

Female

AGE

9 Years

WEIGHT

8.9 Pounds

CANINE CARDIAC PARAMETERS	MR VMAX (m/s)	TR VMAX (m/s)	LA/AO (Boon method)	LA/AO (Heart Base; Swe)	FS (%)	EF (%)	EPSS (cm)
NORMAL PARAMETER	4.5-5.5	<2.7	1.3	<1.6	28-40	40-100	<0.6
PATIENT	5.8	1.9	NM	2.0	47.6	82.5	0.25
CANINE CARDIAC PARAMETERS	HR (BPM)	AV VMAX (m/s)	PV MAX (m/s)	BODY WEIGHT (kg)	LA 2D short axis Base view (cm)	LVIDd Avg; 2D and m-mode short axis (cm)	LVIDs Avg; 2D and m-mode short axis (cm)
NORMAL PARAMETER	50-100	0.7-1.7	0.7-1.6	BELOW	BELOW	BELOW	BELOW
PATIENT	NM	1.1	1.3	--	3.1	2.7	--

INTERPRETED BY

R. McKenzie Daniel, DVM, DABVP (Canine and Feline)

IMAGING PERFORMED BY

Dr. Kim

HOSPITAL NAME

Ridgefield Park AH

REFERRING VET

Dr. Kim

INVOICE

14488

DATE

3/24/22

Cardiac Presentation

The echocardiogram for this patient presented moderately excessive **left atrial size** expressed both in the LA/AO and LA max measurements Chamber volumes and echogenicity were normal. The cranial and caudal **mitral** valve leaflets presented vegetative thickening consistent with endocardiosis. Doppler indicated moderate eccentric insufficiency. The **left ventricle** presented thicknesses with linear contour with mild increased left ventricular volume. The **myocardium** presented normal echogenicity without subjective evidence of significant fibrotic or ischemic disease. **Contractility** of the ventricular walls was adequate and in normal range for this patient evidenced by the fractional shortening measurement and subjective evaluation of the different regions of the myocardium. The **left ventricular outflow** tract demonstrated normal laminar flow and subjective structural integrity. The **right atrium** and auricle revealed normal size, structure and content. No evidence of masses was noted or chamber overload. **Tricuspid** valvular assessment demonstrated adequate linear morphology. The **right ventricle** was of normal size (1/3 diameter of LV), chordae structure, myocardial echogenicity and thickness. **Pulmonic** tract assessment revealed normal valve structure, laminar flow, and diameter (approx.1:1 pa/ao ratio). No visible **pericardial** or free pleura fluid was noted. No echographically detectable evidence of infiltrative disease was visible. The cranial **mediastinum and pericardial regions** were free of masses in the visible window.

ULTRASONOGRAPHIC FINDINGS

- Chronic mitral valve disease (ACVIM B-2)
- Mild TV insufficiency- not overtly consistent with clinical pulmonary hypertension



PATIENT

Shiloh Yoo

SPECIES

Canine

BREED

Maltese

SEX

Female

AGE

9 Years

WEIGHT

8.9 Pounds

INTERPRETED BY

R. McKenzie Daniel,
DVM, DABVP
(Canine and Feline)

**IMAGING
PERFORMED BY**

Dr. Kim

HOSPITAL NAME

Ridgefield Park AH

REFERRING VET

Dr. Kim

INVOICE

14488

DATE

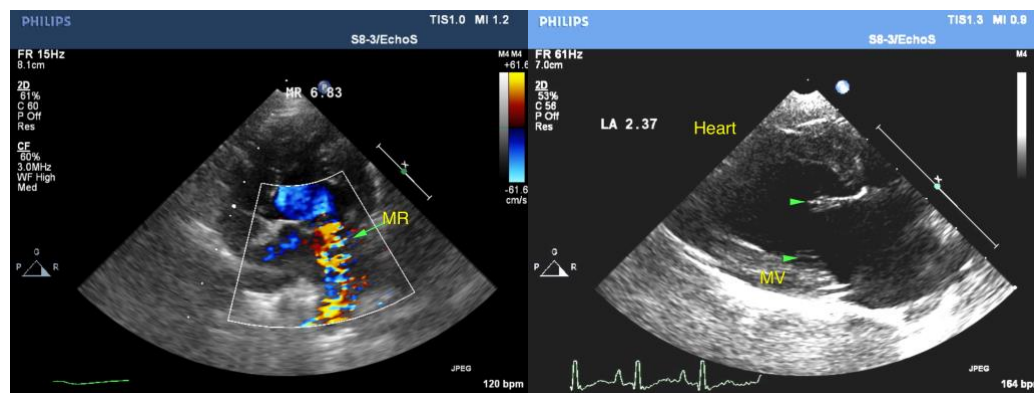
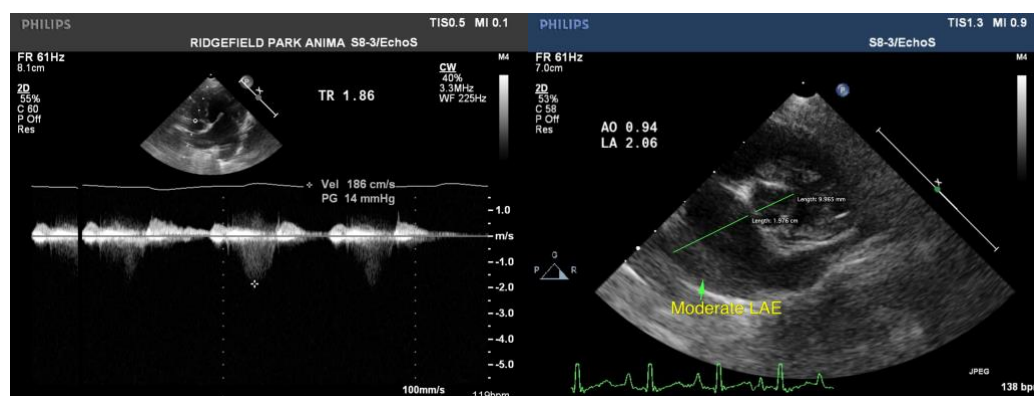
3/24/22

INTERPRETATION OF THE FINDINGS & FURTHER RECOMMENDATIONS

The cause of the murmur is consistent with chronic degenerative valvular changes with secondary eccentric mitral valve insufficiency. The moderate left atrial enlargement indicates that the risk of current and future complications going forward is elevated. No other clinical issues, such as LV systolic dysfunction or overt clinical pulmonary hypertension were present. The coughing in this patient may be multifactorial in origin, assuming no evidence of pulmonary edema on three-view chest radiographs. Some degree of mainstem bronchi irritation or compression, owing to LA enlargement, as well as primary lower airway component to the coughing may be possible.

Pimobendan at 0.3 mg/kg PO BID is warranted at this stage. As needed respiratory support, as well as hydrocodone, at appropriate dose, may prove beneficial. Baseline monitoring of resting respiration rate is recommended. Serial sonographic monitoring is required for further prognosis.

Recheck echocardiogram suggested in 6 months or sooner if clinical signs consistent with heart disease (i.e., exercise intolerance, increased resting respiration rate, syncope, etc.) arise.



The information and recommendations provided are based on the images presented by the referring veterinarian. No evaluation can be communicated regarding pathology that was not visible in the image/video clips provided.

Thank you for this referral. If the clinical or image interpretation does not parallel your findings or if I can be of any further assistance please contact me.

R. McKenzie Daniel, DVM, DABVP (Canine / Feline Practice)
info@SonoPath.com



PATIENT

Shiloh Yoo

SPECIES

Canine

BREED

Maltese

SEX

Female

AGE

9 Years

WEIGHT

8.9 Pounds

INTERPRETED BY

R. McKenzie Daniel,
DVM, DABVP
(Canine and Feline)

**IMAGING
PERFORMED BY**

Dr. Kim

HOSPITAL NAME

Ridgefield Park AH

REFERRING VET

Dr. Kim

INVOICE

14488

DATE

3/24/22