



PATIENT PRESENTING CLINICAL SIGNS

Abbey Coughlin History: 1 month duration PU/PD, palpable abdominal mass
Labs: elevated CK, decreased ALP

SPECIES ULTRASONOGRAPHIC EXAMINATION OF THE ABDOMEN

Canine **Urinary System**

BREED The urinary bladder, trigone, cystourethral junction, and visible pelvic urethra to a depth of 3.0 cm exhibited normal thickness and tone. Anechoic urine was present in the lumen with no uroliths or sediment. The ureteral papillae were normal. The ureters were not visible which is normal. No evidence of inflammatory or neoplastic changes were noted.

SEX The area of the iliac trifurcation was free of pathology, including no evidence of sublumbar or medial iliac lymphadenopathy.

Spayed Female Normal size and margination were present in the kidneys. A normal 1:3 cortex / medulla ratio was maintained. The medulla and cortices were uniform in texture with some increased echogenicity and loss of corticomedullary symmetry and definition expected for the age of the patient. No evidence of pelvic dilation was present. The left kidney measured 5.9 cm in length. A craniomedial cyst was present in the right kidney, measuring 1.6 cm in diameter. The right kidney measured 6.0 cm in length.

AGE

2008

Adrenal Glands

WEIGHT

24.8 kg

The bilateral adrenal glands were normal in size. Mild parenchyma heterogeneity and mild capsule asymmetry was present without suspicion for overt neoplasia. The left adrenal gland measured 2.4 cm in length x 0.68 cm width in the caudal pole. The right adrenal gland measured 2.5 cm in length x 0.79 cm width in the caudal pole.

INTERPRETED BY

R. McKenzie Daniel,
DVM, DABVP
(Canine and Feline)

Spleen

The spleen exhibited a finely textured and homogenous parenchyma which was hyperechoic to the liver and renal cortical parenchyma. The capsule was smooth and regular without apparent expansion. The splenic vasculature at the hilus was normal in volume with no evidence of congestion or thrombosis. Acute to chronic inflammatory, neoplastic, or benign parenchyma changes were not noted.

IMAGING PERFORMED BY

Rebekah Jakum, CVT
ARDMS/RVT

Liver

The liver was subjectively normal in size, structure, and contour. The liver parenchyma was mildly nonuniform and hypoechoic to the spleen with a moderate coarse echotexture and subjective mild to benign parenchymal remodeling. The hepatic and portal vasculature were normal in appearance without signs of congestion.

HOSPITAL NAME

Abby Road VH

The gallbladder was non-distended in size with thin walls and primarily anechoic luminal content. The cystic and common bile ducts were normal.

REFERRING VET

Dr. Gerenser

Gastrointestinal

INVOICE

The stomach presented intact wall layering with a normal wall layer ratio. Luminal gas and minor retained anechoic fluid was present in the stomach.

14469

The visualized small intestine exhibited intact wall layering and maintained 1:3 muscularis/mucosa ratio. No evidence of mechanical/metabolic ileus.

DATE

3/24/22



PATIENT Normal visible colon wall layers were present with apparent formed feces in lumen.

Abbey Coughlin

Pancreas

SPECIES

The pancreas was normal in size and contour with isoechoic to heterogeneous parenchyma compared to adjacent omentum. No signs of active inflammation or neoplasia.

Canine

Free Abdomen

BREED

A moderately sized to large asymmetrical nonhomogeneous to hypoechoic mass was present, occupying the majority of the mid abdomen. The mass measured approximately 10-11 cm in length x 6.0 cm in width, although potentially larger as the entire mass would not fit into a single viewing window. The mass was noted to directly efface yet not overtly originate from the craniomedial spleen as well as directly adjacent to mid abdominal intestinal loops. Subtle evidence of reactive mesentery around the mass was present. No overt evidence of free fluid.

Lab Mix

SEX

Other

Spayed Female

No overt pathology in the area of the uterine remnant.

AGE

ULTRASONOGRAPHIC FINDINGS

2008

- Unspecified to expansive, nonhomogeneous mid abdominal mass
- Age-related kidneys with right kidney cyst
- Mild hepatic parenchymal remodeling

WEIGHT

24.8 kg

INTERPRETATION OF THE FINDINGS & FURTHER RECOMMENDATIONS

INTERPRETED BY

Given the size and extent of the confirmed mid abdominal mass with direct effacement with multiple organs, definitive origin of the mass was not overtly evident. Neoplastic criteria is favored with nonneoplastic etiology possible yet thought less likely.

R. McKenzie Daniel,
DVM, DABVP
(Canine and Feline)

Assuming normal clotting status, ultrasound guided FNA of the mass for screening cytology is warranted for further definition. The mass did not appear to involve either the left or right kidney or adrenal glands. The mass did also not appear to originate from the spleen, although the mass was located in the area of the craniomedial spleen. Unspecified omental lymphatic or possible intestinal origin is considered most probable. CT is likely ideal for further assessment as well as assessment of possible surgical respectability if possible.

IMAGING PERFORMED BY

Rebekah Jakum, CVT
ARDMS/RVT

HOSPITAL NAME

Abby Road VH

REFERRING VET

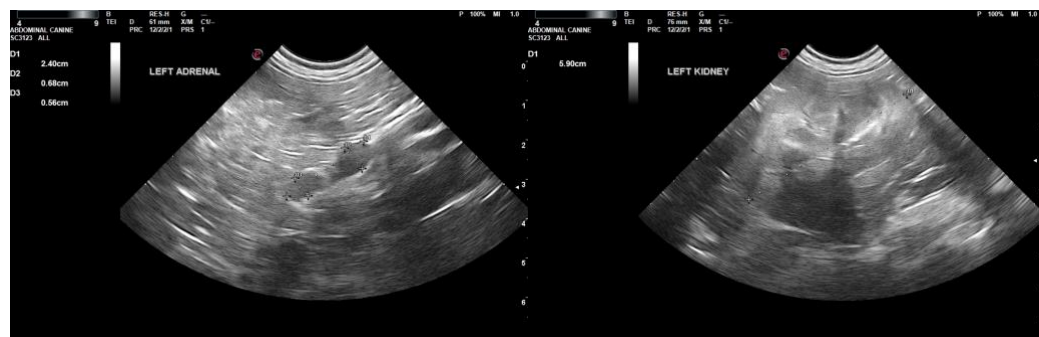Dr. Gerenser

INVOICE

14469

DATE

3/24/22





PATIENT

Abbey Coughlin

SPECIES

Canine

BREED

Lab Mix

SEX

Spayed Female

AGE

2008

WEIGHT

24.8 kg

INTERPRETED BY

R. McKenzie Daniel,
DVM, DABVP
(Canine and Feline)

IMAGING PERFORMED BY

Rebekah Jakum, CVT
ARDMS/RVT

HOSPITAL NAME

Abby Road VH

REFERRING VET

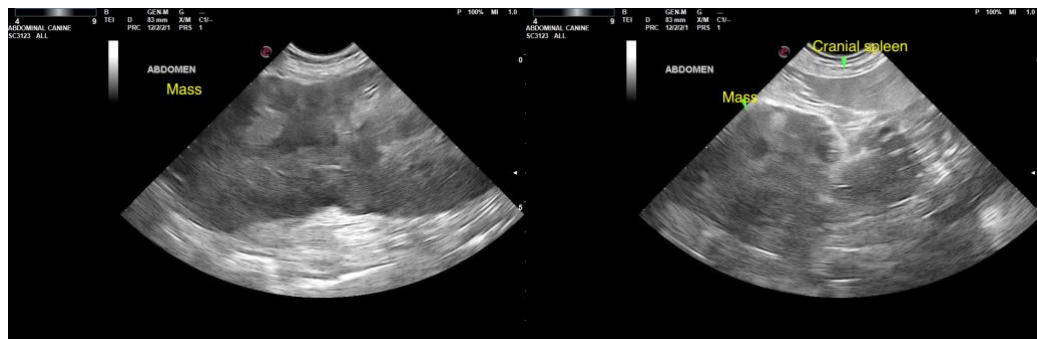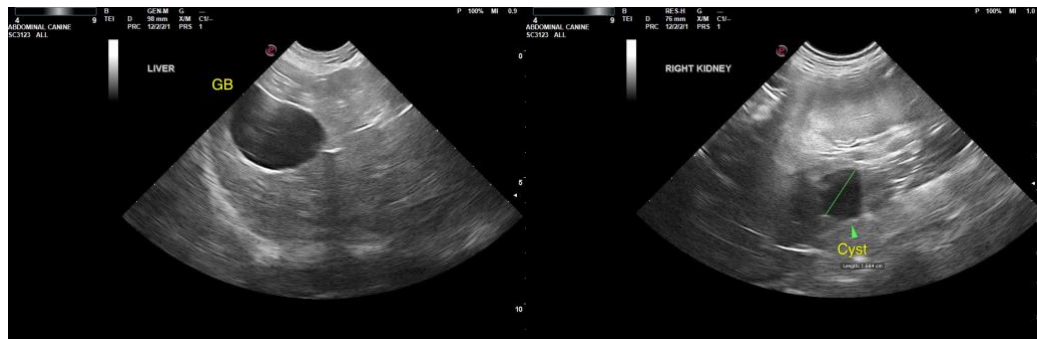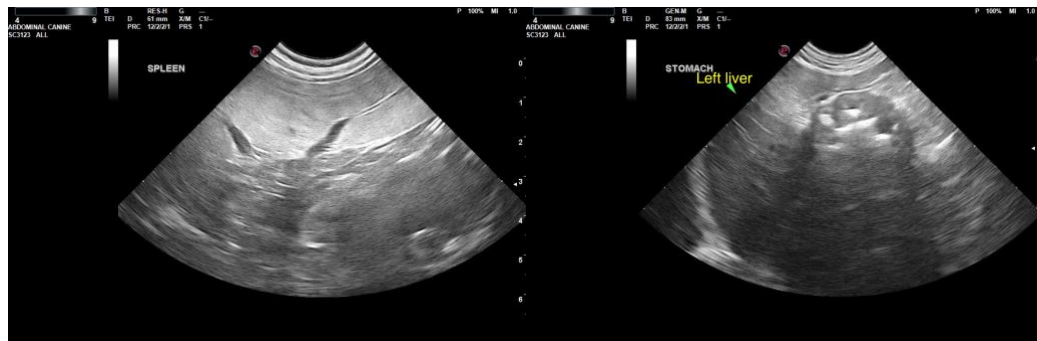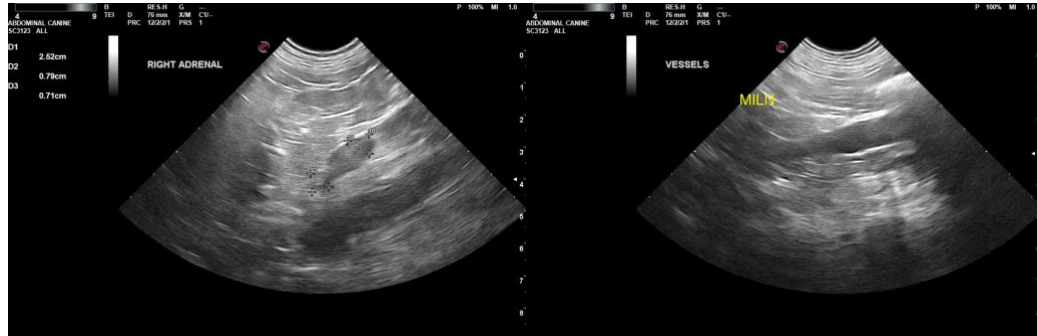Dr. Gerenser

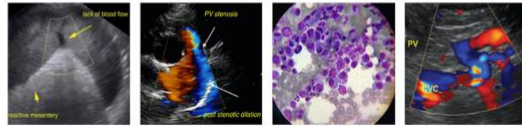
INVOICE

14469

DATE

3/24/22





PATIENT

Abbey Coughlin

SPECIES

Canine

BREED

Lab Mix

SEX

Spayed Female

AGE

2008

WEIGHT

24.8 kg

INTERPRETED BY

R. McKenzie Daniel,
DVM, DABVP
(Canine and Feline)

**IMAGING
PERFORMED BY**

Rebekah Jakum, CVT
ARDMS/RVT

HOSPITAL NAME

Abby Road VH

REFERRING VET

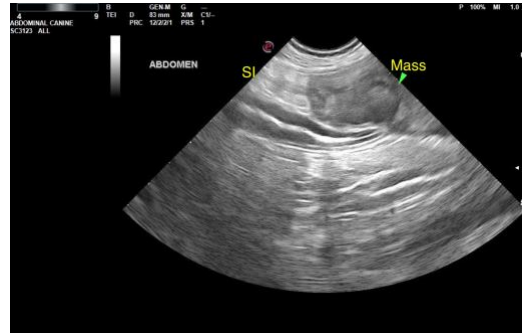Dr. Gerenser

INVOICE

14469

DATE

3/24/22



The information and recommendations provided are based on the images presented by the referring veterinarian. No evaluation can be communicated regarding pathology that was not visible in the image/video clips provided.

Thank you for this referral. If the clinical or image interpretation does not parallel your findings or if I can be of any further assistance please contact me.

R. McKenzie Daniel, DVM, DABVP (Canine / Feline Practice)
info@SonoPath.com