



PATIENT PRESENTING CLINICAL SIGNS

Bogie Wasilunas Found suspect anal sac apocrine gland adenocarcinoma on annual exam (confirmed on cytology). Met check before referral for surgery. Bloodwork being run day of AUS. Chest rads NSF. Obese.

SPECIES ULTRASONOGRAPHIC EXAMINATION OF THE ABDOMEN

Canine **Urinary System**

BREED The urinary bladder, trigone, cystourethral junction, and visible pelvic urethra exhibited normal thickness and tone. Anechoic urine was present in the lumen with no uroliths or sediment. The ureteral papillae were normal. The ureters were not visible which is normal. No evidence of inflammatory or neoplastic changes were noted.
Cockapoo

SEX Normal size and margination were present in the kidneys. A normal 1:3 cortex / medulla ratio was maintained. The medulla and cortices were uniform in texture with some increased echogenicity and moderate loss of corticomedullary symmetry and definition expected for the age of the patient. No evidence of pelvic dilation was present. The left kidney measured 6.4 cm in length. The right kidney measured 6.5 cm in length.
MN

AGE The area of the aortic trifurcation was free of pathology.
11yr

The area of the iliac trifurcation was free of pathology including no evidence of medial, iliac or sublumbar lymphadenopathy.

WEIGHT The area of the residual prostate appeared normal and free of pathology.
51lb

Adrenal Glands

INTERPRETED BY The left adrenal gland was uniform in size and contour with a uniformly hypoechoic parenchyma. The left adrenal gland measured 0.63 cm width at the caudal pole and 0.61 cm width at the cranial pole. The right adrenal gland was uniform in size and contour with a uniformly hypoechoic parenchyma. The right adrenal gland measured 0.51 cm width at the caudal pole and 0.42 cm width at the cranial pole.
R. McKenzie Daniel, DVM, DABVP (Canine and Feline)

Spleen

IMAGING PERFORMED BY The spleen exhibited normal size and areas of minor capsule asymmetry with subtle generalized parenchymal heterogeneity. Intermittent discrete hypoechoic splenic nodules were present, an example measuring 0.55 cm in diameter. The splenic vasculature at the hilus was normal in volume with no evidence of congestion or thrombosis. No splenic masses.
Pamela Harrigan, RDCS

Liver/Gallbladder

HOSPITAL NAME The liver exhibited mild to moderate enlargement, symmetrical capsule contour and uniform mild increased parenchymal echogenicity with mild coarse echotexture. No hepatic masses or nodules. The hepatic and portal vasculature were normal in appearance without signs of congestion. The gallbladder was non-distended in size with thin walls and primarily anechoic luminal content and mild non-dependent echogenic debris. No evidence of gallbladder or peripheral gallbladder inflammation was present. The cystic and common bile ducts were normal.
Norfolk County Veterinary Service

REFERRING VET

Dr. McCabe

INVOICE

13277ag

DATE

03/23/2023



PATIENT

Bogie Wasilunas

The small intestine presented intact wall layering with 1:3 muscularis/mucosa ratio. Segmental non-specific hyperechoic jejunal mucosal speckling was present. The lumen of the small intestine with no signs of ileus, obstruction or foreign material.

SPECIES

Canine

Normal visible colon wall layers were present with apparent formed feces in lumen.

Pancreas

The pancreas was normal in size and contour with isoechoic to heterogeneous parenchyma compared to adjacent omentum. No signs of active inflammation or neoplasia.

BREED

Cockapoo

Free Abdomen

No omental masses, overt lymphadenopathy or peritoneal effusion was present.

SEX

MN

ULTRASONOGRAPHIC FINDINGS

- Hepatomegaly exhibiting non-uniform increased parenchymal echogenicity.
- Gallbladder debris (non-mucocele)
- Age related pancreatic remodeling.
- Bilateral chronic renal changes.
- Discrete splenic nodules-subjectively benign.
- Segmental non-specific jejunal mucosal speckling.

AGE

11yr

WEIGHT

51lb

INTERPRETATION OF THE FINDINGS & FURTHER RECOMMENDATIONS

Largely expected age related abdominal changes without evidence of significant visceral pathology. No overt evidence of intra-abdominal or retroperitoneal neoplastic/metastatic criteria. Correlation with pending lab work is recommended.

INTERPRETED BY

R. McKenzie Daniel, DVM,
DABVP (Canine and Feline)

Assuming normal clotting status, a hepatic FNA for screening cytology could be considered along with hepatosupportive medications if evidence of cholestasis or hepatic enzyme elevation.

IMAGING PERFORMED BY

Pamela Harrigan, RDCS

The discrete hypoechoic splenic nodules tend to trend benign and are most suggestive of probable subtle lymphoid hyperplasia or hematopoiesis. Sonographic monitoring of the spleen for evidence of progressive parenchymal changes as well as general sonographic abdominal monitoring based on oncology recommendations given patient history is recommended.

HOSPITAL NAME

Norfolk County
Veterinary Service

REFERRING VET

Dr. McCabe

INVOICE

13277ag

DATE

03/23/2023



PATIENT

Bogie Wasilunas

SPECIES

Canine

BREED

Cockapoo

SEX

MN

AGE

11yr

WEIGHT

51lb

INTERPRETED BY

R. McKenzie Daniel, DVM,
 DABVP (Canine and Feline)

IMAGING PERFORMED BY

Pamela Harrigan, RDCS

HOSPITAL NAME

Norfolk County
 Veterinary Service

REFERRING VET

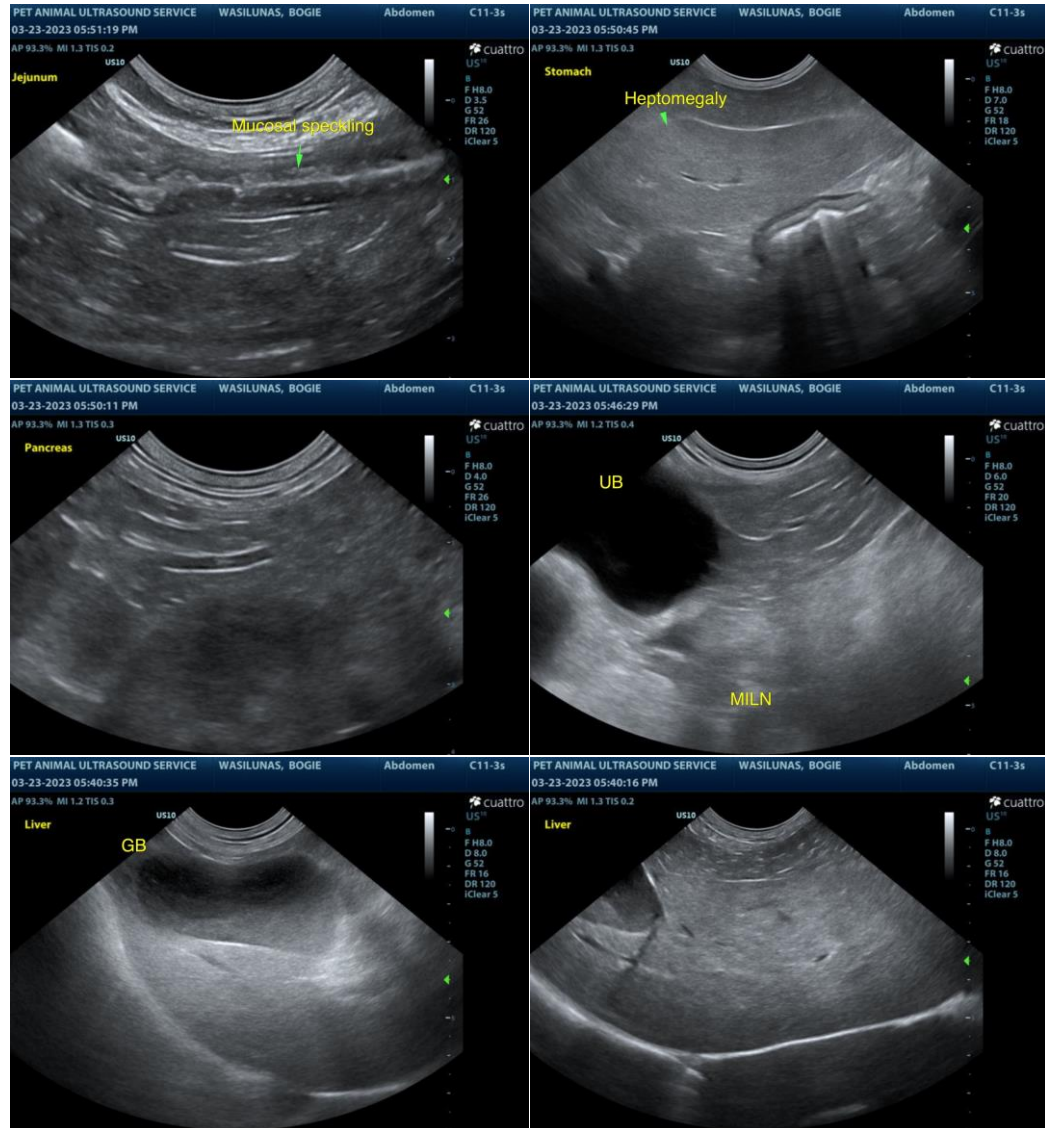
Dr. McCabe

INVOICE

13277ag

DATE

03/23/2023





PATIENT

Bogie Wasilunas

SPECIES

Canine

BREED

Cockapoo

SEX

MN

AGE

11yr

WEIGHT

51lb

INTERPRETED BY

R. McKenzie Daniel, DVM,
 DABVP (Canine and Feline)

IMAGING PERFORMED BY

Pamela Harrigan, RDCS

HOSPITAL NAME

Norfolk County
 Veterinary Service

REFERRING VET

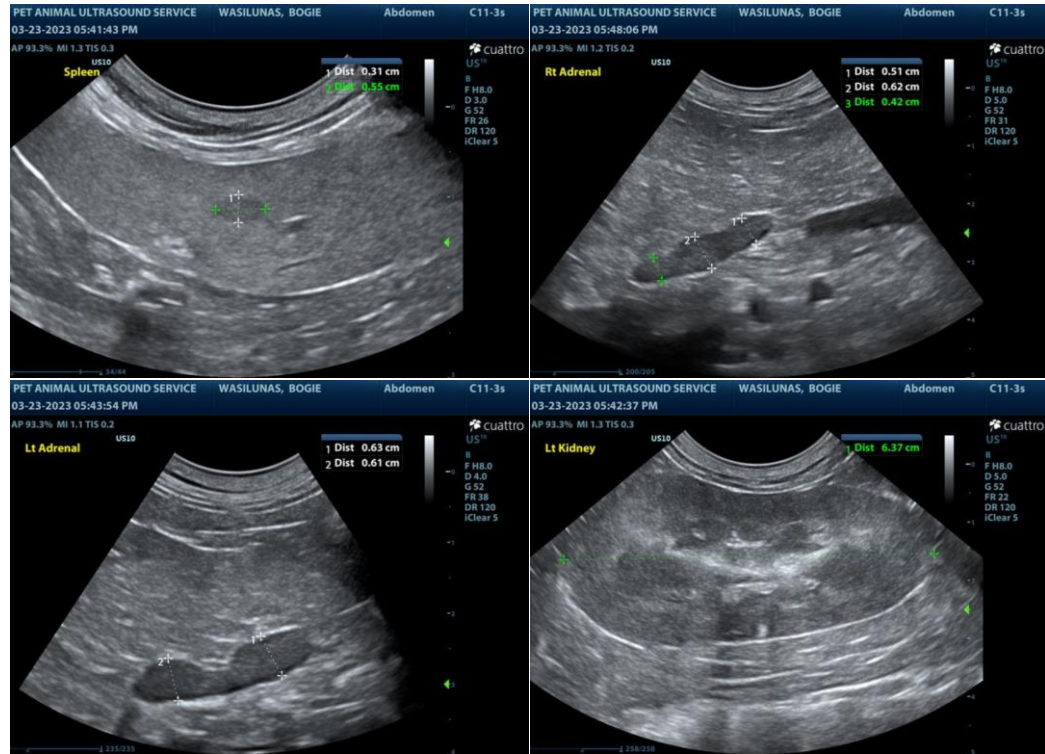
Dr. McCabe

INVOICE

13277ag

DATE

03/23/2023



The information and recommendations provided are based on the images presented by the referring veterinarian/sonographer. No evaluation can be communicated regarding pathology that was not visible in the image/video clips provided.

Thank you for this referral. If the clinical or image interpretation does not parallel your findings or if I can be of any further assistance please contact me.

R. McKenzie Daniel, DVM, DABVP (Canine / Feline Practice)

info@SonoPath.com