



## PATIENT

Isabella Ward

## SPECIES

Feline

## BREED

DLH

## SEX

FS

## AGE

10 years

## WEIGHT

N/A

## INTERPRETED BY

R. McKenzie Daniel,  
DVM, DABVP  
(Canine and Feline)

## IMAGING PERFORMED BY

Diane McFadden

## HOSPITAL NAME

Lake Hopatcong AH

## REFERRING VET

Dr. Batta

## INVOICE

16420

## DATE

3/22/23

## PRESENTING CLINICAL SIGNS

wheezing

## ULTRASONOGRAPHIC EXAMINATION OF THE HEART

FELINE CARDIAC PARAMETERS	BODY WEIGHT (kg)	HR (BPM)	IVSd (cm)	LVIDd (cm)	LVWd (cm)	FS (%)	EF (%)
NORMAL PARAMETER	-----	150-240	0.3-0.6	1.0-2.1	0.25-0.6	35-67	80-100
PATIENT		214	0.30	1.69	0.37	61	92
FELINE CARDIAC PARAMETERS	LA/AO (Boon)	LA/AO HEART BASE (Sisson)	LA 2D 4-chamber long axis AS to FW (Sisson) (cm)	LVOT VEL. (m/s)	RVOT VEL. (m/s)	IVRT (m/)	
NORMAL PARAMETER	<1.5	0.88-1.79	0.7-1.7	<1.6	<1.3	40-60	
PATIENT		1.0	1.2	1.0	0.75	NM	
Adapted from June Boon, Veterinary Echocardiography, 1998							
Sisson D et al. JVIM 1991; 5: 232, Jacobs et al. Am J Vet Res 1985; 46:1705							

## Cardiac Presentation

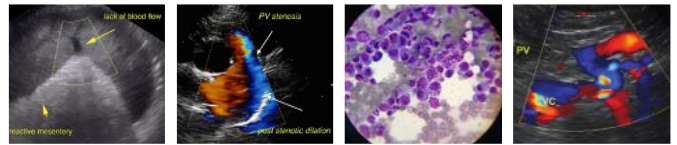
The echocardiogram in this patient demonstrated normal **left atrial** size based on 3 separate LA measurements. The cranial and caudal **mitral** valve leaflets presented normal linear structure and kinetics. The **left ventricle** presented normal thicknesses with linear contour and was not dilated nor restricted. The **myocardium** presented normal echogenicity without subjective evidence of significant fibrotic or ischemic disease. **Contractility** of the ventricular walls was adequate and in normal range for this patient evidenced by the fractional shortening measurement and subjective evaluation of the different regions and angles of the myocardium. The **left ventricular outflow** tract demonstrated normal laminar flow and subjective structural integrity. The **right atrium** and auricle revealed normal size, structure and content. No evidence of masses was noted or chamber overload. **Tricuspid** valvular assessment demonstrated adequate linear morphology and kinetics. The **right ventricle** was of normal size (1/3 diameter of LV), chordae structure, myocardial echogenicity and thickness. **Pulmonic** tract assessment revealed normal valve structure, laminar flow, and diameter (approx. 1:1 pa/ao ratio). No visible **pericardial** or free pleura fluid was noted or extra cardiac pathology in the visible planes. The cranial **mediastinum and pericardial regions** were free of masses in the visible window.

## ULTRASONOGRAPHIC FINDINGS

- Normal echocardiogram

## INTERPRETATION OF THE FINDINGS & FURTHER RECOMMENDATIONS

No evidence of structural or functional cardiomyopathy including no clinical issues such as left or right heart chamber enlargement, LV systolic dysfunction, HCM criteria, or evidence of pulmonary



**PATIENT**

Isabella Ward

hypertension, that would indicate a cardiogenic component to the patient's respiratory abnormalities. The normal cardiac presentation is most suggestive of suspected primary upper or lower airway disease as a primary contributing factor. No overt evidence of pericardial masses or evidence of pleural effusion.

**SPECIES**

Feline

There is no indication for cardiac medications. A radiology consult regarding three-view chest radiographs and as-needed respiratory therapy may be considered.

**BREED**

DLH

**SEX**

FS

**AGE**

10 years

**WEIGHT**

N/A

**INTERPRETED BY**

R. McKenzie Daniel, DVM, DABVP (Canine and Feline)

**IMAGING PERFORMED BY**

Diane McFadden

**HOSPITAL NAME**

Lake Hopatcong AH

**REFERRING VET**

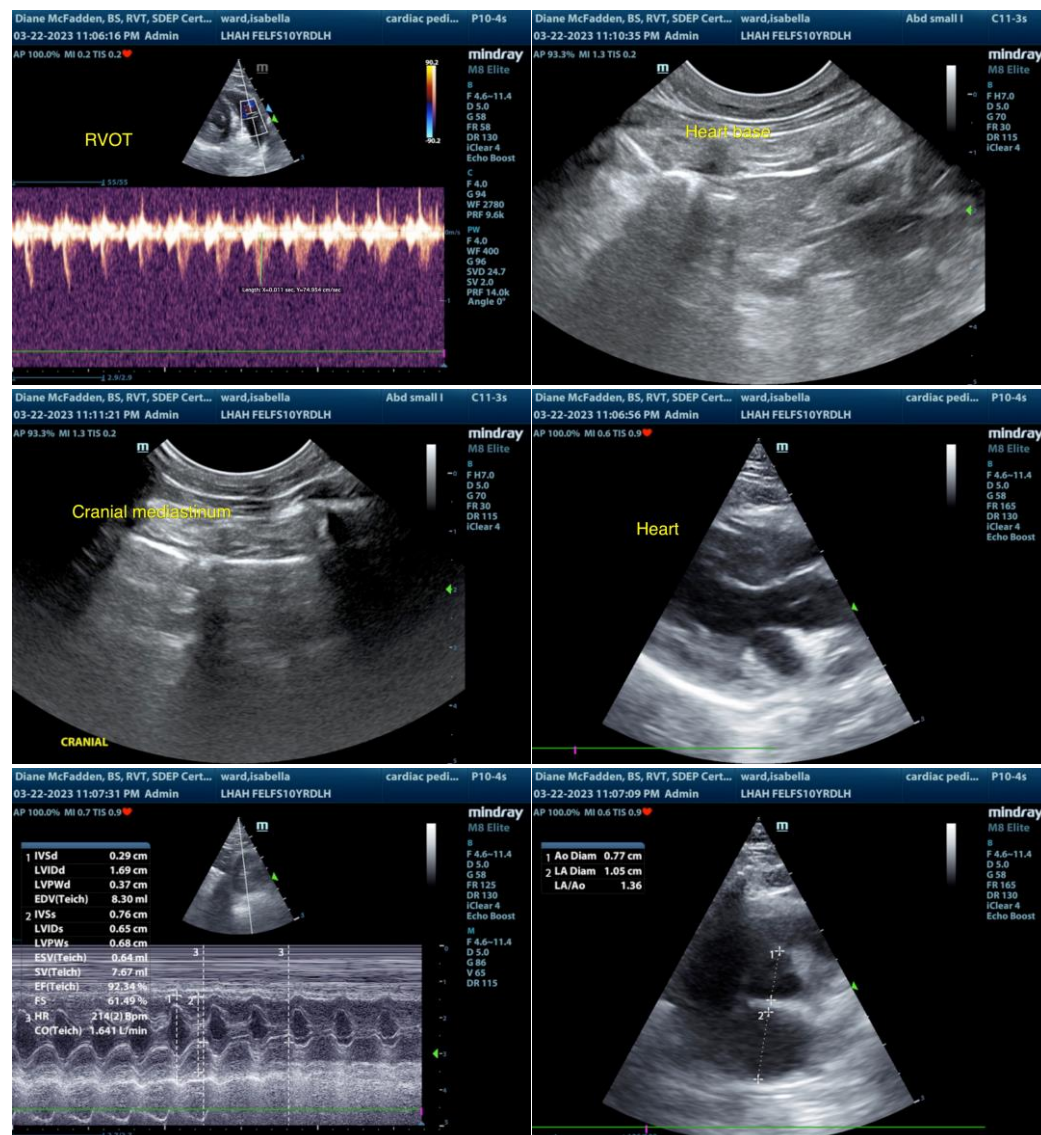
Dr. Batta

**INVOICE**

16420

**DATE**

3/22/23



The information and recommendations provided are based on the images presented by the referring veterinarian/sonographer. No evaluation can be communicated regarding pathology that was not visible in the image/video clips provided.

Thank you for this referral. If the clinical or image interpretation does not parallel your findings or if I can be of any further assistance please contact me.



**PATIENT**

Isabella Ward

**R. McKenzie Daniel, DVM, DABVP (Canine / Feline Practice)**  
**info@SonoPath.com**

**SPECIES**

Feline

**BREED**

DLH

**SEX**

FS

**AGE**

10 years

**WEIGHT**

N/A

**INTERPRETED BY**

R. McKenzie Daniel,  
DVM, DABVP  
(Canine and Feline)

**IMAGING  
PERFORMED BY**

Diane McFadden

**HOSPITAL NAME**

Lake Hopatcong AH

**REFERRING VET**

Dr. Batta

**INVOICE**

16420

**DATE**

3/22/23