

PATIENT

Sophie Stiegler

SPECIES

Feline

BREED

DMH

SEX

FI

AGE

1.5 years

WEIGHT

8.2 lbs.

INTERPRETED BY

R. McKenzie Daniel,
DVM, DABVP
(Canine and Feline)

IMAGING PERFORMED BY

Sara Hansen

HOSPITAL NAME
Pawsitive Wellness
VC

REFERRING VET

Dr. Hardy

INVOICE

13528

DATE

3/22/22

PRESENTING CLINICAL SIGNS

large uterus/tubes palpated in abdomen-sensitive. Enlarged nipples. Recently diagnosed with Calici virus. O unable of possible pregnancy date-could be 4-7 weeks ago from today

ULTRASONOGRAPHIC EXAMINATION OF THE ABDOMEN

Urinary System

The urinary bladder, trigone, cystourethral junction, and visible pelvic urethra to a depth of 2.0 cm exhibited normal thickness and tone. Anechoic urine was present in the lumen with no uroliths or sediment. The ureteral papillae were normal. The ureters were not visible which is normal. No evidence of inflammatory or neoplastic changes was noted.

Sonographic assessment of the uterus revealed suspect 3 viable fetuses exhibiting subjective normal heart rates. Emerging skull to skeletal mineralization was present. The uterus was overtly normal for pregnancy.

Normal size and margination were present in the kidneys. A normal 1:3 cortex / medulla ratio and normal corticomedullary definition were maintained. The echogenicity of the cortex was similar to or slightly less than normal liver parenchyma while the medulla echogenicity was hypoechoic to the cortex with no evidence of pelvic dilation. The left kidney measured 3.5 cm in length. The right kidney measured 3.9 cm in length.

Adrenal Glands

The left adrenal gland was uniform in size and contour with a uniformly hypoechoic parenchyma. The left adrenal gland measured 0.44 cm width. The right adrenal gland was uniform in size and contour with a uniformly hypoechoic parenchyma. The right adrenal gland measured 0.51 cm width.

Spleen

The spleen exhibited a finely textured and homogenous parenchyma which was hyperechoic to the liver and renal cortical parenchyma. The capsule was smooth and regular without apparent expansion. The splenic vasculature at the hilus was normal in volume with no evidence of congestion or thrombosis. Acute to chronic inflammatory, neoplastic, or benign parenchyma changes were not noted.

Liver/ Gallbladder

The liver was subjectively normal in size, structure, and contour. The liver parenchyma was uniform and hypoechoic to the spleen with a mild coarse echotexture. The hepatic and portal vasculature were normal in appearance without signs of congestion. The gallbladder was non-distended in size with thin walls and primarily anechoic luminal content. The cystic and common bile ducts were normal.



PATIENT

Sophie Stiegler

SPECIES

Feline

BREED

DMH

SEX

FI

AGE

1.5 years

WEIGHT

8.2 lbs.

INTERPRETED BY

R. McKenzie Daniel,
DVM, DABVP
(Canine and Feline)

IMAGING PERFORMED BY

Sara Hansen

HOSPITAL NAME
Pawsitive Wellness
VC

REFERRING VET

Dr. Hardy

INVOICE

13528

DATE

3/22/22

Gastrointestinal

The stomach presented intact wall layering with a normal wall layer ratio. The lumen of the stomach contained nonshadowing ingesta / chyme. This is likely consistent with post prandial presentation and incidental.

The small intestine presented intact wall layering with 1:3 muscularis/mucosa ratio. The lumen of the small intestine was empty with no signs of ileus, obstruction, or foreign material.

Normal visible colon wall layers were present with apparent formed feces in lumen.

Pancreas

The parenchyma of the left limb, body, and right limb of the pancreas presented isoechoic to the adjacent omental fat. A normal curvilinear capsule contour of the pancreas was present. The visible pancreatic duct was normal. No signs of active inflammation or neoplastic disease were evident.

Free Abdomen

No overt lymphadenopathy or peritoneal effusion was present.

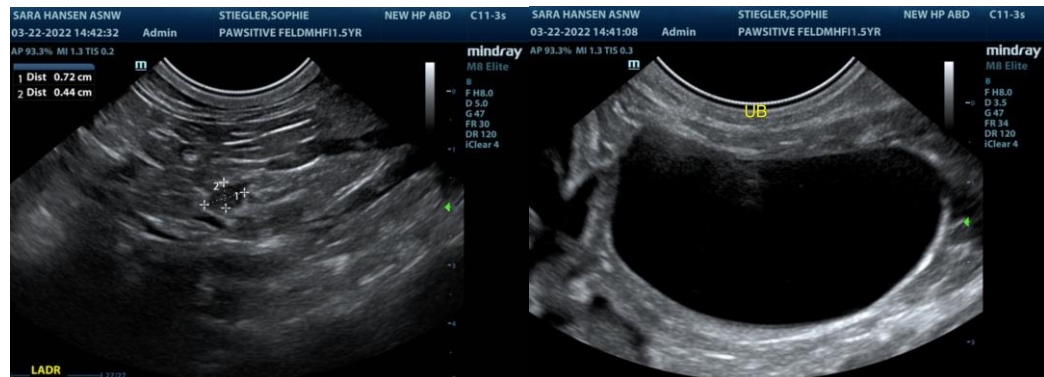
ULTRASONOGRAPHIC FINDINGS

Primary Findings

- Confirmed pregnancy - probable 3 viable fetuses
- Otherwise sonographically unremarkable abdomen

INTERPRETATION OF THE FINDINGS & FURTHER RECOMMENDATIONS

An accurate gestation age was unable to be determined yet evidence of emerging skeletal mineralization was present. Correlation with abdominal radiographs and potential reproductive consultation is recommended.





PATIENT

Sophie Stiegler

SPECIES

Feline

BREED

DMH

SEX

FI

AGE

1.5 years

WEIGHT

8.2 lbs.

INTERPRETED BY

R. McKenzie Daniel,
DVM, DABVP
(Canine and Feline)

IMAGING PERFORMED BY

Sara Hansen

HOSPITAL NAME

Pawsitive Wellness
VC

REFERRING VET

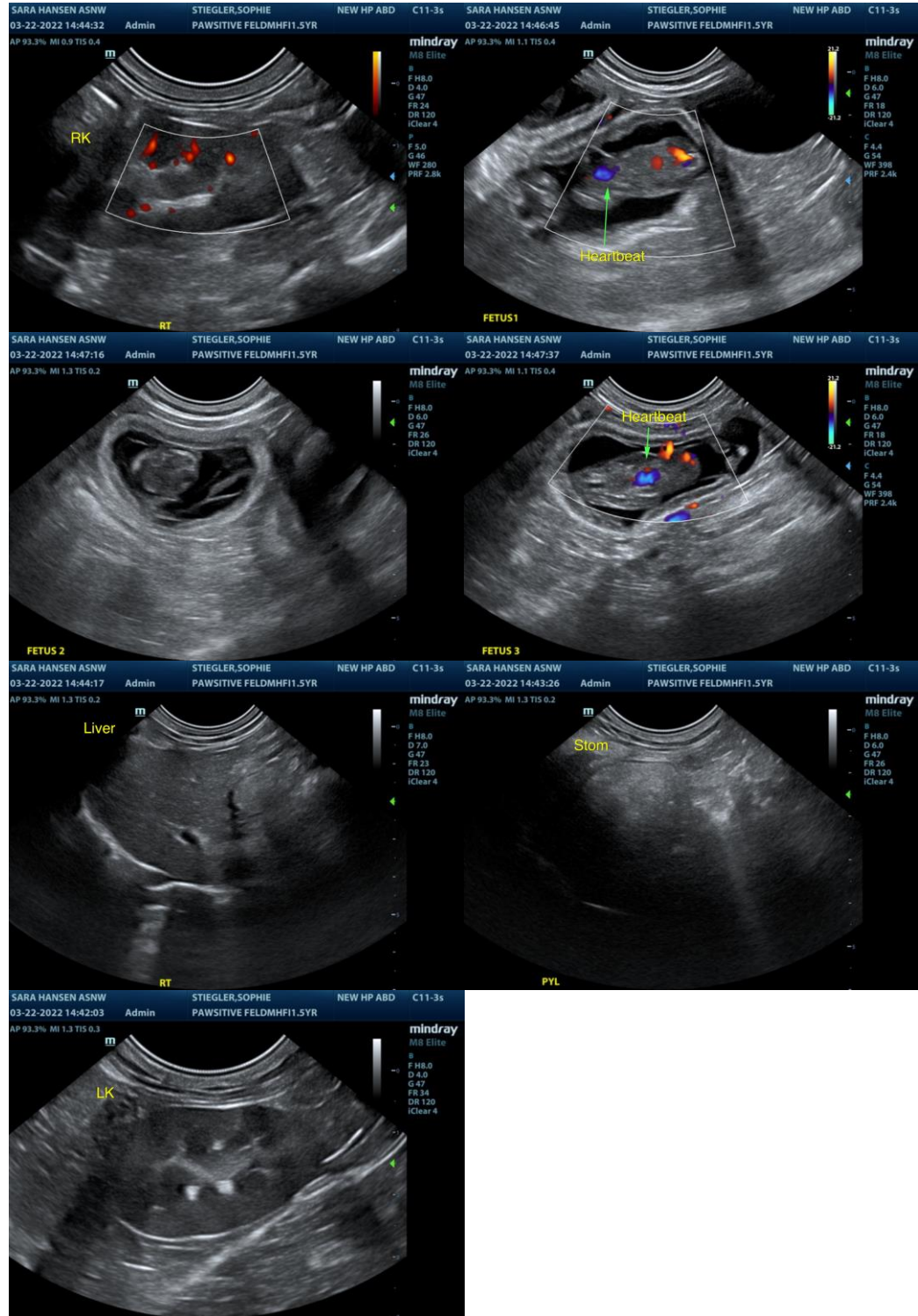
Dr. Hardy

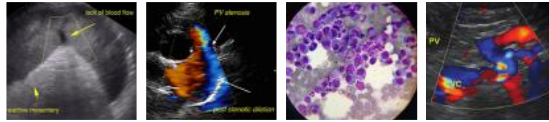
INVOICE

13528

DATE

3/22/22





PATIENT

Sophie Stiegler

SPECIES

Feline

BREED

DMH

SEX

FI

AGE

1.5 years

WEIGHT

8.2 lbs.

INTERPRETED BY

R. McKenzie Daniel,
DVM, DABVP
(Canine and Feline)

IMAGING PERFORMED BY

Sara Hansen

HOSPITAL NAME

Pawsitive Wellness
VC

REFERRING VET

Dr. Hardy

INVOICE

13528

DATE

3/22/22

The information and recommendations provided are based on the images presented by the referring veterinarian/sonographer. No evaluation can be communicated regarding pathology that was not visible in the image/video clips provided.

Thank you for this referral. If the clinical or image interpretation does not parallel your findings or if I can be of any further assistance please contact me.

R. McKenzie Daniel, DVM, DABVP (Canine / Feline Practice)
info@SonoPath.com