



PATIENT PRESENTING CLINICAL SIGNS

Danner Gilbert 2/6 murmur

ULTRASONOGRAPHIC EXAMINATION OF THE HEART

SPECIES

Canine

BREED

German SH Pointer

SEX

MN

AGE

2015

WEIGHT

65

CANINE	MR	TR	LA/AO	LA/AO	FS	EF	EPSS
CARDIAC PARAMETERS	VMAX (m/s)	VMAX (m/s)	(Boon method)	(Heart Base; Swe)	(%)	(%)	(cm)
NORMAL PARAMETER	4.5-5.5	<2.7	1.3	<1.3	28-40	40-100	<0.6
PATIENT				1.36	35	70	0.4
CANINE	HR	AV	PV	BODY WEIGHT	LA	LVIDd	LVIDs
CARDIAC PARAMETERS	(BPM)	VMAX (m/s)	MAX (m/s)	(kg)	2D short axis Base view (cm)	Avg; 2D and m-mode short axis (cm)	Avg; 2D and m-mode short axis (cm)
NORMAL PARAMETER	50-100	0.7-1.7	0.7-1.6				
PATIENT	103	1.9	1.6		4.0	4.3	

INTERPRETED BY

R. McKenzie Daniel,
DVM, DABVP
(Canine and Feline)

IMAGING PERFORMED BY

Rebekah Jakum, CVT
ARDMS/RVT

HOSPITAL NAME

New Britain VC

REFERRING VET

Dr. Bandekar

INVOICE

16411

DATE

3/21/23

Cardiac Presentation

The echocardiogram in this patient demonstrated normal **left atrial** size based on 3 separate methods of LA evaluation. The cranial and caudal **mitral** valve leaflets presented normal linear structure, extension in systole, and union in diastole with normal kinesis. Mild centralized MR was present on Doppler. The **left ventricle** presented normal thicknesses with linear contour and was not dilated nor restricted. The **myocardium** presented normal echogenicity without subjective evidence of significant fibrotic or ischemic disease. **Contractility** of the ventricular walls was adequate and in normal range for this patient evidenced by the fractional shortening measurement and subjective evaluation of the different regions of the myocardium. The **left ventricular outflow** tract demonstrated normal laminar flow and subjective structural integrity. Normal measured LVOT Velocity was noted. The **right atrium** and auricle revealed normal size, structure and content. No evidence of masses was noted. **Tricuspid** valvular assessment demonstrated adequate linear morphology and kinesis. No overt TR was noted on Doppler. The **right ventricle** was of normal size (1/3 diameter of LV), chordae structure, myocardial echogenicity and thickness. **Pulmonary outflow** tract assessment revealed normal valve structure, laminar flow, and diameter (approx.1:1 pa/ao ratio). Normal measured RVOT velocity was present. No visible **pericardial** or free pleura fluid was noted. The cranial **mediastinum and pericardial and extra-cardiac regions** were free of masses in the visible window.

ULTRASONOGRAPHIC FINDINGS

- Normal cardiac structure / function
- Mild centralized MR



PATIENT

Danner Gilbert

SPECIES

Canine

BREED

German SH Pointer

SEX

MN

AGE

2015

WEIGHT

65

INTERPRETED BY

R. McKenzie Daniel,
DVM, DABVP
(Canine and Feline)

IMAGING PERFORMED BY

Rebekah Jakum, CVT
ARDMS/RVT

HOSPITAL NAME

New Britain VC

REFERRING VET

Dr. Bandekar

INVOICE

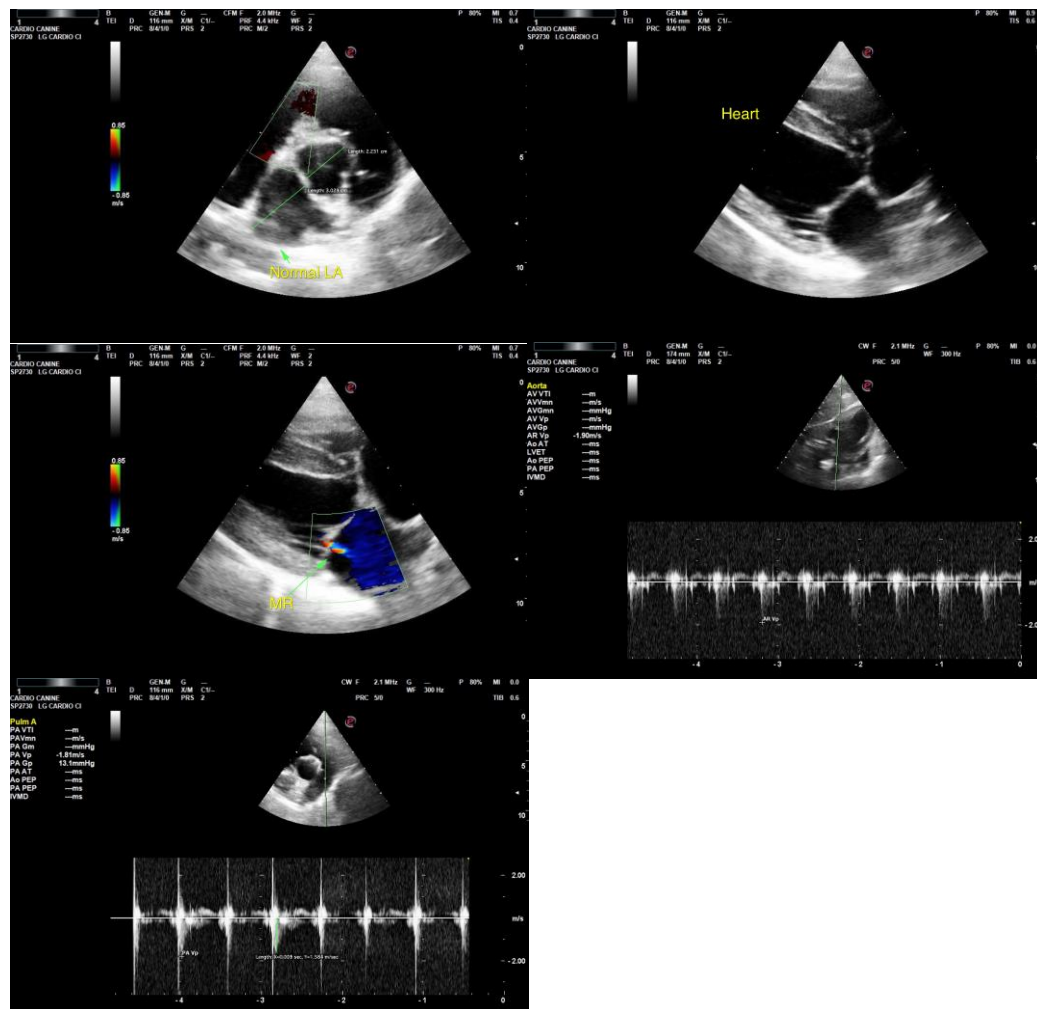
16411

DATE

3/21/23

INTERPRETATION OF THE FINDINGS & FURTHER RECOMMENDATIONS

Overtly normal cardiac structure and function are present with the low-grade murmur suspected to be secondary to mild centralized MR. No evidence of clinical issues such as DCM criteria, LV systolic dysfunction, or clinical pulmonary hypertension was noted. The hemodynamic effects of the mild MR are low, indicated by a lack of left atrium or generalized left heart chamber enlargement. There is no indication for cardiac medications. Conservative monitoring of the murmur at this stage would be appropriate. Recheck echocardiogram is suggested in 6-8 months, sooner if murmur intensity increases or if clinical signs consistent with heart disease arise.



The information and recommendations provided are based on the images presented by the referring veterinarian/sonographer. No evaluation can be communicated regarding pathology that was not visible in the image/video clips provided.

Thank you for this referral. If the clinical or image interpretation does not parallel your findings or if I can be of any further assistance, please contact me.

R. McKenzie Daniel, DVM, DABVP (Canine/Feline Practice)

mac.daniel@sonopath.com