



## PATIENT

Tank McGinnis

## SPECIES

Canine

## BREED

German Shep/Chow

## SEX

MN

## AGE

12yr

## WEIGHT

42.2lb

## INTERPRETED BY

R. McKenzie Daniel,  
DVM, DABVP  
(Canine and Feline)

## IMAGING PERFORMED BY

Meghan Myers VMD

## HOSPITAL NAME

Hershire Animal  
Hospital

## REFERRING VET

Dana Walck DVM

## INVOICE

24081

## DATE

03/02/2026

## PRESENTING CLINICAL SIGNS

chronic history of stranguria, dribbling urine, hematuria- was treated by rdvm for UTI- no improvement- referred for ultrasound. Is already on carprofen for arthritis.

## ULTRASONOGRAPHIC EXAMINATION OF THE ABDOMEN

### Urinary System

The urinary bladder, trigone, cystourethral junction, and visible pelvic urethra exhibited normal thickness and tone. Anechoic urine was present in the lumen with dependent lumen accumulated mineral to small calculi. The ureteral papillae were normal. The ureters were not visible which is normal. No evidence of inflammatory or neoplastic changes was noted.

Normal size and margination were present in the kidneys. A normal 1:3 cortex / medulla ratio was maintained. The medulla and cortices were uniform in texture with some increased echogenicity and loss of corticomedullary symmetry and definition expected for the age of the patient. No evidence of pelvic dilation was present. The left kidney measured 5.4 cm in length. The right kidney measured 5.4 cm in length. Non-obstructive medullary renoliths were present.

The area of the iliac trifurcation was free of pathology including no evidence of medial iliac or sublumbar lymphadenopathy or masses.

The prostate was enlarged in size. The prostatic parenchyma was primarily hypoechoic to heterogeneous with areas of parenchyma mineralization. The margins of the gland were indistinct and difficult to differentiate from the surrounding tissue. The prostate measured 3.6 cm in diameter. Thickened concurrent mineralized periprostatic urethra. No obvious obstruction to urine outflow given non-distended urinary bladder.

### Adrenal Glands

A well-defined, mildly hyperechoic nodule was present in the mid left adrenal gland with mild associated symmetrical capsule expansion. The nodule did not exhibit signs of mineralization or vascular invasion. The nodule measured 0.87 cm x 0.68 cm. The left adrenal caudal pole was normal in size measuring 0.74 cm in width.

The right adrenal gland was enlarged in size with symmetrical contour and mild non-homogenous non-mineralized parenchyma measuring 1.1 cm caudal pole width.

### Spleen

The spleen exhibited a finely textured and homogenous parenchyma which was hyperechoic to the liver and renal cortical parenchyma. The capsule was smooth and regular without apparent expansion. The splenic vasculature at the hilus was normal in volume with no evidence of congestion or thrombosis. Acute to chronic inflammatory, neoplastic, or benign parenchyma changes were not noted.

### Liver/Gallbladder

The liver presented mildly enlarged in size. The parenchyma of the liver was subjectively normal in echogenicity compared to the spleen and renal cortices. The liver parenchyma was uniform with a mildly coarse echotexture. The capsule of the liver was symmetrically rounded to mildly swollen in margination. The hepatic and portal vasculature were normal in appearance without signs of



## PATIENT

Tank McGinnis

## SPECIES

Canine

## BREED

German Shep/Chow

## SEX

MN

## AGE

12yr

## WEIGHT

42.2lb

## INTERPRETED BY

R. McKenzie Daniel,  
DVM, DABVP  
(Canine and Feline)

## IMAGING PERFORMED BY

Meghan Myers VMD

## HOSPITAL NAME

Hershire Animal  
Hospital

## REFERRING VET

Dana Walck DVM

## INVOICE

24081

## DATE

03/02/2026

congestion. The gallbladder was non-distended in size with moderate gravity-dependent to mildly congealed hyperechoic non-organized debris. The cystic and common bile ducts were normal.

### **Gastrointestinal**

The stomach presented intact wall layering with a normal wall layer ratio. The lumen of the stomach was empty with no signs of ileus, obstruction or foreign material.

The small intestine presented intact wall layering with 1:3 muscularis/mucosa ratio. The lumen of the small intestine was empty with no signs of mechanical/metabolic ileus, obstruction or foreign material.

Normal visible colon wall layers were present with apparent formed feces in lumen.

### **Pancreas**

The parenchyma of the left limb, body and right limb of the pancreas presented isoechoic to the adjacent omental fat. A normal curvilinear capsule contour of the pancreas was present. The visible pancreatic duct was normal. No signs of active inflammation or neoplastic disease was evident.

### **Free Abdomen**

No omental masses, overt lymphadenopathy or peritoneal effusion was present.

## **ULTRASONOGRAPHIC FINDINGS**

### **Primary**

- Non-distended urinary bladder with dependent lumen accumulated mineral / small calculi
- Enlarged mineralized prostate and periprostatic urethra
- Mild chronic renal changes with non-obstructive renoliths
- Right adrenomegaly with non-capsule deforming left adrenal nodule
- Mild hepatomegaly
- Non-organized congealed gallbladder debris - not consistent with mature mucocele

## **INTERPRETATION OF THE FINDINGS & FURTHER RECOMMENDATIONS**

The mineralized prostatomegaly and mineralized thickened adjacent urethra is highly suggestive of neoplastic criteria, i.e. transitional cell or prostatic carcinoma. Overt extension into the urinary bladder was not obvious. This patient may be passing small amounts of mineral from the kidneys into the urinary bladder, although no evidence of ureteral obstruction. Prostatic sampling via prostatic wash or ultrasound guided FNA for cytology +/- C/S is required for further definition in conjunction with BRAF assay. No obvious evidence of current regional lymphatic metastatic criteria.

Adrenal hyperplasia, functional vs non-functional adenomatous change, emerging unilateral /bilateral adrenal tumors or metastasis is possible. Adrenal workup warranted if clinical signs consistent with Cushing syndrome are present. Monitoring of systemic BP for hypertension, which may suggest potential pheochromocytoma is recommended. Hepatosupportive medication is recommended if evidence of cholestasis.



**PATIENT**

Tank McGinnis

**SPECIES**

Canine

**BREED**

German Shep/Chow

**SEX**

MN

**AGE**

12yr

**WEIGHT**

42.2lb

**INTERPRETED BY**

R. McKenzie Daniel,  
DVM, DABVP  
(Canine and Feline)

**IMAGING PERFORMED BY**

Meghan Myers VMD

**HOSPITAL NAME**

Hershire Animal  
Hospital

**REFERRING VET**

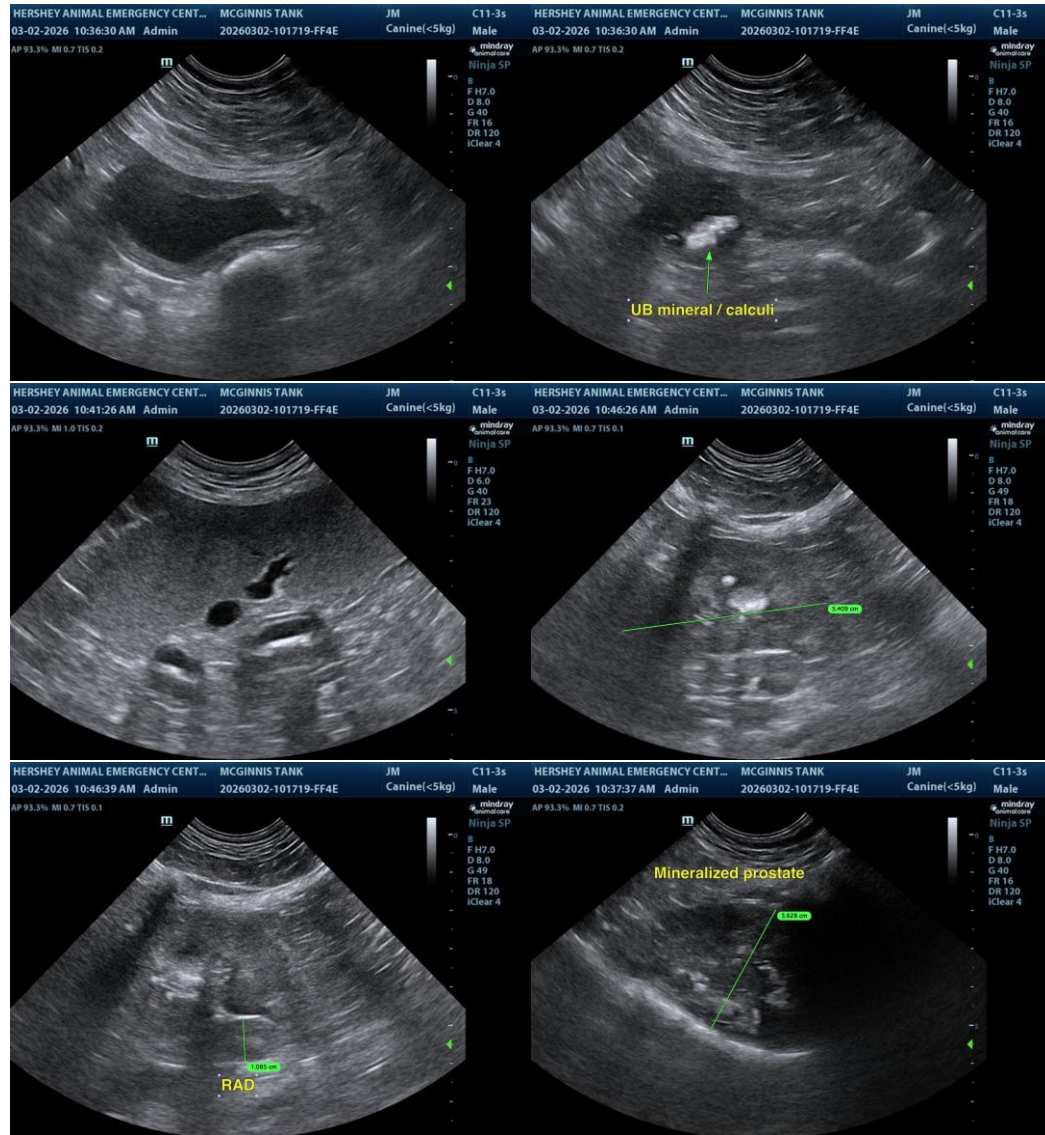
Dana Walck DVM

**INVOICE**

24081

**DATE**

03/02/2026





**PATIENT**

Tank McGinnis

**SPECIES**

Canine

**BREED**

German Shep/Chow

**SEX**

MN

**AGE**

12yr

**WEIGHT**

42.2lb

**INTERPRETED BY**

R. McKenzie Daniel,  
DVM, DABVP  
(Canine and Feline)

**IMAGING PERFORMED BY**

Meghan Myers VMD

**HOSPITAL NAME**

Hershire Animal  
Hospital

**REFERRING VET**

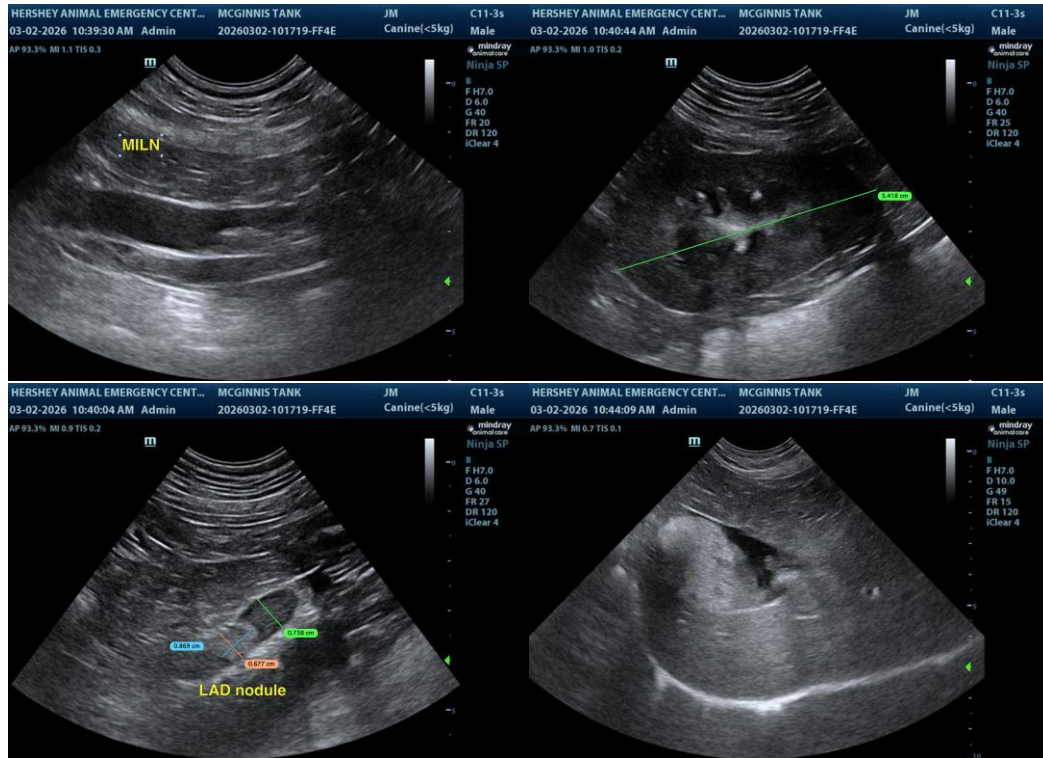
Dana Walck DVM

**INVOICE**

24081

**DATE**

03/02/2026



The information and recommendations provided are based on the images presented by the referring veterinarian/sonographer. No evaluation can be communicated regarding pathology that was not visible in the image/video clips provided.

Thank you for this referral. If the clinical or image interpretation does not parallel your findings or if I can be of any further assistance, please contact me.

R. McKenzie Daniel, DVM, DABVP (Canine/Feline Practice)  
[info@sonopath.com](mailto:info@sonopath.com)