



**PATIENT PRESENTING CLINICAL SIGNS**

**PATIENT**  
Max Velasquez  
History: Hx of losing weight, PU/PD for the past few weeks, since yesterday, loose stool/ melena, vomiting since yesterday night.

**SPECIES**  
Canine  
Abnormal PE/Chem/CBC/UA Results: Enlarged liver on abdominal palpation, tense/painful on cranial abdomen. ~ 5% dehydrated, BCS 7.5/9. poor coat. 3/1/22 BW: Superchem: Alk Phosphatase: 4794 (H) 5-131 GGTP: 18 (H) 1-12 Phosphorus: 7.0 (H) 2.5-6.0 Glucose: 391 (H) 70-138 Calcium: 7.7 (L) 8.9-11.4 Sodium: 133 (L) 139-154 Amylase: 12972 (H) 290-1125 Precision PSL: 9538 (H) 24-140  
**BREED**  
Poodle  
CBC: WBC: 29.6 (H) 4.0-15.5 T4: <0.5 (L) 0.8-3.5 UA: Protein: 3+ Glucose: 2+ Keotne: 4+ Transitional Epithella: 4-10 (H) Squamous Ephitella: 4-10 (H) Microalbumin: >30 (H) <2.5 Protein/Creatinine ratio: 12.5 (H) <0..5

**ULTRASONOGRAPHIC EXAMINATION OF THE ABDOMEN**

**SEX**  
*Urinary System*

Neutered Male  
The urinary bladder, trigone, cystourethral junction, and visible pelvic urethra to a depth of 3.0 cm exhibited normal thickness and tone. Anechoic urine was present in the lumen with no uroliths or sediment. The ureteral papillae were normal. The ureters were not visible which is normal. No evidence of inflammatory or neoplastic changes were noted. Aortic trifurcation as normal.

**AGE**  
7 Years  
Normal size and margination were present in the kidneys. A normal 1:3 cortex / medulla ratio and normal corticomedullary definition were maintained. The echogenicity of the cortex was similar to or slightly less than normal liver parenchyma while the medulla echogenicity was hypoechoic to the cortex with no evidence of pyelectasia. Pinpoint areas of medullary mineral were present. The left kidney measured 4.6 cm in length. The right kidney measured 5.2 cm in length.

**WEIGHT**  
17.8 Pounds

**INTERPRETED BY**  
*Adrenal Glands*

R. McKenzie Daniel, DVM, DABVP (Canine and Feline)  
Bilateral symmetrical adrenal gland enlargement with uniformly hypoechoic parenchyma was present. The left adrenal gland measured 0.60 cm width at the caudal pole and 0.54 cm width at the cranial pole. The right adrenal gland measured 0.77 cm width at the caudal pole and 0.67 cm width at the cranial pole.

**IMAGING PERFORMED BY**  
*Spleen*

Jose  
The spleen exhibited normal size and maintained, finely textured, homogeneous parenchyma. Areas of focal asymmetrical capsule contour were present, which may indicate areas of capsular fibrosis. Potential for possible benign myelolipomas were noted in the subjective medial parenchyma. No overt evidence of splenic neoplastic criteria.

**HOSPITAL NAME**  
*Liver*

Elmhurst AEH  
The liver exhibited marked generalized enlargement and symmetrical yet swollen hepatic contour. Diffuse, mildly nonuniform, hyperechoic parenchyma compared to the falciform fat and spleen. No hepatic masses or nodules noted.

**REFERRING VET**  
Dr. Suci  
The gallbladder walls were overtly normal without evidence of inflammatory changes. Mild dependent to nondependent gallbladder debris present. No evidence of peripheral gallbladder inflammation. The cystic duct and common bile ducts were normal without evidence of dilation.

**INVOICE**  
14143

**DATE**  
*Gastrointestinal*

3/2/22



<b>PATIENT</b>	The stomach presented mild to moderate wall thickening secondary to echogenic mucosa hypertrophy. Intact wall layering was maintained and distinct. Mild gastric distension with minor retained gastric fluid. The gastric body wall measured 0.38 cm.
Max Velasquez	
<b>SPECIES</b>	The duodenum exhibited intact yet prominent wall layering with segmental duodenal corrugation. The duodenum wall measured 0.38 cm. The jejunum wall measured 0.31 cm. The jejunum and ileum to the level of the colon were sonographically unremarkable.
Canine	
<b>BREED</b>	Normal visible colon wall layers were present with semi-formed feces in lumen.
Poodle	
<b>SEX</b>	<b>Pancreas</b>
Neutered Male	The pancreas exhibited generalized enlargement with swollen contour. Mildly hypoechoic to nonhomogeneous parenchyma compared to regional hyperechoic peripancreatic omentum. Potential for areas of pancreatic fibrosis possible. No overt pancreatic masses noted.
<b>AGE</b>	<b>Free Abdomen</b>
7 Years	No overt lymphadenopathy or evidence of free fluid.
<b>WEIGHT</b>	<b>ULTRASONOGRAPHIC FINDINGS</b>
17.8 Pounds	<ul style="list-style-type: none"> <li>• Marked hepatomegaly, exhibiting generalized parenchyma hyperechogenicity- steroid or other vacuolar hepatopathy, metabolic (diabetic) hepatopathy, chronic hepatitis/cholangiohepatitis, lipidoses possible. Potential for hepatic neoplasia is considered a less likely differential diagnosis.</li> <li>• Mild gallbladder debris (non-mucocele)</li> <li>• Active to chronic active pancreatitis pattern with regional peripancreatic reactive mesentery, potential for pancreatic fibrosis</li> <li>• Gastroenterocolitis pattern with moderate gastroduodenitis</li> <li>• Prominent bilateral adrenal glands</li> </ul>
<b>INTERPRETED BY</b>	<b>INTERPRETATION OF THE FINDINGS &amp; FURTHER RECOMMENDATIONS</b>
R. McKenzie Daniel, DVM, DABVP (Canine and Feline)	Urine culture and sensitivity, given the glucosuria as well as fructosamine level warranted. If strong clinical suspicion for hyperadrenocorticism, ACTH stimulation test is recommended. A GI panel to include PLI/TLI/Cobalamin/Folate is recommended.
<b>IMAGING PERFORMED BY</b>	Empirically, hospitalization with diabetic ketoacidosis/pancreatitis therapy with electrolyte supplementation and as needed gastrointestinal support would be reasonable.
Jose	
<b>HOSPITAL NAME</b>	
Elmhurst AEH	
<b>REFERRING VET</b>	
Dr. Suci	For an additional charge, internal medicine consult can be utilized through SonoPath.com. You can select the internal medicine drop down at <a href="http://spa.sonopath.com/">http://spa.sonopath.com/</a> .
<b>INVOICE</b>	
14143	One of the world's top internists & SonoPath associate Dr. Remo Lobetti BVSc, MMedVet, PhD, DECVIM can evaluate your case through SonoPath. <a href="https://sonopath.com/resources/sonopath-services/internal-medicine-teleconsultation-services">https://sonopath.com/resources/sonopath-services/internal-medicine-teleconsultation-services</a>
<b>DATE</b>	
3/2/22	



**PATIENT**

Max Velasquez

**SPECIES**

Canine

**BREED**

Poodle

**SEX**

Neutered Male

**AGE**

7 Years

**WEIGHT**

17.8 Pounds

**INTERPRETED BY**

R. McKenzie Daniel,  
DVM, DABVP  
(Canine and Feline)

**IMAGING PERFORMED BY**

Jose

**HOSPITAL NAME**

Elmhurst AEH

**REFERRING VET**

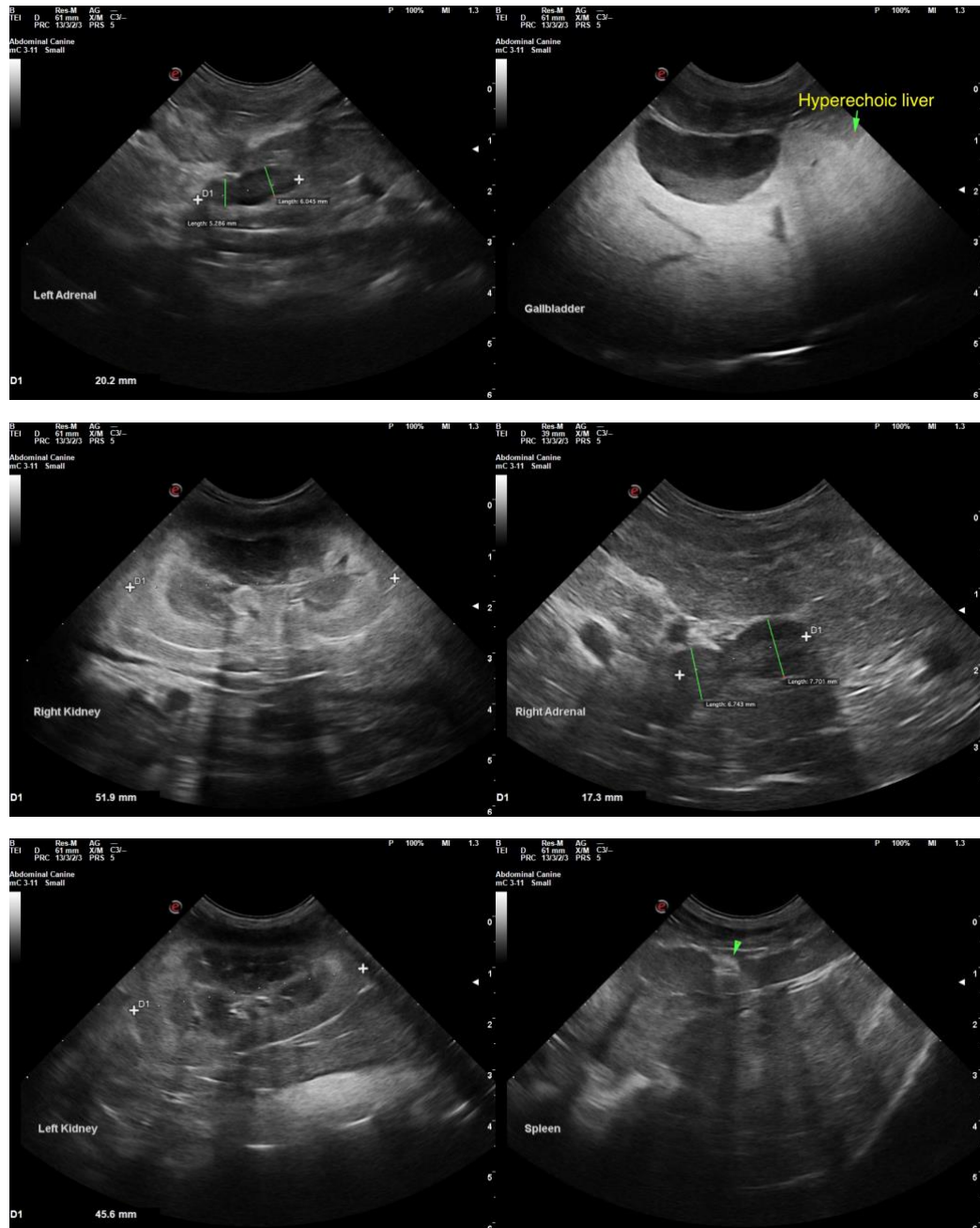
Dr. Suci

**INVOICE**

14143

**DATE**

3/2/22





**PATIENT**

Max Velasquez

**SPECIES**

Canine

**BREED**

Poodle

**SEX**

Neutered Male

**AGE**

7 Years

**WEIGHT**

17.8 Pounds

**INTERPRETED BY**

R. McKenzie Daniel,  
DVM, DABVP  
(Canine and Feline)

**IMAGING PERFORMED BY**

Jose

**HOSPITAL NAME**

Elmhurst AEH

**REFERRING VET**

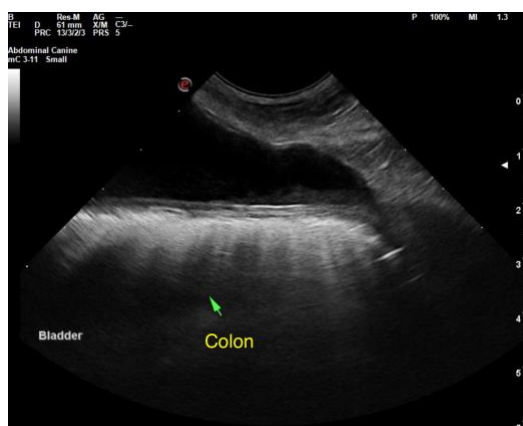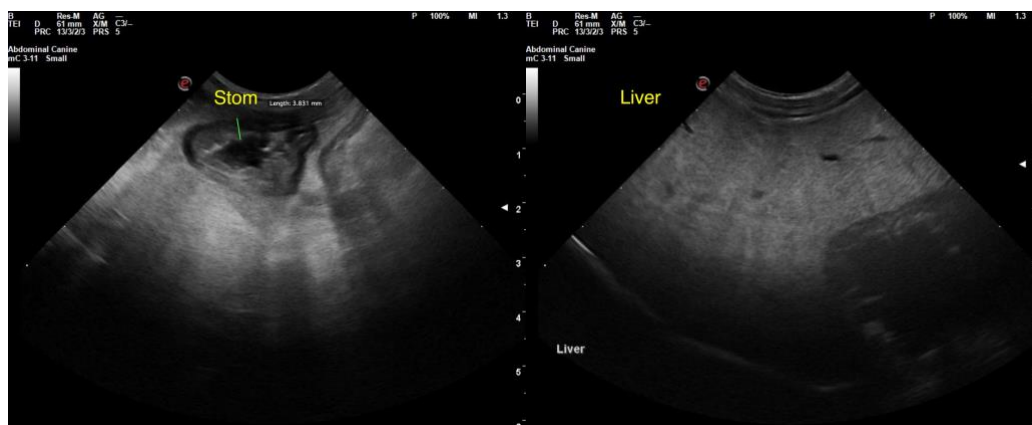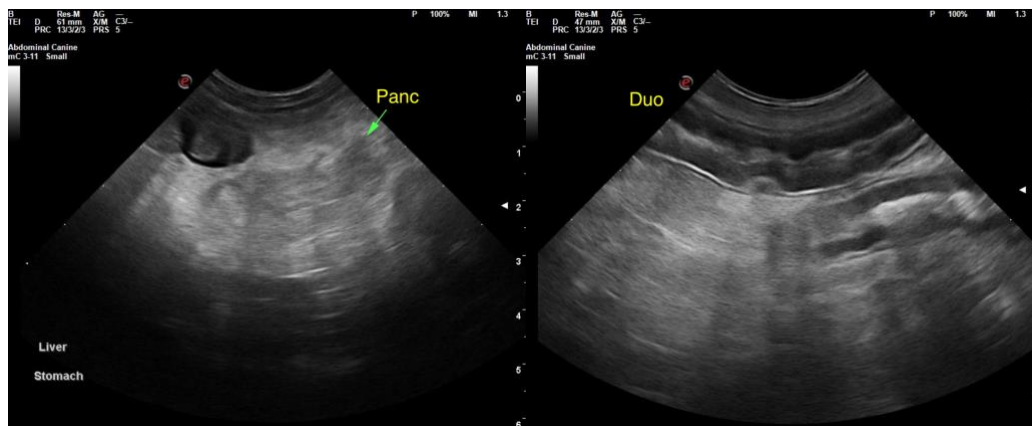Dr. Suci

**INVOICE**

14143

**DATE**

3/2/22



The information and recommendations provided are based on the images presented by the referring veterinarian. No evaluation can be communicated regarding pathology that was not visible in the image/video clips provided.

Thank you for this referral. If the clinical or image interpretation does not parallel your findings or if I can be of any further assistance please contact me.

R. McKenzie Daniel, DVM, DABVP (Canine / Feline Practice)  
info@SonoPath.com



**PATIENT**

Max Velasquez

**SPECIES**

Canine

**BREED**

Poodle

**SEX**

Neutered Male

**AGE**

7 Years

**WEIGHT**

17.8 Pounds

**INTERPRETED BY**

R. McKenzie Daniel,  
DVM, DABVP  
(Canine and Feline)

**IMAGING  
PERFORMED BY**

Jose

**HOSPITAL NAME**

Elmhurst AEH

**REFERRING VET**

Dr. Suciu

**INVOICE**

14143

**DATE**

3/2/22