



PATIENT PRESENTING CLINICAL SIGNS

Jules Hallgrimson History: 3/6 murmur on pre anesthetic assessment for dental procedure gabapentin and butorphanol for scan
 Abnormal PE/Chem/CBC/UA Results: No abnormalities

SPECIES

Canine

ULTRASONOGRAPHIC EXAMINATION OF THE HEART

BREED

Collie X

SEX

Spayed Female

AGE

12 Years

WEIGHT

22 kg

CANINE CARDIAC PARAMETERS	MR VMAX (m/s)	TR VMAX (m/s)	LA/AO (Boon method)	LA/AO (Heart Base; Swe)	FS (%)	EF (%)	EPSS (cm)
NORMAL PARAMETER	4.5-5.5	<2.7	1.3	<1.6	28-40	40-100	<0.6
PATIENT	--	<1.0	1.34	1.5	51.6	84.4	0.2
CANINE CARDIAC PARAMETERS	HR (BPM)	AV VMAX (m/s)	PV MAX (m/s)	BODY WEIGHT (kg)	LA 2D short axis Base view (cm)	LVIDd Avg; 2D and m-mode short axis (cm)	LVIDs Avg; 2D and m-mode short axis (cm)
NORMAL PARAMETER	50-100	0.7-1.7	0.7-1.6	BELOW	BELOW	BELOW	BELOW
PATIENT	105	1.6	1.0	--	2.8	2.7	--

INTERPRETED BY

R. McKenzie Daniel, DVM, DABVP (Canine and Feline)

IMAGING PERFORMED BY

Dr. Belan

HOSPITAL NAME

Healing Traditions

REFERRING VET

Dr. Balac

INVOICE

14144

DATE

3/2/22

Cardiac Presentation

The echocardiogram in this patient demonstrated normal **left atrial** size based on 3 separate methods of LA evaluation. The cranial and caudal **mitral** valve leaflets presented mild vegetative thickening, suggestive of endocardiosis with normal extension in systole, and union in diastole with normal kinesis and without evidence of valvular prolapse. No appreciable MR. The **left ventricle** presented thicknesses with linear contour and was not dilated nor restricted. The **myocardium** presented normal echogenicity without subjective evidence of significant fibrotic or ischemic disease. **Contractility** of the ventricular walls was adequate and in normal range for this patient evidenced by the fractional shortening measurement and subjective evaluation of the different regions of the myocardium. The **left ventricular outflow** tract demonstrated normal laminar flow and subjective structural integrity. The **right atrium** and auricle revealed normal size, structure and content. No evidence of masses was noted. **Tricuspid** valvular assessment demonstrated concurrent mild thickening with normal kinesis. No evidence of significant TR. The **right ventricle** was of normal size (1/3 diameter of LV), chordae structure, myocardial echogenicity and thickness. **Pulmonary outflow** tract assessment revealed normal valve structure, laminar flow, and diameter (approx. 1:1 pa/ao ratio). No visible **pericardial** or free pleura fluid was noted. The cranial **mediastinum and pericardial and extra-cardiac regions** were free of masses in the visible window.

ULTRASONOGRAPHIC FINDINGS

- Normal cardiac structure and function



PATIENT

Jules Hallgrimson

- Mildly thickened MV and TV- consistent with mild acquired/age-related degenerative valvular changes

SPECIES

Canine

BREED

Collie X

SEX

Spayed Female

AGE

12 Years

WEIGHT

22 kg

INTERPRETED BY

R. McKenzie Daniel,
DVM, DABVP
(Canine and Feline)

IMAGING PERFORMED BY

Dr. Belan

HOSPITAL NAME

Healing Traditions

REFERRING VET

Dr. Balac

INVOICE

14144

DATE

3/2/22

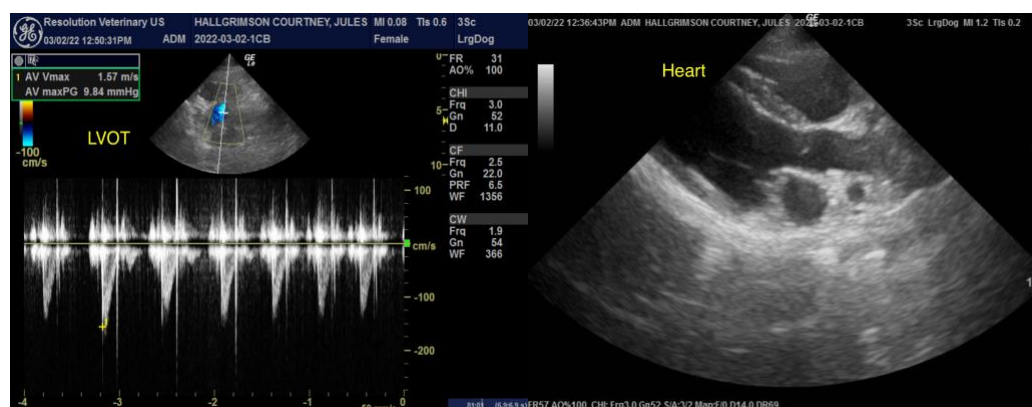
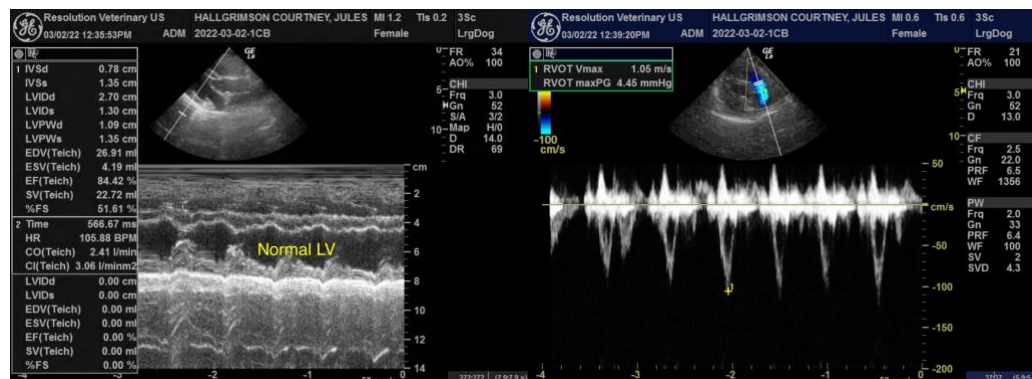
INTERPRETATION OF THE FINDINGS & FURTHER RECOMMENDATIONS

No evidence of significant structural or functional cardiomyopathy. A definitive cause of the murmur was not overtly evident. Assuming no evidence of significant volume changes (i.e., dehydration) or presence of anemia, a benign physiologic flow murmur or small flow abnormality (not visualized) may be possible. Admittedly, the reported moderate murmur is not overtly consistent with what is typically associated with physiologic or flow murmur. Given the patients age and mild degenerative mitral and tricuspid valve changes, compensated mitral or tricuspid valve insufficiency could be present. Regardless, given the lack of left or right heart chamber enlargement and lack of other clinical issues, such as systolic dysfunction or overt clinical pulmonary hypertension, the risk for complications secondary to the murmur is considered low.

No indication for cardiac medications. Likewise, no overt anesthetic contraindications at this stage. Continued monitoring of the murmur would be appropriate with recheck echocardiogram suggested in 6 months to assess for evidence of progression or sooner if clinical signs consistent with heart disease arise or if murmur intensity increases.

Suggested anesthetic protocol may include opioid or Benzodiazepine pre-med, induction with Propofol or Alfaxalone, and appropriate gas anesthesia with avoidance of alpha 2 agonists.

<https://www.antechdiagnostics.com/cadet-braf>





PATIENT

Jules Hallgrimson

SPECIES

Canine

BREED

Collie X

SEX

Spayed Female

AGE

12 Years

WEIGHT

22 kg

INTERPRETED BY

R. McKenzie Daniel,
DVM, DABVP
(Canine and Feline)

IMAGING PERFORMED BY

Dr. Belan

HOSPITAL NAME

Healing Traditions

REFERRING VET

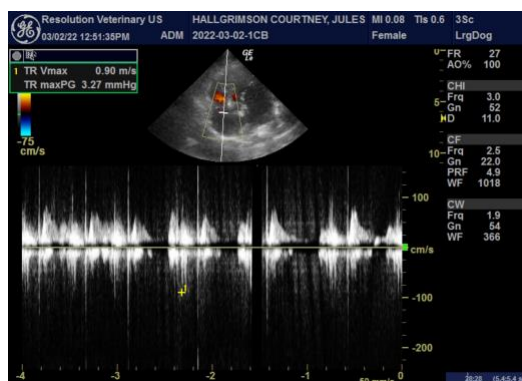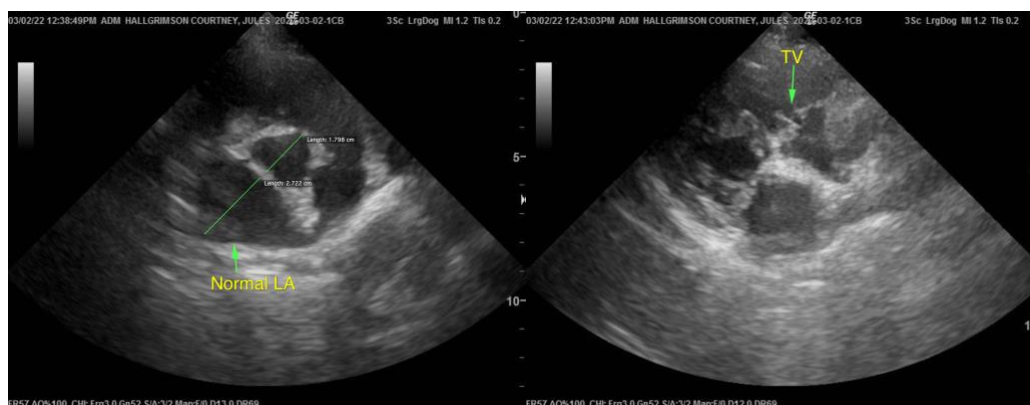
Dr. Balac

INVOICE

14144

DATE

3/2/22



The information and recommendations provided are based on the images presented by the referring veterinarian. No evaluation can be communicated regarding pathology that was not visible in the image/video clips provided.

Thank you for this referral. If the clinical or image interpretation does not parallel your findings or if I can be of any further assistance please contact me.

R. McKenzie Daniel, DVM, DABVP (Canine / Feline Practice)
info@SonoPath.com