


**PATIENT**

Foxy Miller

**SPECIES**

Canine

**BREED**

Pomeranian

**SEX**

Spayed female

**AGE**

15 years

**WEIGHT**

9.76 pounds

**PRESENTING CLINICAL SIGNS**

 History: Patient presents for echo. No reported meds or clinical symptoms.  
 Abnormal PE/Chem/CBC/UA Results:

**ULTRASONOGRAPHIC EXAMINATION OF THE HEART**

CANINE CARDIAC PARAMETERS	MR VMAX (m/s)	TR VMAX (m/s)	LA/AO (Boon method)	LA/AO (Heart Base; Swe)	FS (%)	EF (%)	EPSS (cm)
NORMAL PARAMETER	4.5-5.5	<2.7	1.3	<1.6	28-40	40-100	<0.6
PATIENT	5.2	1.4	1.4	1.2	32.5	64.4	0.32
CANINE CARDIAC PARAMETERS	HR (BPM)	AV VMAX (m/s)	PV MAX (m/s)	BODY WEIGHT (kg)	LA 2D short axis Base view (cm)	LVIDd Avg; 2D and m-mode short axis (cm)	LVIDs Avg; 2D and m-mode short axis (cm)
NORMAL PARAMETER	50-100	0.7-1.7	0.7-1.6	BELOW	BELOW	BELOW	BELOW
PATIENT	127	1.0	0.7		2.0	2.0	

**INTERPRETED BY**

 R. McKenzie Daniel,  
 DVM, DABVP  
 (Canine and Feline)

**IMAGING PERFORMED BY**  
 Kelly Vasquez

**HOSPITAL NAME**

 Westwood Regional  
 Veterinary Hospital

**REFERRING VET**

Dr. Silver

**INVOICE**

10102ag

**DATE**

03/02/2022

**Cardiac Presentation**

The echocardiogram in this patient demonstrated normal left atrial size based on 3 different LA measurement methods. Chamber volumes and echogenicity were normal. The cranial and caudal mitral valve leaflets presented vegetative thickening consistent with endocardiosis. Doppler indicated measurable mild eccentric insufficiency. The left ventricle presented thicknesses with linear contour and was not dilated nor restricted. The myocardium presented normal echogenicity without subjective evidence of significant fibrotic or ischemic disease. Contractility of the ventricular walls was adequate and in normal range for this patient evidenced by the fractional shortening measurement and subjective evaluation of the different regions of the myocardium. The left ventricular outflow tract demonstrated normal laminar flow and subjective structural integrity. The right atrium and auricle revealed normal size, structure and content. No evidence of masses was noted or chamber overload. Tricuspid valvular assessment demonstrated minor TV insufficiency on Doppler. The right ventricle was of normal size (1/3 diameter of LV), chordae structure, myocardial echogenicity and thickness. Pulmonic tract assessment revealed normal valve structure, laminar flow, and diameter (approx.1:1 pa/ao ratio). No visible pericardial or free pleura fluid was noted. No echographically detectable evidence of infiltrative disease was visible. The cranial mediastinum and pericardial regions were free of masses in the visible window.



**PATIENT**

Foxy Miller

**SPECIES**

Canine

**BREED**

Pomeranian

**SEX**

Spayed female

**AGE**

15 years

**WEIGHT**

9.76 pounds

**INTERPRETED BY**

R. McKenzie Daniel,  
DVM, DABVP  
(Canine and Feline)

**IMAGING PERFORMED BY**  
Kelly Vasquez

**HOSPITAL NAME**

Westwood Regional  
Veterinary Hospital

**REFERRING VET**

Dr. Silver

**INVOICE**

10102ag

**DATE**

03/02/2022

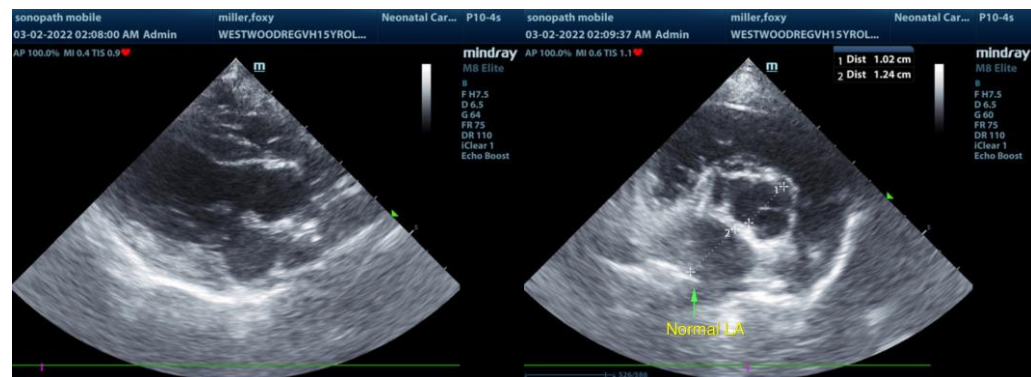
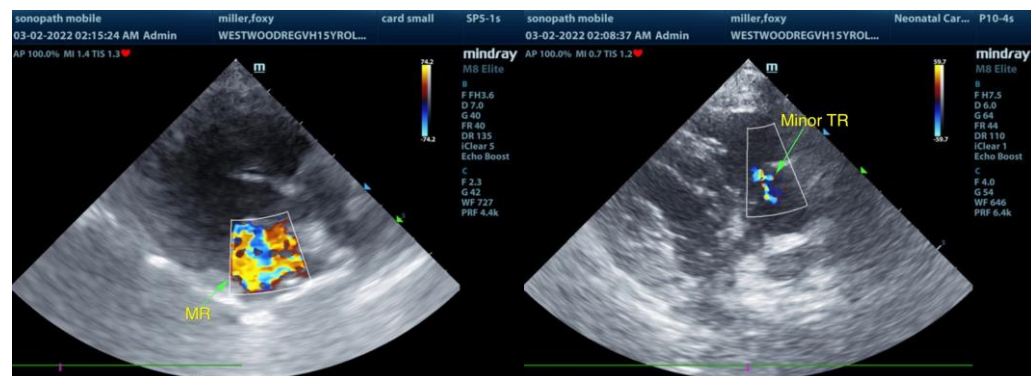
**ULTRASONOGRAPHIC FINDINGS**

- Chronic mitral valve disease (ACVIM B1)
- Minor TR-estimated pulmonary pressure gradient not consistent with pulmonary hypertension.

**INTERPRETATION OF THE FINDINGS & FURTHER RECOMMENDATIONS**

The cause of the murmur is chronic degenerative valvular changes with secondary eccentric mitral valve insufficiency. The lack of left atrial enlargement implies that the risk of complication secondary to mitral valve insufficiency is low at this time and, without current clinical signs, indicates that medical therapy is not required. Conservative monitoring is recommended with a recheck echocardiogram in 6-12 months, sooner if clinical signs suggestive of heart disease develop.

No anesthetic contraindications. Suggested anesthetic protocol may include opioid or Benzodiazepine pre-med, induction with Propofol or Alfaxalone, and appropriate gas anesthesia with avoidance of alpha 2 agonists.





**PATIENT**

Foxy Miller

**SPECIES**

Canine

**BREED**

Pomeranian

**SEX**

Spayed female

**AGE**

15 years

**WEIGHT**

9.76 pounds

**INTERPRETED BY**

R. McKenzie Daniel,  
DVM, DABVP  
(Canine and Feline)

**IMAGING  
PERFORMED BY**

Kelly Vasquez

**HOSPITAL NAME**

Westwood Regional  
Veterinary Hospital

**REFERRING VET**

Dr. Silver

**INVOICE**

10102ag

**DATE**

03/02/2022

The information and recommendations provided are based on the images presented by the referring veterinarian/sonographer. No evaluation can be communicated regarding pathology that was not visible in the image/video clips provided.

Thank you for this referral. If the clinical or image interpretation does not parallel your findings or if I can be of any further assistance please contact me.

R. McKenzie Daniel, DVM, DABVP (Canine / Feline Practice)

info@SonoPath.com