



PATIENT

Cody Howie

SPECIES

Canine

BREED

Mini Dachshund

SEX

MN

AGE

14y, 9m

WEIGHT

9.0 kgs

INTERPRETED BY

R. McKenzie Daniel,
 DVM, DABVP
 (Canine and Feline)

IMAGING PERFORMED BY

Vincent Ravancho, CVT

HOSPITAL NAME

Martinsville VH

REFERRING VET

Dr. Shendell

INVOICE

10696

DATE

3/18/26

PRESENTING CLINICAL SIGNS

History:

- New right sided heart murmur, asymptomatic
- Polydipsic, Polyphagia
- Current medications - Seresto collar, Interceptor Plus

Abnormal PE/Chem/CBC/UA Results: USG 1.011 PLT 450 HCT 46%

ULTRASONOGRAPHIC EXAMINATION OF THE HEART & ABDOMEN

CANINE CARDIAC PARAMETERS	MR VMAX (m/s)	TR VMAX (m/s)	LA/AO (M-Mode)	LA/AO (Heart Base; Swe)	FS (%)	EF (%)	EPSS (cm)
NORMAL PARAMETER	4.5-5.5	<2.7	1.3	Up to 1.6	28-40	40-100	<0.6
PATIENT	5.2	<2.0	-	1.35	45	79	0.1
CANINE CARDIAC PARAMETERS	HR (BPM)	AV VMAX (m/s)	PV MAX (m/s)	BODY WEIGHT	LAD LA MAX4 Chamber	LVIDd Avg; 2D and m-mode short axis (cm)	LVIDs Avg; 2D and m-mode short axis (cm)
NORMAL PARAMETER	50-100	0.7-1.7	0.7-1.6				
PATIENT	NM	1.4	0.85	9.0 kgs	2.5	2.2	-

Cardiac Presentation

The echocardiogram in this patient demonstrated normal **left atrial** size based on 2 different LA measurement methods. The cranial and caudal **mitral** valve leaflets presented thickening consistent with endocardiosis. Doppler indicated measurable mild to moderate eccentric MR (MR velocity 5.2 m/s). The **left ventricle** presented thicknesses with linear contour and was not dilated nor restricted. The **myocardium** presented normal echogenicity without subjective evidence of significant fibrotic or ischemic disease. **Contractility** of the ventricular walls was adequate and in normal range for this patient evidenced by the fractional shortening measurement and subjective evaluation of the different regions of the myocardium. The **left ventricular outflow** tract demonstrated normal laminar flow and subjective structural integrity. The **right atrium** and auricle revealed normal size, structure and content. No evidence of masses was noted or chamber overload. **Tricuspid** valvular assessment demonstrated mild thickening with mild TR (Measured TR velocity <2.0 m/s). The **right ventricle** was of normal size (1/3 diameter of LV), chordae structure, myocardial echogenicity and thickness. **Pulmonic** tract assessment revealed normal valve structure, laminar flow, and diameter (approx.1:1 pa/ao ratio). No visible **pericardial** or free pleura fluid was noted. No echographically detectable evidence of cardiac / pericardial tumors was visible.



PATIENT

Urinary System

Cody Howie

The urinary bladder was nondistended with urine. The urinary bladder, trigone, cystourethral junction, and visible pelvic urethra to a depth of 3.0 cm exhibited normal thickness and tone. Anechoic urine was present in the lumen with no uroliths or sediment. The ureteral papillae were normal. The ureters were not visible which is normal. No evidence of inflammatory or neoplastic changes were noted.

SPECIES

Canine

The area of the residual prostate appeared normal and free of pathology

BREED

Mini Dachshund

The area of the iliac trifurcation was free of pathology.

SEX

MN

Normal size and margination were present in the kidneys. A normal 1:3 cortex / medulla ratio was maintained. The medulla and cortices were uniform in texture with some increased echogenicity and mild to moderate loss of corticomedullary symmetry and definition expected for the age of the patient. Mild left kidney pyelectasia was present. The left kidney measured 4.6 cm in length. The right kidney measured 4.9 cm in length.

AGE

14y, 9m

Adrenal Glands

The left adrenal gland was uniform in size and contour with a uniformly hypoechoic parenchyma. The left adrenal gland measured 0.52 cm width at the caudal pole. The right adrenal gland was uniform in size and contour with a uniformly hypoechoic parenchyma. The right adrenal gland measured 0.45 cm width at the caudal pole.

WEIGHT

9.0 kgs

Spleen

INTERPRETED BY

R. McKenzie Daniel,
DVM, DABVP
(Canine and Feline)

The spleen exhibited a finely textured and homogenous parenchyma which was hyperechoic to the liver and renal cortical parenchyma. A solitary, discreet, hypoechoic mid-splenic nodule was present, measuring 0.48 cm diameter. A separate mildly nonhomogeneous cranial medial splenic nodule without associated capsule distortion was present, measuring 0.81 cm diameter. The capsule was smooth and regular without apparent expansion. The splenic vasculature at the hilus was normal in volume with no evidence of congestion or thrombosis. Acute to chronic inflammatory, neoplastic, or benign parenchyma changes were not noted.

IMAGING PERFORMED BY

Vincent Ravancho, CVT

Liver/ Gallbladder

HOSPITAL NAME

Martinsville VH

The liver was subjectively normal in size, structure, and contour. Normal hepatic vascular volume was present. The liver parenchyma was uniform and hypoechoic to the spleen with a mild coarse echotexture. The hepatic and portal vasculature were normal in appearance without signs of congestion. The gallbladder was non-distended in size containing primarily anechoic content with mild, nonorganized gallbladder debris. The cystic and common bile ducts were normal.

REFERRING VET

Dr. Shendell

Gastrointestinal

INVOICE

10696

The stomach presented intact wall layering with a normal wall layer ratio. The lumen of the stomach was empty without evidence of retained ingesta or foreign material. Mild retained fluid was noted.

DATE

3/18/26

The small intestine presented intact wall layering with 1:3 muscularis/mucosa ratio. The lumen of the small intestine was empty with no signs of ileus, obstruction, or foreign material.

Normal visible colon wall layers were present with formed feces in lumen.



PATIENT

Cody Howie

SPECIES

Canine

BREED

Mini Dachshund

SEX

MN

AGE

14y, 9m

WEIGHT

9.0 kgs

Pancreas

The pancreas was normal in size, exhibiting an indistinct capsule compared to adjacent omentum with nonhomogeneous, mildly hyperechoic right pancreatic limb parenchyma. These changes may suggest chronic inflammation, fibrosis, or saponification if previous history of pancreatitis. No overt signs of pancreatic neoplasia.

Free Abdomen

No overt lymphadenopathy or peritoneal effusion was present.

ULTRASONOGRAPHIC FINDINGS

- Compensated mitral valve disease (B1)
- TV insufficiency - no overt clinical pulmonary hypertension
- Chronic renal changes with mild left kidney pyelectasia
- Normal adrenal glands
- Sonographically unremarkable normal volume liver
- Mild gallbladder debris (non mucocele)
- Small hypoechoic to nonhomogeneous splenic nodules
- Pancreatic remodeling with possible fibrosis

INTERPRETED BY

R. McKenzie Daniel,
DVM, DABVP
(Canine and Feline)

IMAGING PERFORMED BY

Vincent Ravancho, CVT

HOSPITAL NAME

Martinsville VH

REFERRING VET

Dr. Shendell

INVOICE

10696

DATE

3/18/26

INTERPRETATION OF THE FINDINGS & FURTHER RECOMMENDATIONS

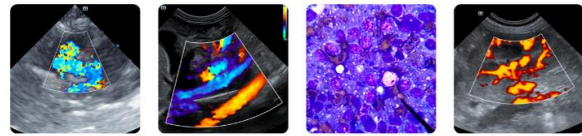
The cause of the murmur is chronic degenerative valvular changes with secondary eccentric mitral valve insufficiency and tricuspid valve insufficiency. The lack of left atrial enlargement implies that the risk of complication secondary to mitral valve insufficiency is low at this time and, without current clinical signs, indicates that medical therapy is not required. Prognosis is considered variable and sonographic monitoring is recommended. Recheck echocardiogram is suggested in 6-12 months, sooner if clinical signs arise. Anesthetic risk is considered low. If required, the following protocol is recommended.

Full urinary workup including urinalysis, C/S, and UPC level for renal staging is recommended. No overt evidence of adrenal pathology as a contributing factor to the patient's clinical signs. Adrenal screening could be considered despite lack of adrenal pathology if clinical signs are suggestive of Cushing's Syndrome.

Potential etiologies for the splenic nodules may include benign processes such as nodular hyperplasia, extramedullary hematopoiesis, hematoma, infection, infarction, or neoplasia. Ultrasound guided FNA of the nodule using 25-gauge needle and assuming normal coagulation parameters may be considered. Otherwise, sonographic monitoring of the splenic nodules for any changes in size or appearance with initial recheck in 3-4 weeks would be a more conservative approach.

A spec cPL could be considered if clinical signs suggestive of chronic pancreatitis are noted.

Suggested anesthetic protocol may include opioid or Benzodiazepine pre-med, induction with Propofol or Alfaxalone, and appropriate gas anesthesia with avoidance of alpha 2 agonists.



PATIENT

Cody Howie

SPECIES

Canine

BREED

Mini Dachshund

SEX

MN

AGE

14y, 9m

WEIGHT

9.0 kgs

INTERPRETED BY

R. McKenzie Daniel,
 DVM, DABVP
 (Canine and Feline)

IMAGING PERFORMED BY

Vincent Ravancho, CVT

HOSPITAL NAME

Martinsville VH

REFERRING VET

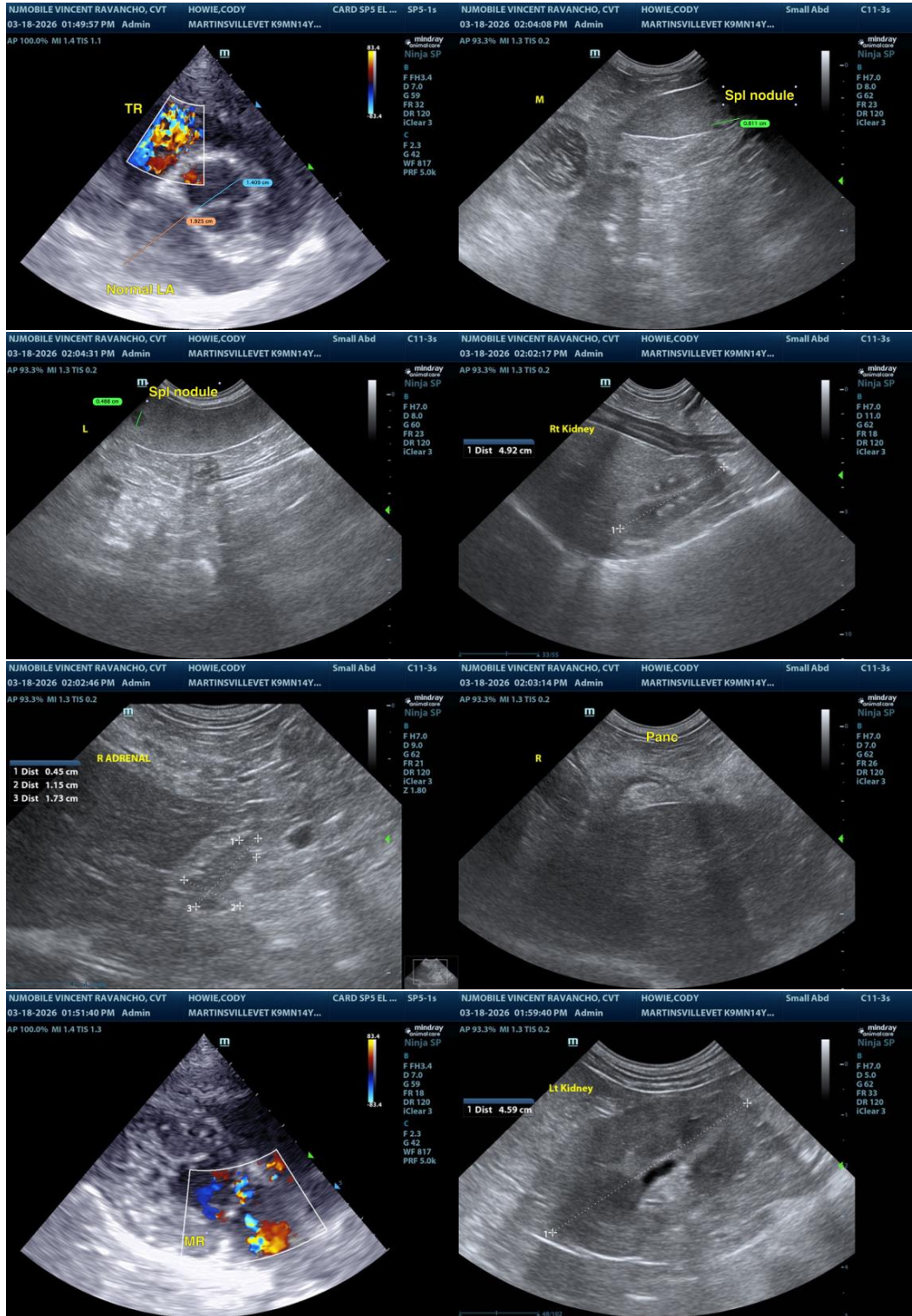
Dr. Shendell

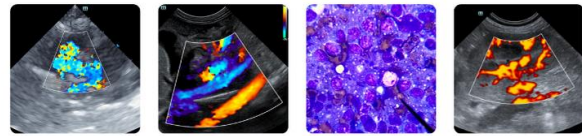
INVOICE

10696

DATE

3/18/26





PATIENT

Cody Howie

SPECIES

Canine

BREED

Mini Dachshund

SEX

MN

AGE

14y, 9m

WEIGHT

9.0 kgs

INTERPRETED BY

R. McKenzie Daniel,
 DVM, DABVP
 (Canine and Feline)

IMAGING PERFORMED BY

Vincent Ravancho, CVT

HOSPITAL NAME

Martinsville VH

REFERRING VET

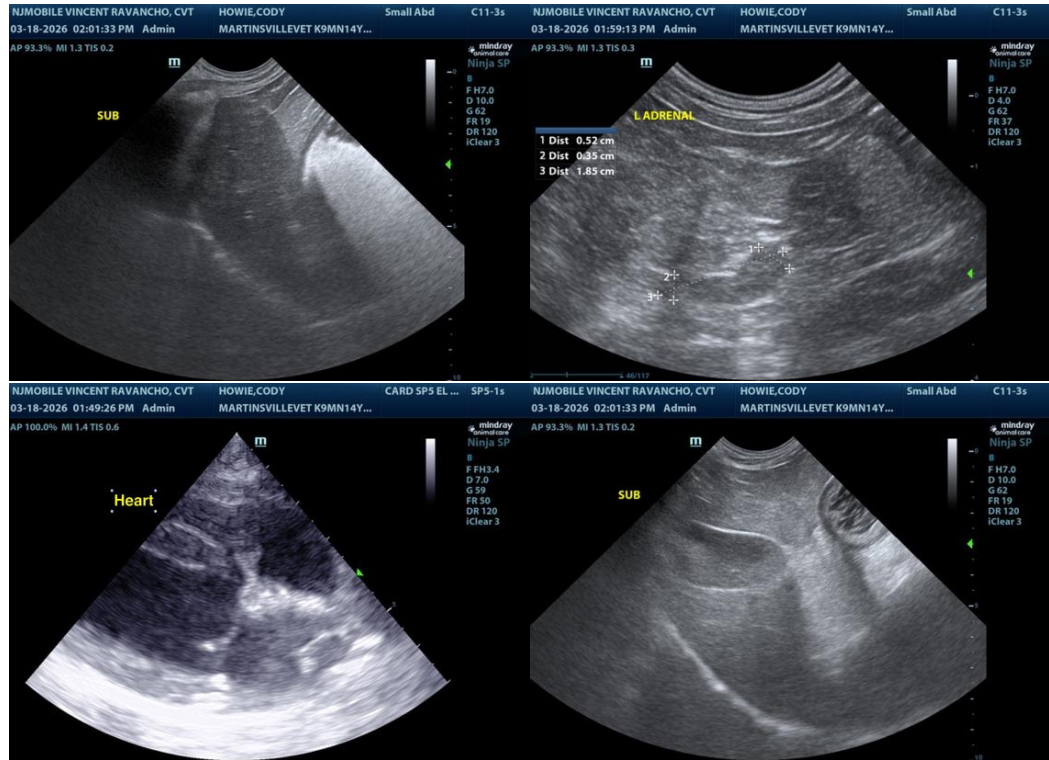
Dr. Shendell

INVOICE

10696

DATE

3/18/26



The information and recommendations provided are based on the images presented by the referring veterinarian/sonographer. No evaluation can be communicated regarding pathology that was not visible in the image/video clips provided.

Thank you for this referral. If the clinical or image interpretation does not parallel your findings or if I can be of any further assistance, please contact me.

R. McKenzie Daniel, DVM, DABVP (Canine/Feline Practice)
info@sonopath.com