



PATIENT PRESENTING CLINICAL SIGNS

Gemma Baran History: Chronic hematuria, cystitis

SPECIES Abnormal PE/Chem/CBC/UA Results: UA SG 1.030 cloudy neg protein neg glucose, no epithelial cells or bacteria

Canine **ULTRASONOGRAPHIC EXAMINATION OF THE ABDOMEN**

BREED *Urinary System*

Lab X The urinary bladder was overall normal in size and tone. Anechoic urine was present in the lumen with no uroliths, mineral or sediment. A focal ventral polyp to possible focal polyploid cystitis measuring 1.0 cm x 0.7 cm was noted. No evidence of associated mineralization in the polyp parenchyma. Subtly prominent adjacent ventral and apical urinary bladder wall measuring 0.23 cm was noted. The polyp and the bladder wall exhibited normal echoic mural echogenicity. The urethra exhibited normal structure and tone to a depth of 4 cm.

SEX Spayed female Normal size and margination were present in the kidneys. A normal 1:3 cortex / medulla ratio and normal corticomedullary definition were maintained. The echogenicity of the cortex was similar to or slightly less than normal liver parenchyma while the medulla echogenicity was hypoechoic to the cortex with no evidence of pelvic dilation. The left kidney measured 6.7 cm in length. The right kidney measured 6.2 cm in length.

WEIGHT *Adrenal Glands*

65 pounds The left adrenal gland was uniform in size and contour with a uniformly hypoechoic parenchyma. The left adrenal gland measured 0.55 cm width at the caudal pole and 0.42 cm width at the cranial pole. The right adrenal gland was uniform in size and contour with a uniformly hypoechoic parenchyma. The right adrenal gland measured 0.62 cm width at the caudal pole and 0.78 cm width at the cranial pole.

INTERPRETED BY R. McKenzie Daniel, DVM, DABVP (Canine and Feline)

Spleen The spleen exhibited a finely textured and homogenous parenchyma which was hyperechoic to the liver and renal cortical parenchyma. The capsule was smooth and regular without apparent expansion. The splenic vasculature at the hilus was normal in volume with no evidence of congestion or thrombosis. Acute to chronic inflammatory, neoplastic, or benign parenchyma changes were not noted.

IMAGING PERFORMED BY

Rebekah Jakum, CVT ARDMS/RVT

Liver

The liver was subjectively normal in size, structure, and contour. The liver parenchyma was uniform and hypoechoic to the spleen with a mild coarse echotexture. The hepatic and portal vasculature were normal in appearance without signs of congestion. The gallbladder was non-distended in size with thin walls and primarily anechoic luminal content. The cystic and common bile ducts were normal.

HOSPITAL NAME

Littlestown Veterinary Hospital

REFERRING VET

Dr. Jennings

Gastrointestinal

The stomach presented intact wall layering with a normal wall layer ratio. The lumen of the stomach was empty with no signs of ileus, obstruction or foreign material.

INVOICE

10197ag

The small intestine presented intact wall layering with 1:3 muscularis/mucosa ratio. The lumen of the small intestine was empty with no signs of ileus, obstruction or foreign material.

DATE

03/18/2022

Normal visible colon wall layers were present with apparent formed feces in lumen.



PATIENT *Pancreas*

Gemma Baran The parenchyma of the left limb, body and right limb of the pancreas presented isoechoic to the adjacent omental fat. A normal curvilinear capsule contour of the pancreas was present. The visible pancreatic duct was normal. No signs of active inflammation or neoplastic disease was evident.

SPECIES

Canine

ULTRASONOGRAPHIC FINDINGS

BREED

- Focal ventral urinary bladder polyp to focal polyploid cystitis.
- Sonographically unremarkable bilateral kidneys-no evidence of pyelonephritis.

Lab X

SEX

Spayed female

INTERPRETATION OF THE FINDINGS & FURTHER RECOMMENDATIONS

The focal ventral polyp was not suggestive of neoplastic criteria, regardless a screening BRAF assay would be warranted. If recurrent documented UTI based on C/S, this polyp could be serving as a nidus for recurrent infection. Recheck urine C/S on a sterile urine sample along with UA monitoring is recommended.

AGE

6 years

Conservatively a NSAID trial such as piroxicam as well as sonographic monitoring of the polyp for evidence of progression and assessment of cystitis sing response would be reasonable.

WEIGHT

65 pounds

INTERPRETED BY

R. McKenzie Daniel,
DVM, DABVP
(Canine and Feline)

IMAGING PERFORMED BY

Rebekah Jakum, CVT
ARDMS/RVT

HOSPITAL NAME

Littlestown Veterinary
Hospital

REFERRING VET

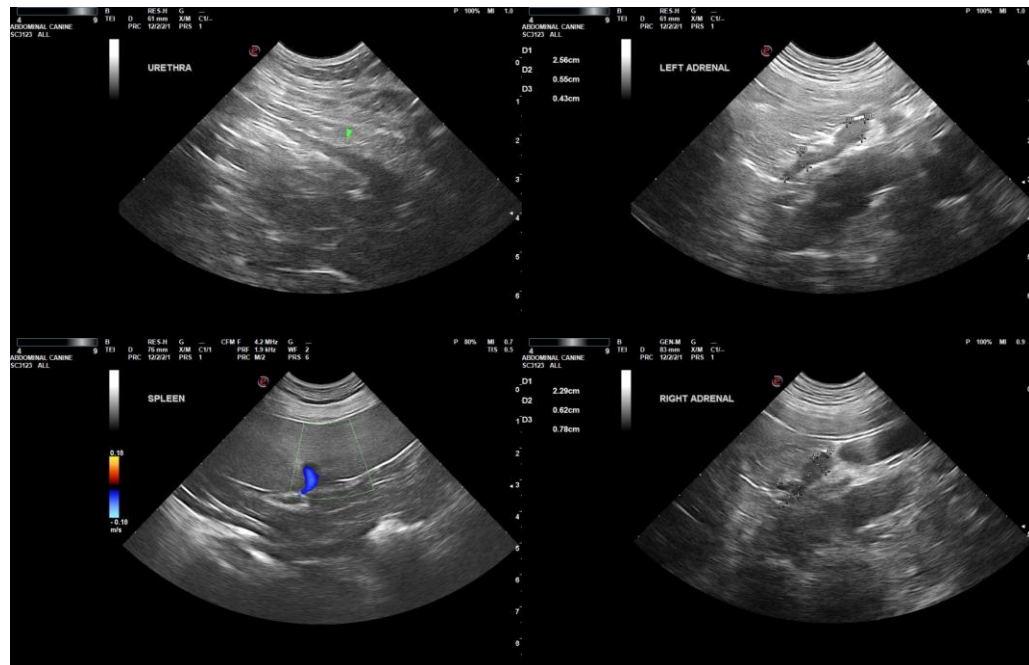
Dr. Jennings

INVOICE

10197ag

DATE

03/18/2022





PATIENT

Gemma Baran

SPECIES

Canine

BREED

Lab X

SEX

Spayed female

AGE

6 years

WEIGHT

65 pounds

INTERPRETED BY

R. McKenzie Daniel,
DVM, DABVP
(Canine and Feline)

IMAGING PERFORMED BY

Rebekah Jakum, CVT
ARDMS/RVT

HOSPITAL NAME

Littlestown Veterinary
Hospital

REFERRING VET

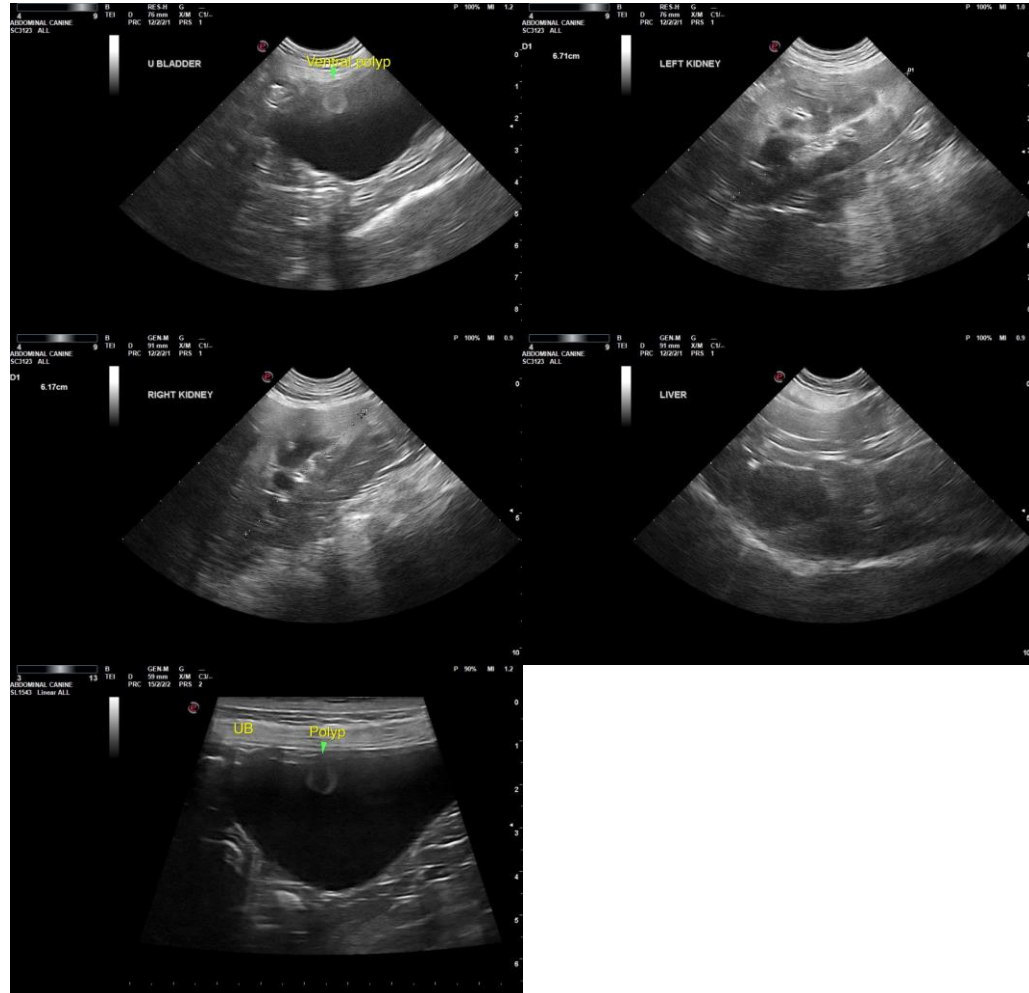
Dr. Jennings

INVOICE

10197ag

DATE

03/18/2022



The information and recommendations provided are based on the images presented by the referring veterinarian/sonographer. No evaluation can be communicated regarding pathology that was not visible in the image/video clips provided.

Thank you for this referral. If the clinical or image interpretation does not parallel your findings or if I can be of any further assistance please contact me.

R. McKenzie Daniel, DVM, DABVP (Canine / Feline Practice)

info@SonoPath.com