



## PATIENT

Rhett Butler Hermanek

## SPECIES

Canine

## BREED

Scottish Terrier

## SEX

Male Neutered

## AGE

8y 4m

## WEIGHT

8.8 kgs

## INTERPRETED BY

R. McKenzie Daniel,  
DVM, DABVP  
(Canine and Feline)

## IMAGING PERFORMED BY

Patti Mayfield, DVM

## HOSPITAL NAME

Ridgeview VC

## REFERRING VET

Caelli Edmonds, DVM

## INVOICE

13291

## DATE

3/17/26

## PRESENTING CLINICAL SIGNS

History:

- Polyuria/polydipsia
- Chronic liver enzyme elevation
- Prior ultrasound showing focal hepatic lesion (~2 cm)
- Newly identified severe proteinuria (UPC 11.1)
- Clinically stable (no vomiting/diarrhea)
- Medications / treatments: Denamarin (liver support), Gabapentin (pre-visit sedation)

Abnormal PE/Chem/CBC/UA Results: PE: Overweight, otherwise unremarkable Dx: Liver enzymes: - ALP: 2897 (markedly ↑) - ALT: 380 (↑) - GGT: 25 (↑) Lipid panel: - Cholesterol: 367 (↑) - Triglycerides: 254 (↑) - UPC: 11.1 (markedly ↑) - USG: 1.008 (isosthenuric) - BUN: low-normal - Creatinine & SDMA: normal - Precision PSL: 396 (↑) CBC: - Mild hemoconcentration (HCT 61%) - Mild neutrophilia LDDST (negative for Cushing's) Thyroid testing (normal) Precision PSL (elevated) Abdominal ultrasound: ~2 cm region of altered hepatic echogenicity - 0.5 cm hyperechoic focus within lesion - Otherwise unremarkable

## ULTRASONOGRAPHIC EXAMINATION OF THE ABDOMEN

### Urinary System

The urinary bladder, trigone, cystourethral junction, and visible pelvic urethra exhibited normal thickness and tone. Anechoic urine was present in the lumen with no uroliths or sediment. The ureteral papillae were normal. The ureters were not visible which is normal. No evidence of inflammatory or neoplastic changes were noted.

Normal size and margination was present in the kidneys. A normal 1:3 cortex / medulla ratio and normal corticomedullary definition were maintained. The echogenicity of the cortex was similar to or slightly less than normal liver parenchyma while the medulla echogenicity was hypoechoic to the cortex. Emerging areas of medullary mineral noted. The left kidney exhibited minor pyelectasia. The left kidney measured 5.6 cm in length. The right kidney measured 5.1 cm in length.

### Adrenal Glands

Bilateral mild, symmetrical adrenal gland enlargement with uniformly hypoechoic parenchyma was present. The left adrenal gland measured 0.72 cm width at the caudal pole. The right adrenal gland measured 0.70 cm width at the caudal pole.

### Spleen

The spleen exhibited a finely textured and homogenous parenchyma which was hyperechoic to the liver and renal cortical parenchyma. The capsule was smooth and regular without apparent expansion. The splenic vasculature at the hilus was normal in volume with no evidence of congestion or thrombosis. Acute to chronic inflammatory, neoplastic, or benign parenchyma changes were not noted.

### Liver

The liver exhibited generalized hepatomegaly. The parenchyma of the liver was subjectively normal in echogenicity compared to the spleen and renal cortices. The liver parenchyma was uniform with a



## PATIENT

Rhett Butler Hermanek

## SPECIES

Canine

## BREED

Scottish Terrier

## SEX

Male Neutered

## AGE

8y 4m

## WEIGHT

8.8 kgs

## INTERPRETED BY

R. McKenzie Daniel,  
DVM, DABVP  
(Canine and Feline)

## IMAGING PERFORMED BY

Patti Mayfield, DVM

## HOSPITAL NAME

Ridgeview VC

## REFERRING VET

Caelli Edmonds, DVM

## INVOICE

13291

## DATE

3/17/26

mildly coarse echotexture. The capsule of the liver was symmetrically rounded to mildly swollen in margination. The hepatic and portal vasculature were normal in appearance without signs of congestion. Mildly expansive non-homogeneous ventral caudal intraparenchymal nodule with mild associated capsule distortion was present measuring 2.3 cm in diameter. A separate, indistinctly marginated, isoechoic macronodular lesion in the right liver with intralesion hyperechoic nodule measuring ~3.9 cm in diameter. The hyperechoic intralesion nodule measured 0.94 cm in diameter. The gallbladder was non distended in size with mild, non-organized, echogenic, nonmineralized biliary sludge. The cystic duct and common bile ducts were normal without evidence of dilation.

### ***Gastrointestinal***

The stomach presented intact wall layering with a normal wall layer ratio. The lumen of the stomach contained mild, echogenic, non-shadowing ingesta without signs of obstruction or foreign material.

The small intestine presented intact wall layering with 1:3 muscularis/mucosa ratio. The lumen of the small intestine exhibited similar appearing non-shadowing ingesta.

Normal visible colon wall layers were present with apparent formed feces in lumen.

### ***Pancreas***

The parenchyma of the left limb, body and right limb of the pancreas presented isoechoic to the adjacent omental fat. A normal curvilinear capsule contour of the pancreas was present. The visible pancreatic duct was normal. No signs of active inflammation or neoplastic disease was evident.

### ***Free Abdomen***

No overt lymphadenopathy or peritoneal effusion was present.

## **ULTRASONOGRAPHIC FINDINGS**

- Hepatopathy with ventral caudal and right liver intraparenchymal nodular to macronodular lesions
- Mild gallbladder debris (non-mucocele) minor right kidney pyelectasia
- Bilateral mild adrenomegaly
- Gastrointestinal ingesta - consistent with food echogenicity
- Sonographically normal pancreas

## **INTERPRETATION OF THE FINDINGS & FURTHER RECOMMENDATIONS**

The overall liver and parenchymal nodular lesions may indicate vacuolar, or breed associated vacuolar hepatopathy, inflammatory disease, hyperplasia, granulomas, neoplasia or combination. Further assessment may include, assuming normal clotting status, hepatic parenchyma and nodular lesion FNA cytology. The bilateral mild adrenomegaly is of unclear clinical significance given negative adrenal testing. Recheck adrenal testing could be considered if continued progressive clinical signs which may suggest adrenal disease. ON overt adrenal neoplastic criteria. Empirical therapy for significant proteinuria with monitoring of systemic BP indicated if persistent significant elevated UPC. No evidence of active pancreatitis, although low-grade or chronic pancreatitis may present sonographically normal and may be considered if concurrent clinical signs. Hepato-supportive medications may prove beneficial.



**PATIENT**

Rhett Butler Hermanek

**SPECIES**

Canine

**BREED**

Scottish Terrier

**SEX**

Male Neutered

**AGE**

8y 4m

**WEIGHT**

8.8 kgs

**INTERPRETED BY**

R. McKenzie Daniel,  
DVM, DABVP  
(Canine and Feline)

**IMAGING PERFORMED BY**

Patti Mayfield, DVM

**HOSPITAL NAME**

Ridgeview VC

**REFERRING VET**

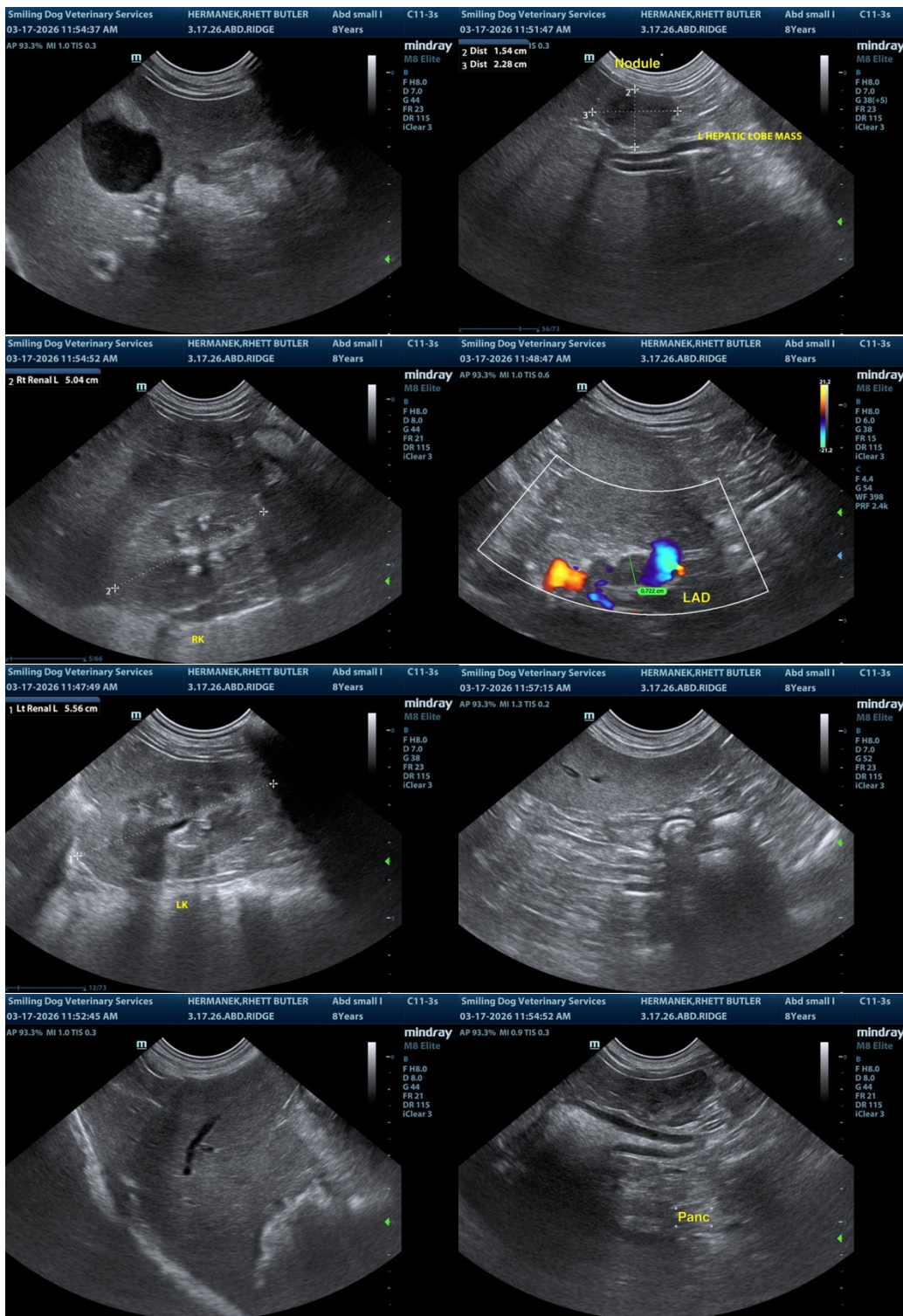
Caelli Edmonds, DVM

**INVOICE**

13291

**DATE**

3/17/26





#### PATIENT

Rhett Butler Hermanek

#### SPECIES

Canine

#### BREED

Scottish Terrier

#### SEX

Male Neutered

#### AGE

8y 4m

#### WEIGHT

8.8 kgs

#### INTERPRETED BY

R. McKenzie Daniel,  
DVM, DABVP  
(Canine and Feline)

#### IMAGING PERFORMED BY

Patti Mayfield, DVM

#### HOSPITAL NAME

Ridgeview VC

#### REFERRING VET

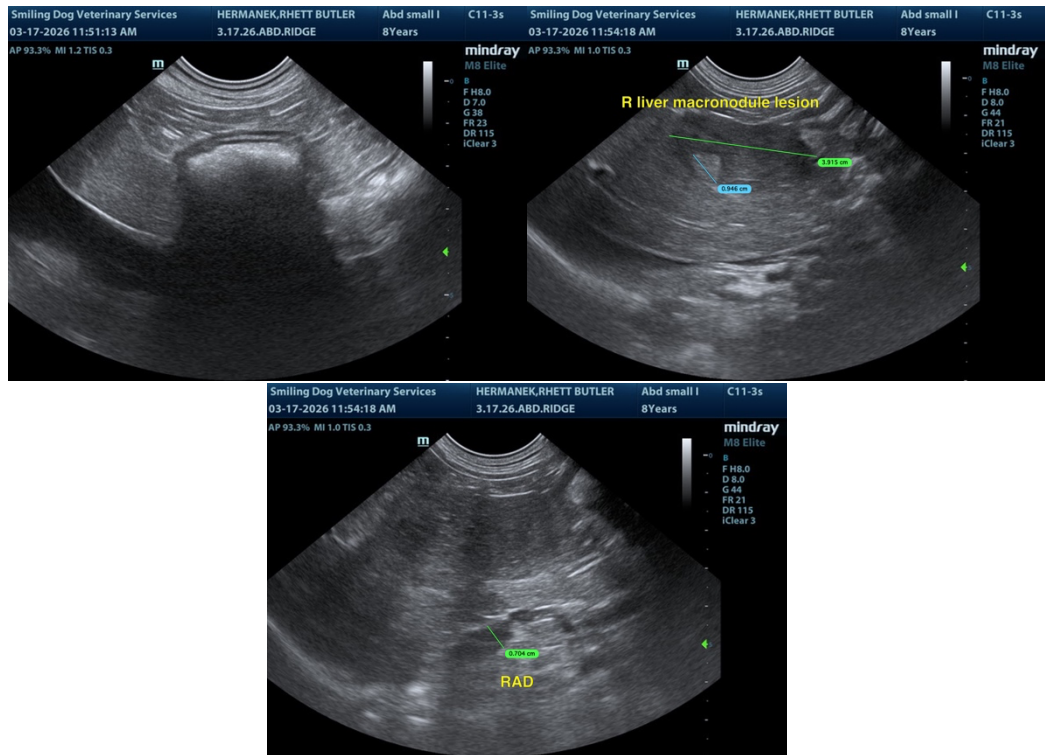
Caelli Edmonds, DVM

#### INVOICE

13291

#### DATE

3/17/26



The information and recommendations provided are based on the images presented by the referring veterinarian/sonographer. No evaluation can be communicated regarding pathology that was not visible in the image/video clips provided.

Thank you for this referral. If the clinical or image interpretation does not parallel your findings or if I can be of any further assistance, please contact me.

R. McKenzie Daniel, DVM, DABVP (Canine / Feline Practice)

[info@sonopath.com](mailto:info@sonopath.com)