



PATIENT

Paisley Wilson

SPECIES

Canine

BREED

Aussie

SEX

Spayed Female

AGE

7

WEIGHT

14

INTERPRETED BY

R. McKenzie Daniel,
DVM, DABVP (Canine
/ Feline Practice)

IMAGING PERFORMED BY

Jenn

HOSPITAL NAME

Rockaway Animal
Hospital

REFERRING VET

Dr. Maniar

INVOICE

14367

DATE

03/17/26

PRESENTING CLINICAL SIGNS

- severe HGE

Abnormal PE/Chem/CBC/UA Results: TLI > 50 Lipase 3/2 1445 3/17 956

ULTRASONOGRAPHIC EXAMINATION OF THE ABDOMEN

Urinary System

The urinary bladder, trigone, cystourethral junction, and visible pelvic urethra exhibited normal thickness and tone. Anechoic urine was present in the lumen with no uroliths or sediment. The ureteral papillae were normal. The ureters were not visible which is normal. No evidence of inflammatory or neoplastic change were noted.

Normal size and margination was present in the kidneys. A normal 1:3 cortex / medulla ratio and normal corticomedullary definition were maintained. The echogenicity of the cortex was similar to or slightly less than normal liver parenchyma while the medulla echogenicity was hypoechoic to the cortex with no evidence of pelvic dilation. The left kidney measured 4.5 cm in length. The right kidney measured 4.0 cm in length.

Adrenal Glands

The left adrenal gland was uniform in size and contour with a uniformly hypoechoic parenchyma. The left adrenal gland measured 0.58 cm width at the caudal pole.

The right adrenal gland was uniform in size and contour with a uniformly hypoechoic parenchyma. The right adrenal gland measured 0.53 cm width at the caudal pole.

Spleen

The spleen exhibited a finely textured and homogenous parenchyma which was hyperechoic to the liver and renal cortical parenchyma. The capsule was smooth and regular without apparent expansion. The splenic vasculature at the hilus was normal in volume with no evidence of congestion or thrombosis. Acute to chronic inflammatory, neoplastic, or benign parenchyma changes were not noted.

Liver & Gallbladder

The liver was subjectively normal in size, structure, and contour. The liver parenchyma was uniform and hypoechoic to the spleen with a mild coarse echotexture. The hepatic and portal vasculature were normal in appearance without signs of congestion.

The gallbladder was non-distended in size with thin walls and primarily anechoic luminal content. The cystic and common bile ducts were normal.

Gastrointestinal

The stomach presented intact wall layering with a normal wall layer ratio. The lumen of the stomach contained mildly retained anechoic to mildly echogenic fluid and lumen gas.

The small intestine presented intact wall layering with 1:3 muscularis/mucosa ratio. The lumen of the small intestine was empty with no signs of ileus, obstruction or foreign material.



PATIENT

Paisley Wilson

SPECIES

Canine

BREED

Aussie

SEX

Spayed Female

AGE

7

WEIGHT

14

INTERPRETED BY

R. McKenzie Daniel,
DVM, DABVP (Canine
/ Feline Practice)

**IMAGING
PERFORMED BY**

Jenn

HOSPITAL NAME

Rockaway Animal
Hospital

REFERRING VET

Dr. Maniar

INVOICE

14367

DATE

03/17/26

The descending colon walls presented intact yet mild thickened wall layering. The descending colon was empty with nonformed fecal matter in the proximal colon.

Pancreas

The area of the pancreas was sonographically normal.

Free Abdomen

No overt lymphadenopathy or peritoneal effusion was present.

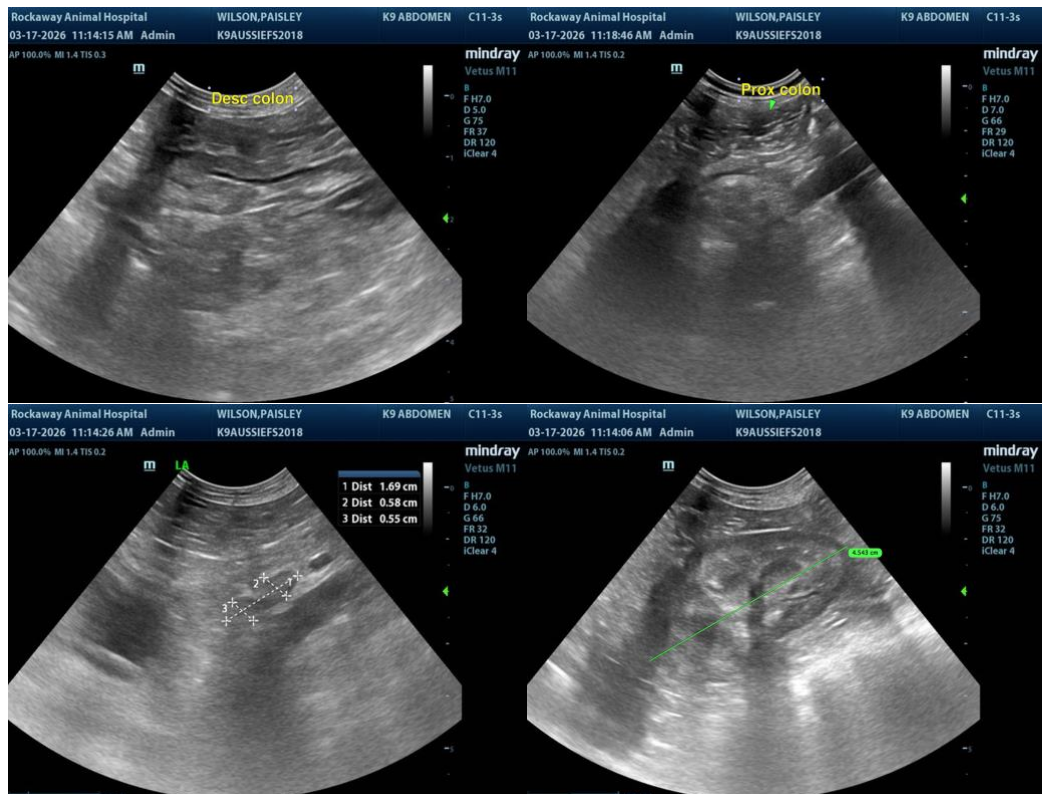
ULTRASONOGRAPHIC FINDINGS

- Sonographically unremarkable gastrointestinal tract with persistent mild hypomotile stomach.
- Persistent mild colitis pattern with nonformed fecal matter in the proximal colon.
- Normal area of the pancreas.

INTERPRETATION OF THE FINDINGS & FURTHER RECOMMENDATIONS

Correlation with the current clinical and gastrointestinal signs is recommended. Persistent mild pancreatitis may present sonographically normal and may be suspected of cranial abdomen/subxiphoid discomfort on palpation.

Continue as needed gastrointestinal support and empirical therapy for hemorrhagic gastroenteritis and pancreatitis would be reasonable with clinical monitoring. Sonographic monitoring or recheck is indicated if persistent or progressive gastrointestinal signs.





PATIENT

Paisley Wilson

SPECIES

Canine

BREED

Aussie

SEX

Spayed Female

AGE

7

WEIGHT

14

INTERPRETED BY

R. McKenzie Daniel, DVM, DABVP (Canine / Feline Practice)

IMAGING PERFORMED BY

Jenn

HOSPITAL NAME

Rockaway Animal Hospital

REFERRING VET

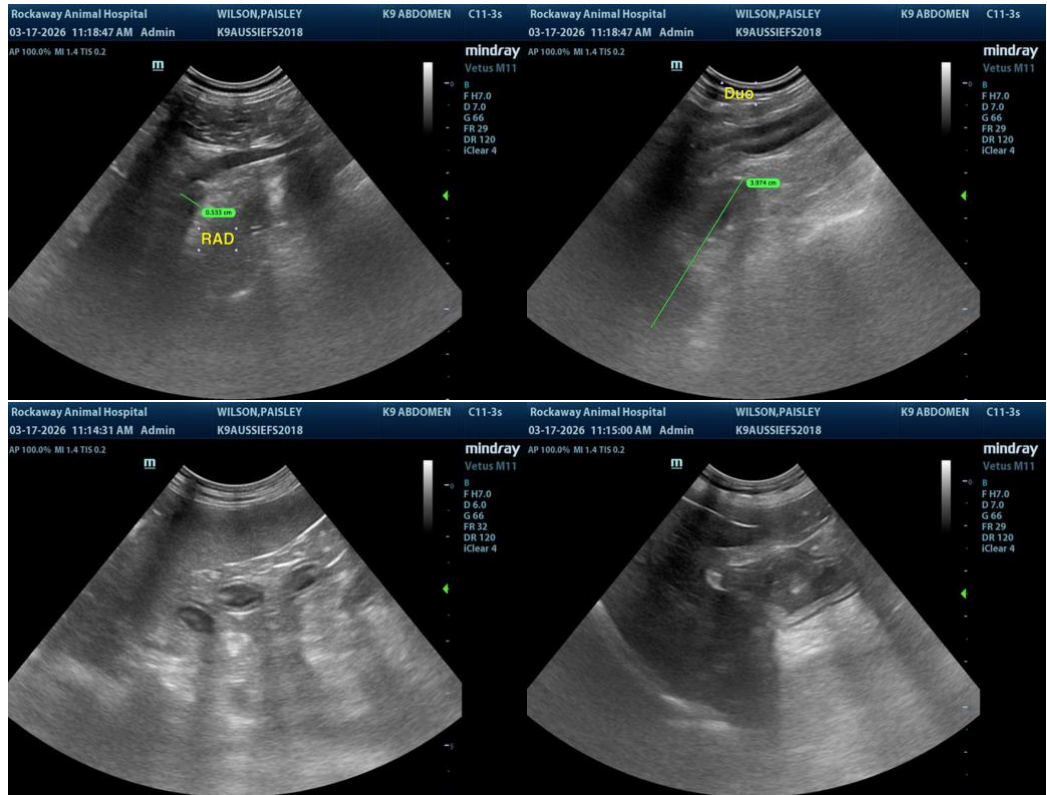
Dr. Maniar

INVOICE

14367

DATE

03/17/26



The information and recommendations provided are based on the images presented by the referring veterinarian/sonographer. No evaluation can be communicated regarding pathology that was not visible in the image/video clips provided.

Thank you for this referral. If the clinical or image interpretation does not parallel your findings or if I can be of any further assistance, please contact me.

R. McKenzie Daniel, DVM, DABVP (Canine / Feline Practice)

info@SonoPath.com