



PATIENT

Fritz Short-Lyons

SPECIES

Canine

BREED

Poodle Mix

SEX

Male Neutered

AGE

9y

WEIGHT

14.2

INTERPRETED BY

R. McKenzie Daniel,
DVM, DABVP
(Canine and Feline)

IMAGING PERFORMED BY

Dr. Csrlos Abdul-Chani

HOSPITAL NAME

Byram AH

REFERRING VET

Dr. Maria Cruz

INVOICE

13824

DATE

3/17/26

PRESENTING CLINICAL SIGNS

History:

- Heart murmur
- Infrequent cough
- PU/PD
- Current meds- Furosemide 12.5mg 1 BID

Abnormal PE/Chem/CBC/UA Results: Abnormal CBC/ Chem findings- results not in yet Urine- not done

ULTRASONOGRAPHIC EXAMINATION OF THE CARD

CANINE CARDIAC PARAMETERS	MR VMAX (m/s)	TR VMAX (m/s)	LA/AO (M-Mode)	LA/AO (Heart Base; Swe)	FS (%)	EF (%)	EPSS (cm)
NORMAL PARAMETER	4.5-5.5	<2.7	1.3	Up to 1.6	28-40	40-100	<0.6
PATIENT	--	--	--	1.45	46	80	0.2
CANINE CARDIAC PARAMETERS	HR (BPM)	AV VMAX (m/s)	PV MAX (m/s)	BODY WEIGHT (kg)	LAD LA MAX 4 Chamber	LVIDd Avg; 2D and m-mode short axis (cm)	LVIDs Avg; 2D and m-mode short axis (cm)
NORMAL PARAMETER	50-100	0.7-1.7	0.7-1.6				
PATIENT	NM	1.0	0.9	--	2.7	2.5	--

Cardiac Presentation

The echocardiogram in this patient demonstrated normal **left atrial** size based on 2 different LA measurement methods. The cranial and caudal **mitral** valve leaflets presented thickening consistent with endocardiosis. Doppler indicated mild to moderate eccentric insufficiency. The **left ventricle** presented thicknesses with linear contour and was not dilated nor restricted. The **myocardium** presented normal echogenicity without subjective evidence of significant fibrotic or ischemic disease. **Contractility** of the ventricular walls was adequate and in normal range for this patient evidenced by the fractional shortening measurement and subjective evaluation of the different regions of the myocardium. The **left ventricular outflow** tract demonstrated normal laminar flow and subjective structural integrity. The **right atrium** and auricle revealed normal size, structure and content. No evidence of masses was noted or chamber overload. **Tricuspid** valvular assessment demonstrated adequate linear morphology. The **right ventricle** was of normal size (1/3 diameter of LV), chordae structure, myocardial echogenicity and thickness. **Pulmonic** tract assessment revealed normal valve



PATIENT

Fritz Short-Lyons

SPECIES

Canine

BREED

Poodle Mix

SEX

Male Neutered

AGE

9y

WEIGHT

14.2

INTERPRETED BY

R. McKenzie Daniel,
DVM, DABVP
(Canine and Feline)

IMAGING PERFORMED BY

Dr. Csrlos Abdul-Chani

HOSPITAL NAME

Byram AH

REFERRING VET

Dr. Maria Cruz

INVOICE

13824

DATE

3/17/26

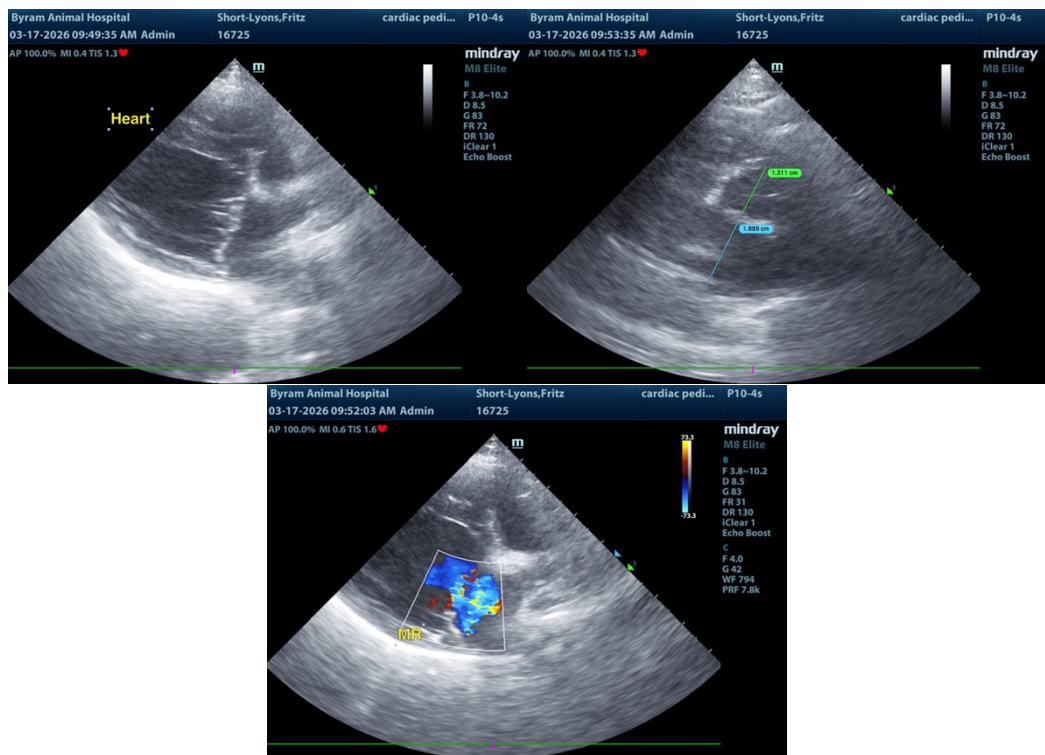
structure, laminar flow, and diameter (approx.1:1 pa/ao ratio). No visible pericardial or free pleura fluid was noted. No echographically detectable evidence of cardiac / pericardial tumors was visible.

ULTRASONOGRAPHIC FINDINGS

- Chronic mitral valve disease (B1)

INTERPRETATION OF THE FINDINGS & FURTHER RECOMMENDATIONS

The cause of the murmur is chronic degenerative valvular changes with secondary eccentric mitral valve insufficiency. The lack of left atrial enlargement implies that the risk of complication secondary to mitral valve insufficiency is low at this time and, without current clinical signs, indicates that medical therapy is not required. Prognosis is considered variable and sonographic monitoring is recommended. Recheck echo cardiogram is suggested in 6-12 months, sooner if clinical signs arise. Anesthetic risk is considered low to mild. Suggested anesthetic protocol may include opioid or Benzodiazepine pre-med, induction with Propofol or Alfaxalone, and appropriate gas anesthesia with avoidance of alpha 2 agonists.





PATIENT

Fritz Short-Lyons

SPECIES

Canine

BREED

Poodle Mix

SEX

Male Neutered

AGE

9y

WEIGHT

14.2

INTERPRETED BY

R. McKenzie Daniel,
DVM, DABVP
(Canine and Feline)

IMAGING PERFORMED BY

Dr. Csrlos Abdul-Chani

HOSPITAL NAME

Byram AH

REFERRING VET

Dr. Maria Cruz

INVOICE

13824

DATE

3/17/26

The information and recommendations provided are based on the images presented by the referring veterinarian/sonographer. No evaluation can be communicated regarding pathology that was not visible in the image/video clips provided.

Thank you for this referral. If the clinical or image interpretation does not parallel your findings or if I can be of any further assistance, please contact me.

R. McKenzie Daniel, DVM, DABVP (Canine / Feline Practice)

info@sonopath.com