



## PATIENT

Abby Eroh

## SPECIES

Canine

## BREED

Scottish Terrier

## SEX

FS

## AGE

6 years

## WEIGHT

23.8 lbs.

## INTERPRETED BY

R. McKenzie Daniel,  
DVM, DABVP  
(Canine and Feline)

## IMAGING PERFORMED BY

Chloe Lowe, CVT

## HOSPITAL NAME

Nazareth VC

## REFERRING VET

Dr. Bankowski

## INVOICE

10381

## DATE

3/17/26

## PRESENTING CLINICAL SIGNS

### History:

- elevated liver enzymes
- dental disease
- asymptomatic

Abnormal PE/Chem/CBC/UA Results: ALT 163, ALP 407 No full Chem

## ULTRASONOGRAPHIC EXAMINATION OF THE ABDOMEN

### *Urinary System*

The urinary bladder, trigone, cystourethral junction, and visible pelvic urethra to a depth of 3.0 cm exhibited normal thickness and tone. Anechoic urine was present in the lumen with no uroliths or sediment. The ureteral papillae were normal. The ureters were not visible which is normal. No evidence of inflammatory or neoplastic changes were noted.

The area of the iliac trifurcation was free of pathology.

Normal size and margination were present in the kidneys. A normal 1:3 cortex / medulla ratio and normal corticomedullary definition were maintained. The echogenicity of the cortex was similar to or slightly less than normal liver parenchyma while the medulla echogenicity was hypoechoic to the cortex with no evidence of pelvic dilation. The left kidney measured 4.8 cm in length. The right kidney measured 4.7 cm in length.

### *Adrenal Glands*

The left adrenal gland was uniform in size and contour with a uniformly hypoechoic parenchyma. The left adrenal gland measured 0.35 cm width at the caudal pole. The right adrenal gland was uniform in size and contour with a uniformly hypoechoic parenchyma. The right adrenal gland measured 0.41 cm width at the caudal pole.

### *Spleen*

The spleen exhibited a finely textured and homogenous parenchyma which was hyperechoic to the liver and renal cortical parenchyma. The capsule was smooth and regular without apparent expansion. The splenic vasculature at the hilus was normal in volume with no evidence of congestion or thrombosis. Acute to chronic inflammatory, neoplastic, or benign parenchyma changes were not noted.

### *Liver/ Gallbladder*

The liver presented subjective borderline mild hepatomegaly. The parenchyma of the liver was subjectively normal in echogenicity compared to the spleen and renal cortices. The liver parenchyma was uniform with a mildly coarse echotexture. The capsule of the liver was symmetrically rounded to mildly swollen in margination. The hepatic and portal vasculature were normal in appearance without signs of congestion. The gallbladder was non-distended in size with thin walls and primarily anechoic luminal content. The cystic and common bile ducts were normal.



**PATIENT**

Abby Eroh

**SPECIES**

Canine

**BREED**

Scottish Terrier

**SEX**

FS

**AGE**

6 years

**WEIGHT**

23.8 lbs.

**INTERPRETED BY**

R. McKenzie Daniel,  
DVM, DABVP  
(Canine and Feline)

**IMAGING PERFORMED BY**

Chloe Lowe, CVT

**HOSPITAL NAME**

Nazareth VC

**REFERRING VET**

Dr. Bankowski

**INVOICE**

10381

**DATE**

3/17/26

***Gastrointestinal***

The stomach presented intact wall layering with a normal wall layer ratio. The lumen of the stomach was empty without evidence of retained ingesta, fluid, or foreign material.

The small intestine presented intact wall layering with 1:3 muscularis/mucosa ratio. The lumen of the small intestine was empty with no signs of ileus, obstruction, or foreign material.

Normal visible colon wall layers were present with formed feces in lumen.

***Pancreas***

The parenchyma of the left limb, body, and right limb of the pancreas presented isoechoic to the adjacent omental fat. A normal curvilinear capsule contour of the pancreas was present. The visible pancreatic duct was normal. No signs of active inflammation or neoplastic disease were evident.

***Free Abdomen***

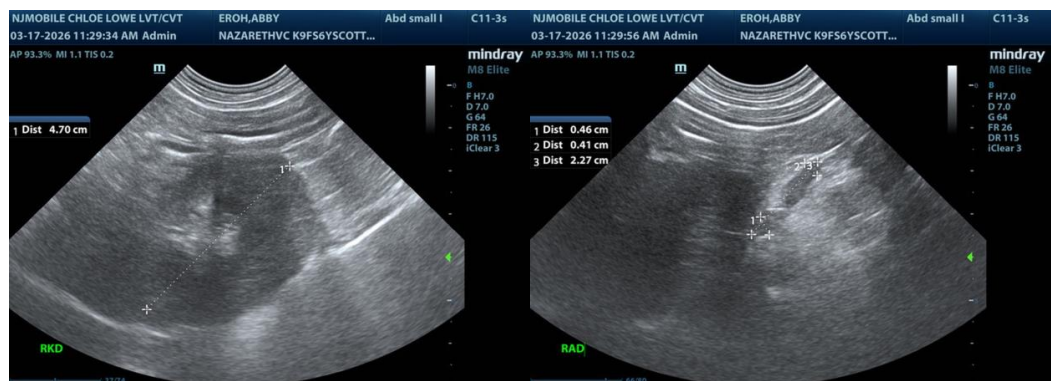
No overt lymphadenopathy or peritoneal effusion was present.

**ULTRASONOGRAPHIC FINDINGS**

- Hepatopathy
- Normal gallbladder
- Normal bilateral adrenal glands

**INTERPRETATION OF THE FINDINGS & FURTHER RECOMMENDATIONS**

Hepatopathy most consistent with benign criteria with considerations including idiopathic or breed-associated vacuolar hepatopathy, inflammatory disease, nonobstructive cholestasis, or other, without evidence of neoplastic criteria. Given that the patient is nonclinical, hepatosupportive medications including Denamarin and Ursodiol, if tolerated, may prove beneficial with clinical monitoring. Hepatic sampling or biopsy required for further clarification and may be considered if evidence of progressive hepatopathy.





**PATIENT**

Abby Eroh

**SPECIES**

Canine

**BREED**

Scottish Terrier

**SEX**

FS

**AGE**

6 years

**WEIGHT**

23.8 lbs.

**INTERPRETED BY**

R. McKenzie Daniel,  
 DVM, DABVP  
 (Canine and Feline)

**IMAGING PERFORMED BY**

Chloe Lowe, CVT

**HOSPITAL NAME**

Nazareth VC

**REFERRING VET**

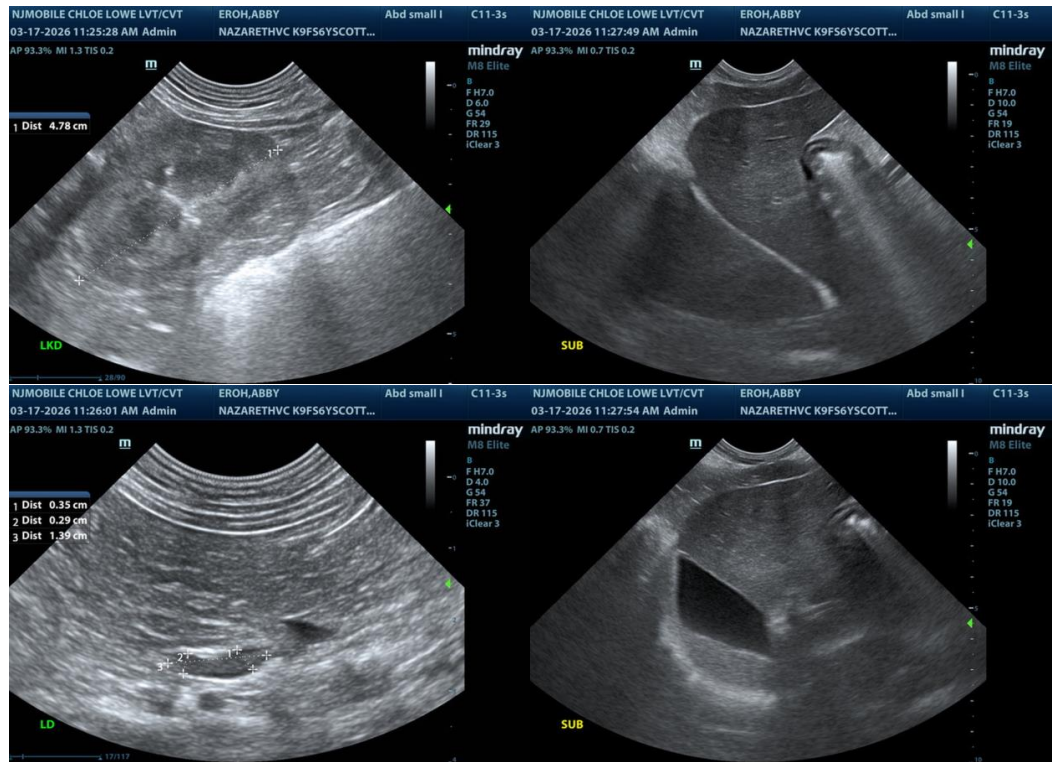
Dr. Bankowski

**INVOICE**

10381

**DATE**

3/17/26



The information and recommendations provided are based on the images presented by the referring veterinarian/sonographer. No evaluation can be communicated regarding pathology that was not visible in the image/video clips provided.

Thank you for this referral. If the clinical or image interpretation does not parallel your findings or if I can be of any further assistance, please contact me.

R. McKenzie Daniel, DVM, DABVP (Canine/Feline Practice)  
[info@sonopath.com](mailto:info@sonopath.com)