



**PATIENT**

Frankie Tretheway

**SPECIES**

Canine

**BREED**

Beagle

**SEX**

FS

**AGE**

13 years

**WEIGHT**

15.8 lbs.

**PRESENTING CLINICAL SIGNS**

Presented on 3/7/22 for not eating or drinking. 3/13/22 Symptoms improved while on antibiotics, but straining to defecate and dribbles while urinating. Frankie as passed huge blood clots.

Abnormal PE/Chem/CBC/UA Results: Urinalysis shows bacteria in urine.

**ULTRASONOGRAPHIC EXAMINATION OF THE URINARY BLADDER**

**Urinary Bladder**

The overall urinary bladder was subnormal in size owing to lack of urine distention. Potential mild to variable thickening of the ventral and dorsal urinary bladder walls was noted. A sessile based mass with asymmetrical margination was present and measured approximately 2.8 cm x 1.6 cm. The parenchyma of the mass was heterogeneous with focal echogenic foci and mineralization. Color flow doppler evaluation of the mass confirmed blood flow within the mass. The urethra was normal in structure and tone to a depth of 2.0 cm. Anechoic urine was present in the lumen with no uroliths, sediment, or calculi. The ureteral papillae were normal. The ureters were not visible which is normal. The ventral trigone wall measured 0.3 cm width. No overt evidence of regional inflammation around the urinary bladder was noted.

**ULTRASONOGRAPHIC FINDINGS**

**Primary Findings**

- Urinary bladder mass - consistent with neoplastic criteria, transitional cell carcinoma likely until prove otherwise

**INTERPRETED BY**

R. McKenzie Daniel,  
DVM, DABVP  
(Canine and Feline)

**INTERPRETATION OF THE FINDINGS & FURTHER RECOMMENDATIONS**

Screening BRAF Assay and / or cytospin cytology of a free catch urine sample may be considered. The mass does not appear amendable to surgical resection based on its size, as well as the potential for generalized urinary bladder involvement.

**IMAGING PERFORMED BY**

Kim Liedberg

**HOSPITAL NAME**

SVS Imaging WI

**REFERRING VET**

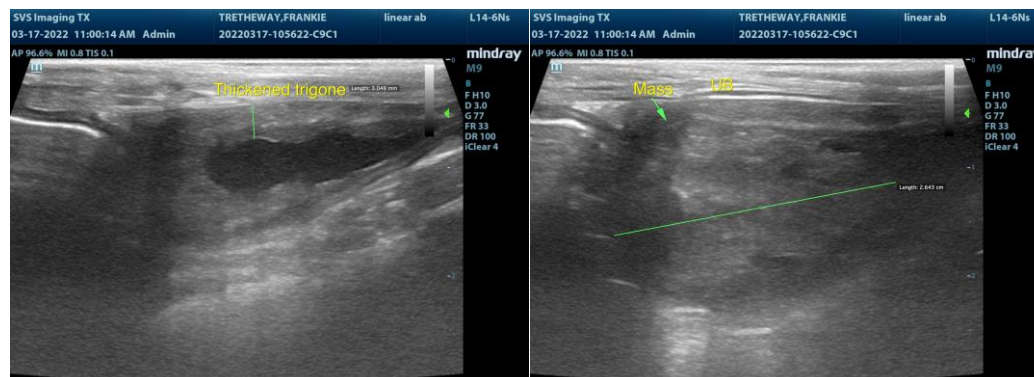
Dr Hoffman,  
Germantown AH

**INVOICE**

13514

**DATE**

3/17/22





**PATIENT**

Frankie Tretheway

**SPECIES**

Canine

**BREED**

Beagle

**SEX**

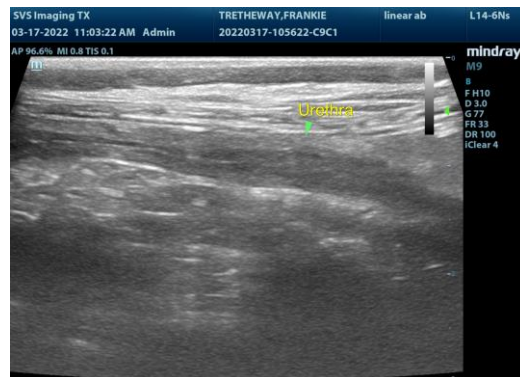FS

**AGE**

13 years

**WEIGHT**

15.8 lbs.



The information and recommendations provided are based on the images presented by the referring veterinarian/sonographer. No evaluation can be communicated regarding pathology that was not visible in the image/video clips provided.

Thank you for this referral. If the clinical or image interpretation does not parallel your findings or if I can be of any further assistance please contact me.

**INTERPRETED BY**

R. McKenzie Daniel,  
DVM, DABVP  
(Canine and Feline)

**R. McKenzie Daniel, DVM, DABVP (Canine / Feline Practice)**  
info@SonoPath.com

**IMAGING PERFORMED BY**

Kim Liedberg

**HOSPITAL NAME**

SVS Imaging WI

**REFERRING VET**

Dr Hoffman,  
Germantown AH

**INVOICE**

13514

**DATE**

3/17/22