



PATIENT

Riley Cameron

SPECIES

Canine

BREED

Jack Russell

SEX

Spayed female

AGE

13 years

WEIGHT

13.6 pounds

INTERPRETED BY

R. McKenzie Daniel,
DVM, DABVP
(Canine and Feline)

**IMAGING
PERFORMED BY**
CH

HOSPITAL NAME

Columbia Animal
Clinic

REFERRING VET

Dr. Michelle Engel

INVOICE

10186ag

DATE

03/16/2022

PRESENTING CLINICAL SIGNS

History: Appetite has increased at home (eating normally but seems always hungry) and losing weight. Last labwork was WNL.

ULTRASONOGRAPHIC EXAMINATION OF THE ABDOMEN

Urinary System

The urinary bladder, trigone, cystourethral junction, and visible pelvic urethra to a depth of 3 cm exhibited normal thickness and tone. Anechoic urine was present in the lumen with no uroliths or sediment. The ureteral papillae were normal. The ureters were not visible which is normal. No evidence of inflammatory or neoplastic changes were noted.

Normal size and margination was present in the kidneys. A normal 1:3 cortex / medulla ratio was maintained. The medulla and cortices were uniform in texture with some moderately increased echogenicity and moderate loss of corticomedullary symmetry and definition expected for the age of the patient. No evidence of pelvic dilation was present. The left kidney measured 4.2 cm in length. The right kidney measured 4.0 cm in length.

The area of the aortic trifurcation was free of pathology.

Adrenal Glands

The left adrenal gland was uniform in size and contour with a uniformly hypoechoic parenchyma. The left adrenal gland measured 0.55 cm width at the caudal pole and 0.55 cm width at the cranial pole. The right adrenal gland was uniform in size and contour with a uniformly hypoechoic parenchyma. The right adrenal gland measured 0.54 cm width at the caudal pole and 0.46 cm width at the cranial pole.

Spleen

The spleen exhibited primarily finely textured parenchyma which was hyperechoic to the liver and renal cortical parenchyma. Mild generalized parenchyma heterogeneity was present without evidence of nodular changes. The capsule was smooth and regular without apparent expansion. The splenic vasculature at the hilus was normal in volume with no evidence of congestion or thrombosis. The parenchymal heterogeneity is likely consistent with benign changes such as extramedullary hematopoiesis or age-related remodeling with minor potential for inflammatory or neoplastic disease.

Liver

The liver was subjectively normal in size, structure, and contour. The liver parenchyma was uniform and hypoechoic to the spleen with a mild coarse echotexture. The hepatic and portal vasculature were normal in appearance without signs of congestion. The gallbladder was non-distended in size with thin walls and mild gallbladder debris. The cystic and common bile ducts were normal.

Gastrointestinal

The stomach presented intact wall layering with a normal wall layer ratio. The lumen of the stomach contained moderate ingesta exhibiting subtle progressive distal acoustic shadowing. The visualized gastric walls were sonographically normal. The gastric body wall measured 0.38 cm.

The small intestine presented intact wall layering with 1:3 muscularis/mucosa ratio. The lumen of the small intestine contained echogenic, nonshadowing ingesta consistent with normal food without signs



PATIENT

Riley Cameron

of ileus, obstruction or foreign material. The jejunum wall measured 0.25 cm. The duodenum wall measured 0.45 cm.

Normal visible colon wall layers were present with apparent formed feces in lumen.

SPECIES

Canine

Pancreas

The pancreas was normal in size and contour with isoechoic to heterogeneous parenchyma compared to adjacent omentum. No signs of active inflammation or neoplasia.

BREED

Jack Russell

Free Abdomen

No overt lymphadenopathy or peritoneal effusion was present.

SEX

Spayed female

ULTRASONOGRAPHIC FINDINGS

AGE

13 years

- Moderate chronic renal changes.
- Overtly normal gastrointestinal tract with gastrointestinal ingesta/chyme.
- Minor pancreatic remodeling-likely consistent with age related pancreatic changes considered incidental, no evidence of active pancreatic inflammation.
- Moderate gallbladder debris (non mucocele)-likely incidental if no evidence of cholestasis.

WEIGHT

13.6 pounds

INTERPRETATION OF THE FINDINGS & FURTHER RECOMMENDATIONS

Largely geriatric abdomen without evidence of overt visceral pathology as an obvious cause of the patient's weight loss.

INTERPRETED BY

R. McKenzie Daniel,
DVM, DABVP
(Canine and Feline)

A GI panel to include PLI/TLI/Cobalamin/Folate is recommended to assess for underlying nonstructural gastrointestinal disease or maldigestion disorder.

Three view chest radiographs are also suggested to rule out occult thoracic pathology. Depending on date of last lab work, correlation with recheck lab work may be considered.

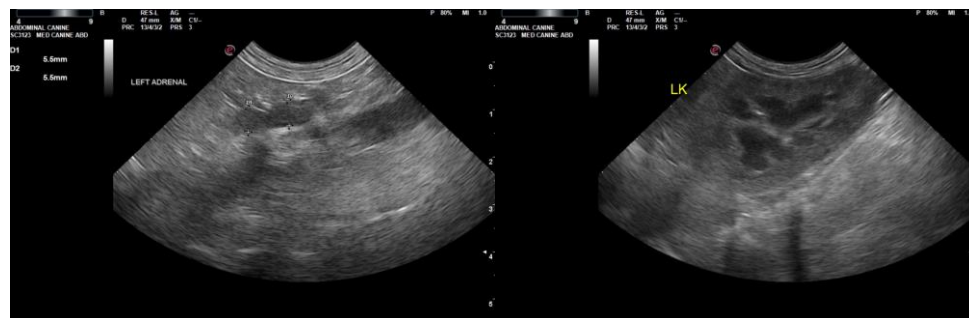IMAGING PERFORMED BY
CH

HOSPITAL NAME

Columbia Animal
Clinic

REFERRING VET

Dr. Michelle Engel



INVOICE

10186ag

DATE

03/16/2022



PATIENT

Riley Cameron

SPECIES

Canine

BREED

Jack Russell

SEX

Spayed female

AGE

13 years

WEIGHT

13.6 pounds

INTERPRETED BY

R. McKenzie Daniel,
DVM, DABVP
(Canine and Feline)

**IMAGING
PERFORMED BY**
CH

HOSPITAL NAME

Columbia Animal
Clinic

REFERRING VET

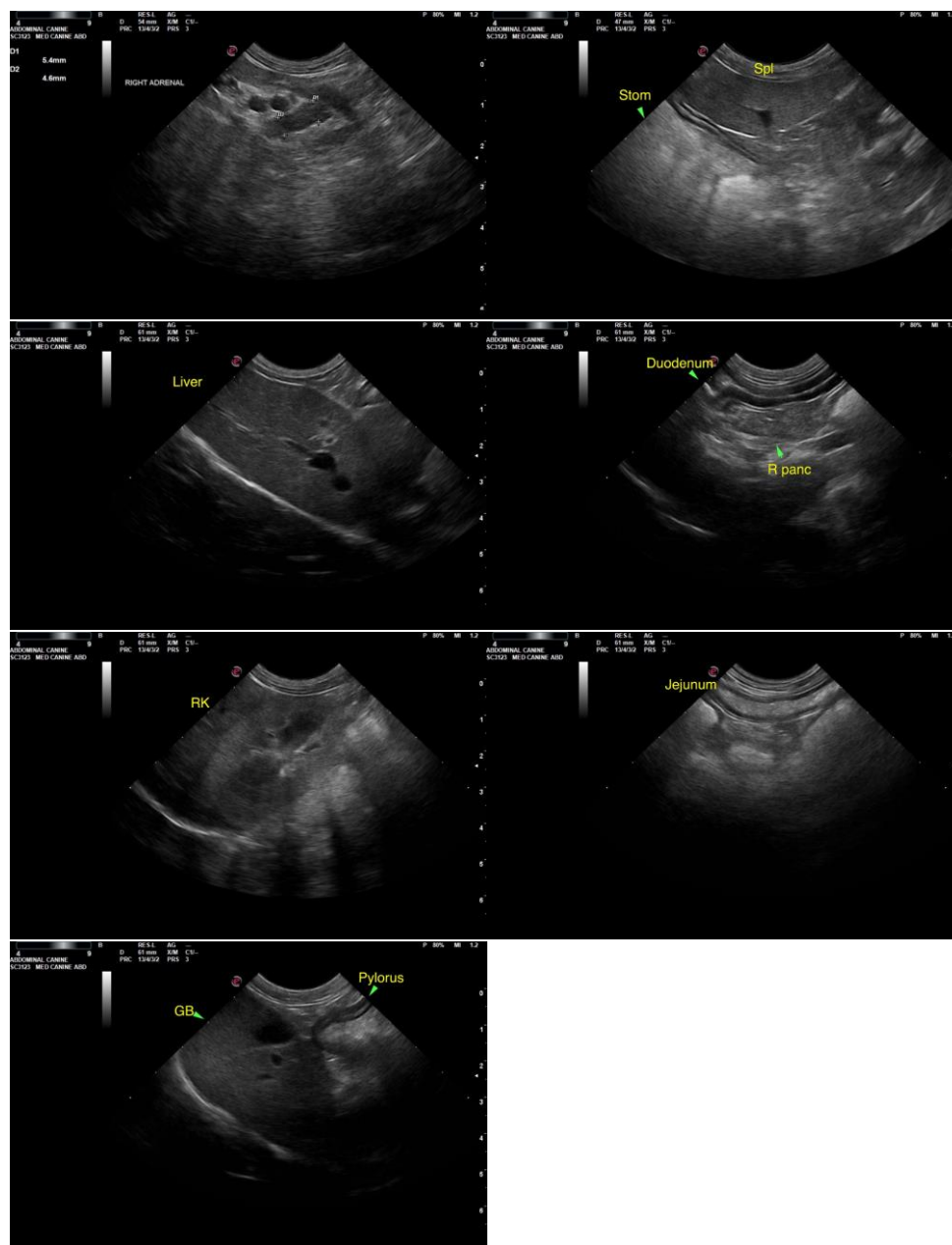
Dr. Michelle Engel

INVOICE

10186ag

DATE

03/16/2022



The information and recommendations provided are based on the images presented by the referring veterinarian/sonographer. No evaluation can be communicated regarding pathology that was not visible in the image/video clips provided.

Thank you for this referral. If the clinical or image interpretation does not parallel your findings or if I can be of any further assistance please contact me.

R. McKenzie Daniel, DVM, DABVP (Canine / Feline Practice)

info@SonoPath.com