



**PATIENT PRESENTING CLINICAL SIGNS**

Poseidon Christman Chronic urinary issues

**SPECIES ULTRASONOGRAPHIC EXAMINATION OF THE ABDOMEN**

**Canine Urinary System**

The urinary bladder was mildly distended yet exhibited subjective normal tone containing anechoic urine without evidence of sediment or calculi. No evidence of inflammatory urinary bladder wall changes, as well as no evidence of an apical urachal remnant, was noted. Possible small tubular structure which appeared to potentially bypass the level of the ureteral papilla extending caudally into the level of the prostate and proximal urethra, measuring 0.18 cm in diameter. Visible proximal urethra exhibited normal structure and tone without evidence of urethral urine retention to a depth of 3.0 cm.

**BREED** Lab  
**SEX** M  
 The prostate was of expected size and presentation for a young intact male canine without pathology measuring 1.0 cm in diameter.

**AGE** 6 months  
 No evidence of pathology in the area of the aortic trifurcation.

**WEIGHT** 27  
 Normal size and margination were present in the kidneys. A normal 1:3 cortex / medulla ratio and normal corticomedullary definition were maintained. The echogenicity of the cortex was similar to or slightly less than normal liver parenchyma while the medulla echogenicity was hypoechoic to the cortex with no evidence of pyelectasia. The left kidney measured 6.4 cm in length. The right kidney measured 6.7 cm in length.

**INTERPRETED BY Adrenal Glands**

R. McKenzie Daniel, DVM, DABVP (Canine and Feline)  
 The left adrenal gland was uniform in size and contour with a uniformly hypoechoic parenchyma. The left adrenal gland measured 0.33 cm width at the caudal pole and 0.30 cm width at the cranial pole. The right adrenal gland was uniform in size and contour with a uniformly hypoechoic parenchyma. The right adrenal gland measured 0.5 cm width at the caudal pole and 0.5 cm width at the cranial pole.

**IMAGING PERFORMED BY**  
 Rebekah Jakum, CVT  
 ARDMS/RVT

**Spleen**

**HOSPITAL NAME** Leighton AH  
 The spleen exhibited a finely textured and homogenous parenchyma which was hyperechoic to the liver and renal cortical parenchyma. The capsule was smooth and regular without apparent expansion. The splenic vasculature at the hilus was normal in volume with no evidence of congestion or thrombosis. Acute to chronic inflammatory, neoplastic, or benign parenchyma changes were not noted.

**REFERRING VET** Dr. Mriss  
**Liver/ Gallbladder**

The liver was subjectively normal in size, structure, and contour. The liver parenchyma was uniform and hypoechoic to the spleen with a mild coarse echotexture. The hepatic and portal vasculature were normal in appearance without signs of congestion. The gallbladder was non-distended in size with thin walls and primarily anechoic luminal content. The cystic and common bile ducts were normal.

**INVOICE** 13500  
**DATE** 3/16/22



**PATIENT**

Poseidon Christman

***Gastrointestinal***

The stomach presented intact yet subjective mild prominent wall layering with minor retained anechoic fluid.

**SPECIES**

Canine

The small intestine presented intact wall layering with 1:3 muscularis/mucosa ratio. The lumen of the small intestine was empty with no signs of ileus, obstruction, or foreign material.

**BREED**

Lab

***Pancreas***

The parenchyma of the left limb, body, and right limb of the pancreas presented isoechoic to the adjacent omental fat. A normal curvilinear capsule contour of the pancreas was present. The visible pancreatic duct was normal. No signs of active inflammation or neoplastic disease were evident.

**SEX**

M

***Free Abdomen***

**AGE**

6 months

Intermittent, mesenteric lymph nodes were present. The lymph nodes were moderately prominent in size and essentially isoechoic to adjacent omentum without evidence of peripheral inflammation and maintaining a normal width: length ratio (<0.5). An example lymph node measured 1.4 cm in diameter. No effusion was noted.

**WEIGHT**

27

Both the left and right testicles were sonographically unremarkable.

**ULTRASONOGRAPHIC FINDINGS**

***Primary Findings***

- Possible small ectopic ureter, overtly normal urinary bladder, prostate, and visible proximal urethra otherwise
- Normal bilateral kidneys - no evidence of dysplasia or pyelonephritis
- Intermittent benign to mildly nonhomogeneous mesenteric lymph nodes - suspect benign hyperplasia or immunologic immaturity

**INTERPRETED BY**

R. McKenzie Daniel,  
 DVM, DABVP  
 (Canine and Feline)

**IMAGING PERFORMED BY**

Rebekah Jakum, CVT  
 ARDMS/RVT

**HOSPITAL NAME**

Lehighton AH

**REFERRING VET**

Dr. Mriss

**INTERPRETATION OF THE FINDINGS & FURTHER RECOMMENDATIONS**

Although not definitive, the small tubular structure appearing to bypass the level of the ureteral papilla is suggestive of a small ectopic ureter, especially if clinical signs consistent with ectopic ureter i.e., incontinence signs, persistent documented Infection on sterile urine C/S are present. No other overt evidence of upper or lower urinary tract pathology was noted.

Further assessment including contrast radiography or ideally, gold standard CT with contrast is suggested for further assessment if possible.

**INVOICE**

13500

**DATE**

3/16/22



**PATIENT**

Poseidon Christman

**SPECIES**

Canine

**BREED**

Lab

**SEX**

M

**AGE**

6 months

**WEIGHT**

27

**INTERPRETED BY**

R. McKenzie Daniel,  
DVM, DABVP  
(Canine and Feline)

**IMAGING**

**PERFORMED BY**

Rebekah Jakum, CVT  
ARDMS/RVT

**HOSPITAL NAME**

Leighton AH

**REFERRING VET**

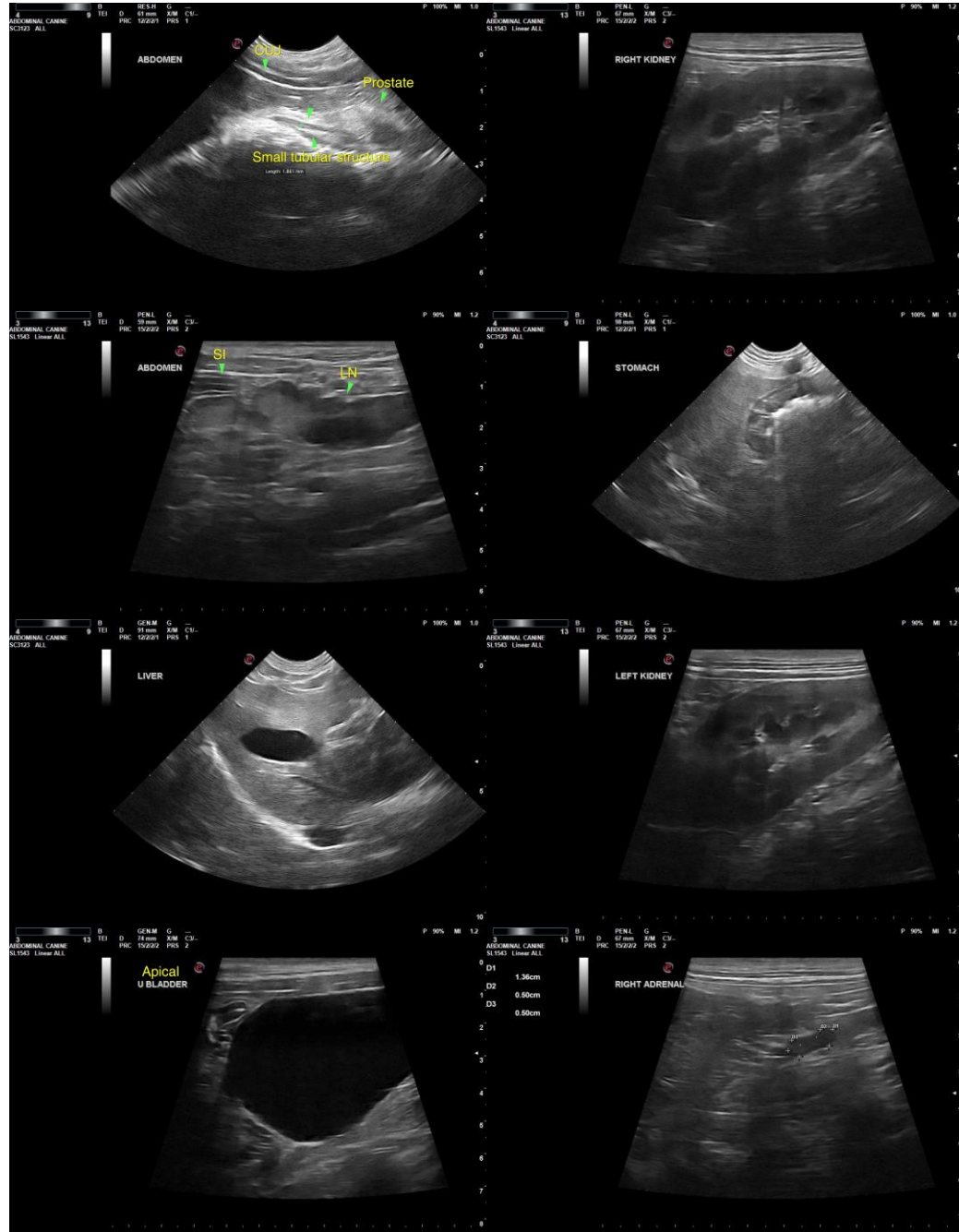
Dr. Mriss

**INVOICE**

13500

**DATE**

3/16/22





**PATIENT**

Poseidon Christman

**SPECIES**

Canine

**BREED**

Lab

**SEX**

M

**AGE**

6 months

**WEIGHT**

27

**INTERPRETED BY**

R. McKenzie Daniel,  
DVM, DABVP  
(Canine and Feline)

**IMAGING  
PERFORMED BY**

Rebekah Jakum, CVT  
ARDMS/RVT

**HOSPITAL NAME**

Lehighton AH

**REFERRING VET**

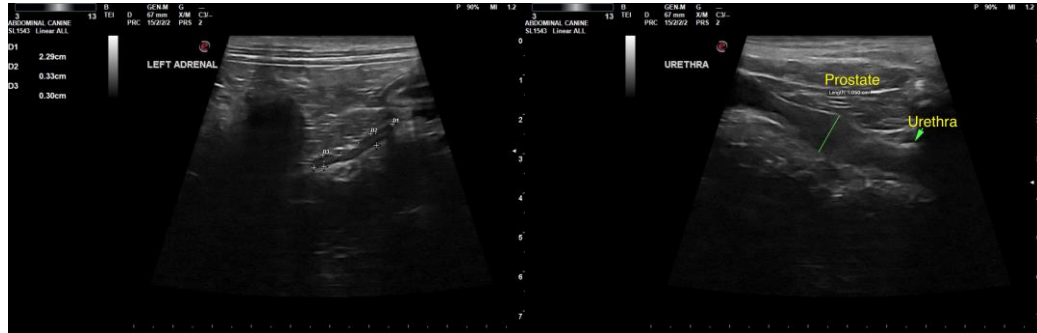Dr. Mriss

**INVOICE**

13500

**DATE**

3/16/22



The information and recommendations provided are based on the images presented by the referring veterinarian/sonographer. No evaluation can be communicated regarding pathology that was not visible in the image/video clips provided.

Thank you for this referral. If the clinical or image interpretation does not parallel your findings or if I can be of any further assistance, please contact me.

**R. McKenzie Daniel, DVM, DABVP (Canine/Feline Practice)**  
[mac.daniel@sonopath.com](mailto:mac.daniel@sonopath.com)