



PATIENT

Willow Dsouza

SPECIES

Canine

BREED

Aust Blue Heeler X

SEX

Female

AGE

1 Year 3 Months

WEIGHT

63 Pounds

INTERPRETED BY

R. McKenzie Daniel,
DVM, DABVP
(Canine and Feline)

IMAGING PERFORMED BY

Amanda Crook – SDEP
Certified Clinical
Sonographer

HOSPITAL NAME

Rivers Edge PMC

REFERRING VET

Dr. Travis Gibson

INVOICE

45859

DATE

3/13/23

PRESENTING CLINICAL SIGNS

P was spayed 12/2022; 5-6 days ago started showing signs of heat; has bloody vaginal discharge and swollen vulva.

Abnormal PE/Chem/CBC/UA Results: CBC shows normal values - see attached

LIMITED ULTRASONOGRAPHIC EXAMINATION

Urinary System

The urinary bladder, trigone, cystourethral junction, and visible pelvic urethra to a depth of 2.0 cm exhibited normal thickness and tone. Anechoic urine was present in the lumen with no uroliths or sediment. The ureteral papillae were normal. The ureters were not visible which is normal. No evidence of inflammatory or neoplastic changes were noted.

Persistent mildly prominent uterine tissue noted at the level of the cervix, dorsal to the urinary bladder, potentially extending into the area of the proximal uterine horn cranial to the urinary bladder. Visualized uterine tissue appeared to exhibit empty lumen without overt evidence of luminal fluid or obvious pyometra/stump pyometra criteria. Visible persistent uterine tissue measured 2.0 cm in diameter. Mildly non-homogeneous potentially cystic or follicular retained ovarian tissue noted caudal to the left kidney, measuring 2.0 cm in diameter. No obvious evidence of retained right ovarian tissue.

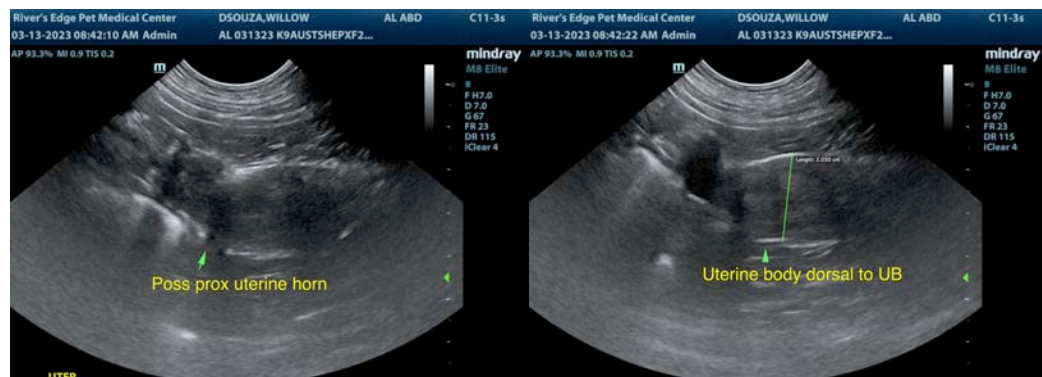
Both kidneys appeared sonographically unremarkable in size, with 1:3 cortex to medulla ratio and adequate corticomedullary border demarcation.

ULTRASONOGRAPHIC FINDINGS

- Left ovarian remnant
- Retained uterine body tissue dorsal to potentially dorsocranially to the urinary bladder with possible mild retained proximal uterine horn tissue, potential emerging stump granuloma.

INTERPRETATION OF THE FINDINGS & FURTHER RECOMMENDATIONS

Laparotomy with resection of retained left ovarian tissue as well as resection of persistent uterine tissue to include the cervix is recommended.





PATIENT

Willow Dsouza

SPECIES

Canine

BREED

Aust Blue Heeler X

SEX

Female

AGE

1 Year 3 Months

WEIGHT

63 Pounds

INTERPRETED BY

R. McKenzie Daniel,
DVM, DABVP
(Canine and Feline)

IMAGING PERFORMED BY

Amanda Crook – SDEP
Certified Clinical
Sonographer

HOSPITAL NAME

Rivers Edge PMC

REFERRING VET

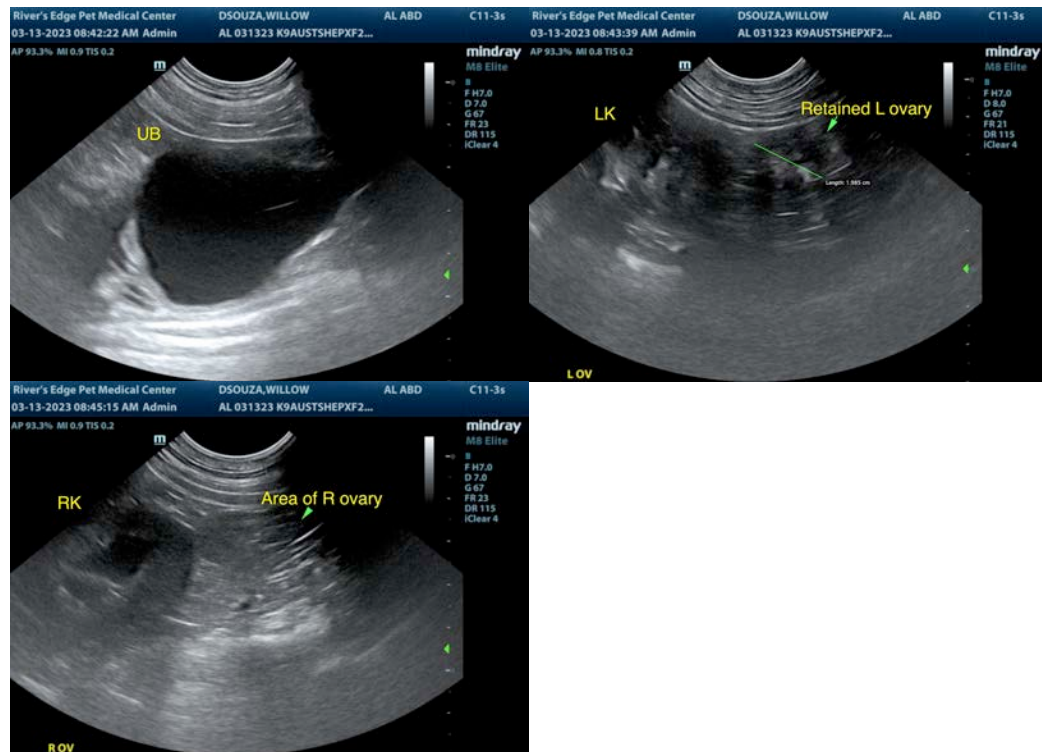
Dr. Travis Gibson

INVOICE

45859

DATE

3/13/23



The information and recommendations provided are based on the images presented by the referring veterinarian/sonographer. No evaluation can be communicated regarding pathology that was not visible in the image/video clips provided.

Thank you for this referral. If the clinical or image interpretation does not parallel your findings or if I can be of any further assistance please contact me.

R. McKenzie Daniel, DVM, DABVP (Canine / Feline Practice)

info@SonoPath.com