



PATIENT

Piper Garnic

SPECIES

Canine

BREED

Boxer/Coonhound Mix

SEX

Spayed Female

AGE

10 Years

WEIGHT

70 pounds

INTERPRETED BY

R. McKenzie Daniel,
DVM, DABVP (Canine
/ Feline Practice)

IMAGING PERFORMED BY

Dr. Brandon Holmes

HOSPITAL NAME

West Newton Animal
Clinic

REFERRING VET

Dr. Brandon Holmes

INVOICE

14299

DATE

03/12/26

PRESENTING CLINICAL SIGNS

- Progressively elevated liver values since mid-2024.
- Assumed values were elevated due to a spindle cell tumor that was removed in 2025 or dental disease which was addressed in 2024 with no improvement.

Abnormal PE/Chem/CBC/UA Results: 2/2/2026 bloodwork showing ALT = 267 and ALKP = 1843

ULTRASONOGRAPHIC EXAMINATION OF THE ABDOMEN

Urinary System

The urinary bladder, trigone, cystourethral junction, and visible pelvic urethra to a depth of 3.0 cm exhibited normal thickness and tone. Anechoic urine was present in the lumen with no uroliths or sediment. The ureteral papillae were normal. The ureters were not visible which is normal. No evidence of inflammatory or neoplastic change were noted.

The area of the aortic trifurcation was free of pathology.

Normal size and margination was present in the kidneys. A normal 1:3 cortex / medulla ratio was maintained. The medulla and cortices were uniform in texture with some increased echogenicity and mild loss of corticomedullary symmetry and definition expected for the age of the patient. No evidence of pelvic dilation was present. The left kidney measured 6.8 cm in length. The right kidney measured 6.9 cm in length.

Adrenal Glands

The left adrenal gland was uniform in size and contour with a uniformly hypoechoic parenchyma. The left adrenal gland measured 0.74 cm width at the caudal pole.

The right adrenal gland was indistinctly visualized yet overtly normal in size, position and shape without overt pathology. The right adrenal gland subjectively measured 0.70 cm width at the caudal pole.

Spleen

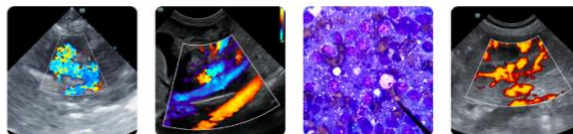
The spleen exhibited a finely textured and homogenous parenchyma which was hyperechoic to the liver and renal cortical parenchyma. The capsule was smooth and regular without apparent expansion. The splenic vasculature at the hilus was normal in volume with no evidence of congestion or thrombosis. Acute to chronic inflammatory, neoplastic, or benign parenchyma changes were not noted.

Liver & Gallbladder

The liver was subjectively normal in size, structure, and contour. The liver parenchyma was uniform and hypoechoic to the spleen with a mild coarse echotexture. The hepatic and portal vasculature were normal in appearance without signs of congestion.

The gallbladder was non distended in size with mild nonorganized biliary sludge. The cystic duct and common bile ducts were normal without evidence of dilation.

Gastrointestinal



PATIENT

Piper Garnic

SPECIES

Canine

BREED

Boxer/Coonhound Mix

SEX

Spayed Female

AGE

10 Years

WEIGHT

70 pounds

INTERPRETED BY

R. McKenzie Daniel,
DVM, DABVP (Canine
/ Feline Practice)

IMAGING PERFORMED BY

Dr. Brandon Holmes

HOSPITAL NAME

West Newton Animal
Clinic

REFERRING VET

Dr. Brandon Holmes

INVOICE

14299

DATE

03/12/26

The stomach presented intact wall layering with a normal wall layer ratio. The lumen of the stomach contained primarily pyloric variably echogenic nonshadowing ingesta without signs of obstruction or foreign material.

The small intestine presented intact wall layering with 1:3 muscularis/mucosa ratio. The lumen of the small intestine was empty with no signs of ileus, obstruction or foreign material.

Normal visible colon wall layers were present with apparent formed feces in lumen.

Pancreas

The parenchyma of the left limb, body and right limb of the pancreas presented isoechoic to the adjacent omental fat. A normal curvilinear capsule contour of the pancreas was present. The visible pancreatic duct was normal. No signs of active inflammation or neoplastic disease was evident.

Free Abdomen

No overt lymphadenopathy or peritoneal effusion was present.

ULTRASONOGRAPHIC FINDINGS

- Sonographically unremarkable normal volume liver.
- Minor gallbladder debris (non-mucocele).
- Mild age-related renal changes.
- Normal adrenal glands.

INTERPRETATION OF THE FINDINGS & FURTHER RECOMMENDATIONS

The appearance of the liver was nonspecific but most consistent with benign hepatopathy. Considerations for the liver may include benign vacuolar / cholestatic hepatopathy, inflammatory/infectious/immune mediated disease, hyperplasia, hematopoiesis, toxic hepatopathy (i.e. copper), other with neoplasia thought less likely. No evidence of intrahepatic or extrahepatic macroscopic shunt.

Ultrasound guided FNA of the liver using a 25-gauge needle and assuming normal coagulation parameters would be warranted for screening cytology. Hepatosupportive medications such as Denamarin or Vitamin E as well as Ursodiol due to its antioxidant and immunomodulatory effects within the liver would be warranted, although these medications may not result in decreased hepatic enzyme levels. Leptospiriosis titers / PCR may be considered if clinically indicated. Core or surgical biopsy likely required for definitive diagnosis. No evidence of adrenal pathology as a contributing factor, although adrenal screening or sonographic reassessment is indicated if clinical signs consistent with adrenal disease arise, or progressive hepatopathy.



PATIENT

Piper Garnic

SPECIES

Canine

BREED

Boxer/Coonhound Mix

SEX

Spayed Female

AGE

10 Years

WEIGHT

70 pounds

INTERPRETED BY

R. McKenzie Daniel,
DVM, DABVP (Canine
/ Feline Practice)

**IMAGING
PERFORMED BY**

Dr. Brandon Holmes

HOSPITAL NAME

West Newton Animal
Clinic

REFERRING VET

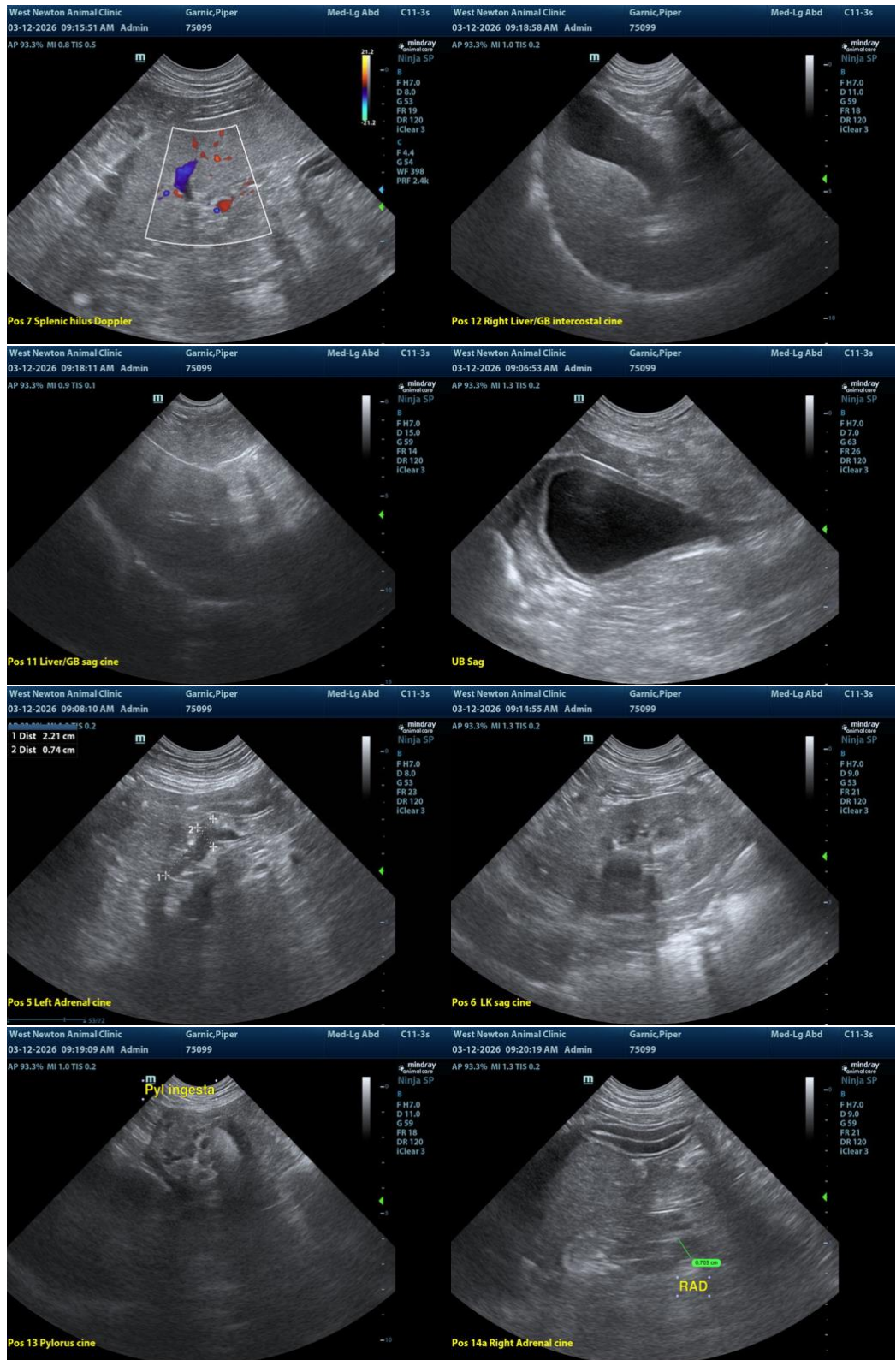
Dr. Brandon Holmes

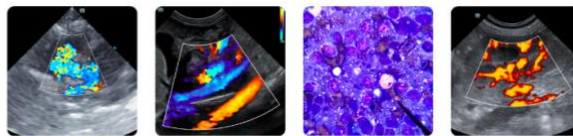
INVOICE

14299

DATE

03/12/26





PATIENT

Piper Garnic

SPECIES

Canine

BREED

Boxer/Coonhound Mix

SEX

Spayed Female

AGE

10 Years

WEIGHT

70 pounds

INTERPRETED BY

R. McKenzie Daniel,
DVM, DABVP (Canine
/ Feline Practice)

IMAGING PERFORMED BY

Dr. Brandon Holmes

HOSPITAL NAME

West Newton Animal
Clinic

REFERRING VET

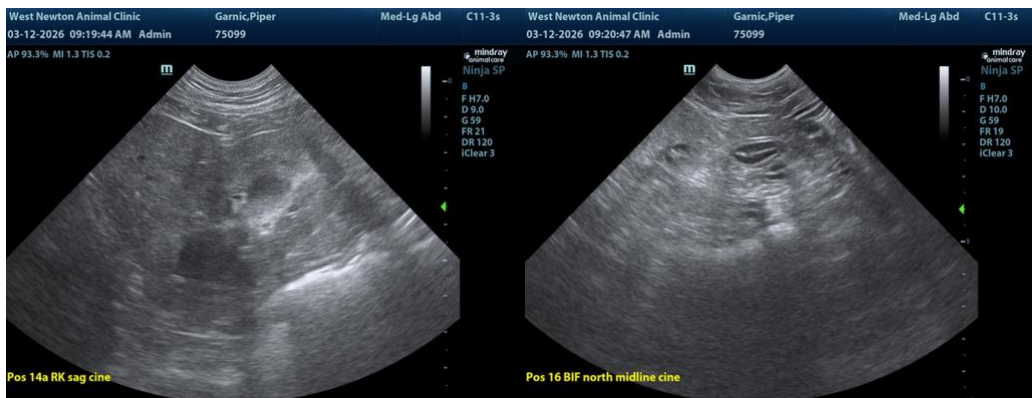
Dr. Brandon Holmes

INVOICE

14299

DATE

03/12/26



The information and recommendations provided are based on the images presented by the referring veterinarian/sonographer. No evaluation can be communicated regarding pathology that was not visible in the image/video clips provided.

Thank you for this referral. If the clinical or image interpretation does not parallel your findings or if I can be of any further assistance, please contact me.

R. McKenzie Daniel, DVM, DABVP (Canine / Feline Practice)

info@SonoPath.com