



## PATIENT

Loki Gossen

## SPECIES

Feline

## BREED

DSH

## SEX

MC

## AGE

7.5 y

## WEIGHT

4.5 kg

## INTERPRETED BY

R. McKenzie Daniel,  
DVM, DABVP  
(Canine and Feline)

## IMAGING PERFORMED BY

Danielle RVT

## HOSPITAL NAME

Orchard Veterinary  
Care

## REFERRING VET

Dr. Orchard

## INVOICE

10670

## DATE

3/12/26

## PRESENTING CLINICAL SIGNS

### History:

- chronic, long term vomiting, tried diets with no change, and GI Scope and biopsies came back normal. Owner uses Cerenia often, but as soon as he is off the medication, he vomits. Poops have been thin and stringy
- Patient is otherwise BAR, ED fine

Abnormal PE/Chem/CBC/UA Results: All WNL

## ULTRASONOGRAPHIC EXAMINATION OF THE ABDOMEN

### *Urinary System*

The urinary bladder, trigone, and cystourethral junction exhibited normal thickness and tone. Anechoic urine was present in the lumen with no uroliths or sediment. The ureteral papillae were normal. The ureters were not visible which is normal. No evidence of inflammatory or neoplastic changes were noted.

No evidence of pathology in the area of the aortic trifurcation.

Normal size and margination were present in the kidneys. A normal 1:3 cortex / medulla ratio and normal corticomedullary definition were maintained. The echogenicity of the cortex was similar to or slightly less than normal liver parenchyma while the medulla echogenicity was hypoechoic to the cortex with no evidence of pelvic dilation. The left kidney measured 3.9 cm in length. The right kidney measured 4.2 cm in length.

### *Adrenal Glands*

The left and right adrenal glands were uniform in size and contour with a uniformly hypoechoic parenchyma. The left adrenal gland measured 0.37 cm width and the right adrenal gland measured 0.34 cm width.

### *Spleen*

The spleen exhibited a finely textured and homogenous parenchyma which was hyperechoic to the liver and renal cortical parenchyma. The capsule was smooth and regular without apparent expansion. The splenic vasculature at the hilus was normal in volume with no evidence of congestion or thrombosis. Acute to chronic inflammatory, neoplastic, or benign parenchyma changes were not noted.

### *Liver/ Gallbladder*

The liver was subjectively normal in size, structure, and contour. Normal hepatic vascular volume was present. The liver parenchyma was uniform and hypoechoic to the spleen with a mild coarse echotexture. The hepatic and portal vasculature were normal in appearance without signs of congestion. The gallbladder was non-distended in size with thin walls and primarily anechoic luminal content. The cystic and common bile ducts were normal.

### *Gastrointestinal*

The stomach presented intact wall layering with a normal wall layer ratio. Mild retained primarily pyloric fluid was noted. There was no evidence of obstruction to pyloric outflow or obstructive pyloric mural pathology. The pylorus wall width measured 0.23 cm in width.



## PATIENT

Loki Gossen

## SPECIES

Feline

## BREED

DSH

## SEX

MC

## AGE

7.5 y

## WEIGHT

4.5 kg

The small intestine presented intact wall layering with 1:3 muscularis/mucosa ratio. The lumen of the small intestine was empty with no signs of ileus, obstruction, or foreign material. The duodenum wall measured 0.23 cm width. The jejunum wall measured 0.20-0.23 cm width. The ileocolic wall measured 0.35 cm width.

Normal visible colon wall layers were present with formed feces in lumen.

## *Pancreas*

The parenchyma of the left limb, body and right limb of the pancreas presented isoechoic to the adjacent omental fat. A normal curvilinear capsule contour of the pancreas was present. The visible pancreatic duct was normal. No signs of active inflammation or neoplastic disease was evident.

## *Free Abdomen*

No overt lymphadenopathy or peritoneal effusion was present.

## ULTRASONOGRAPHIC FINDINGS

- Sonographically normal gastrointestinal tract with mild retained gastric pyloric fluid
- Normal area of pancreas
- Sonographically normal visualized colon

## INTERPRETATION OF THE FINDINGS & FURTHER RECOMMENDATIONS

There is no evidence of gastroenterocolic mural pathology or active pancreatitis. Mild nonobstructive metabolic gastric stasis is present. A GI panel to include PLI/TLI/Cobalamin/Folate to assess for nonstructural intestinal disease or mild pancreatitis, which may present as sonographically normal, as a contributing factor, may be considered. Sedated rectal palpation is recommended if persistent abnormal defecation. A novel protein or hydrolyzed diet trial, if not previously noted, with as-needed continued gastroprotectants, which may include Omeprazole 1.0 mg/kg PO SID as needed, may prove beneficial.

## INTERPRETED BY

R. McKenzie Daniel,  
DVM, DABVP  
(Canine and Feline)

## IMAGING PERFORMED BY

Danielle RVT

## HOSPITAL NAME

Orchard Veterinary  
Care

## REFERRING VET

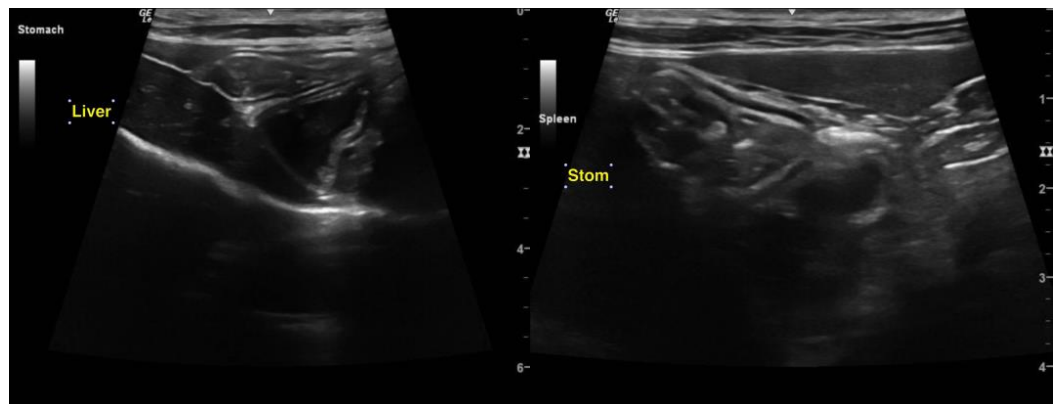
Dr. Orchard

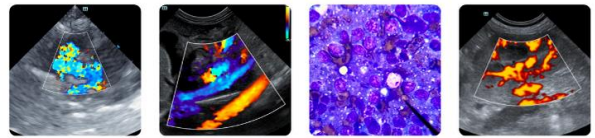
## INVOICE

10670

## DATE

3/12/26





## PATIENT

Loki Gossen

## SPECIES

Feline

## BREED

DSH

## SEX

MC

## AGE

7.5 y

## WEIGHT

4.5 kg

## INTERPRETED BY

R. McKenzie Daniel,  
DVM, DABVP  
(Canine and Feline)

## IMAGING PERFORMED BY

Danielle RVT

## HOSPITAL NAME

Orchard Veterinary  
Care

## REFERRING VET

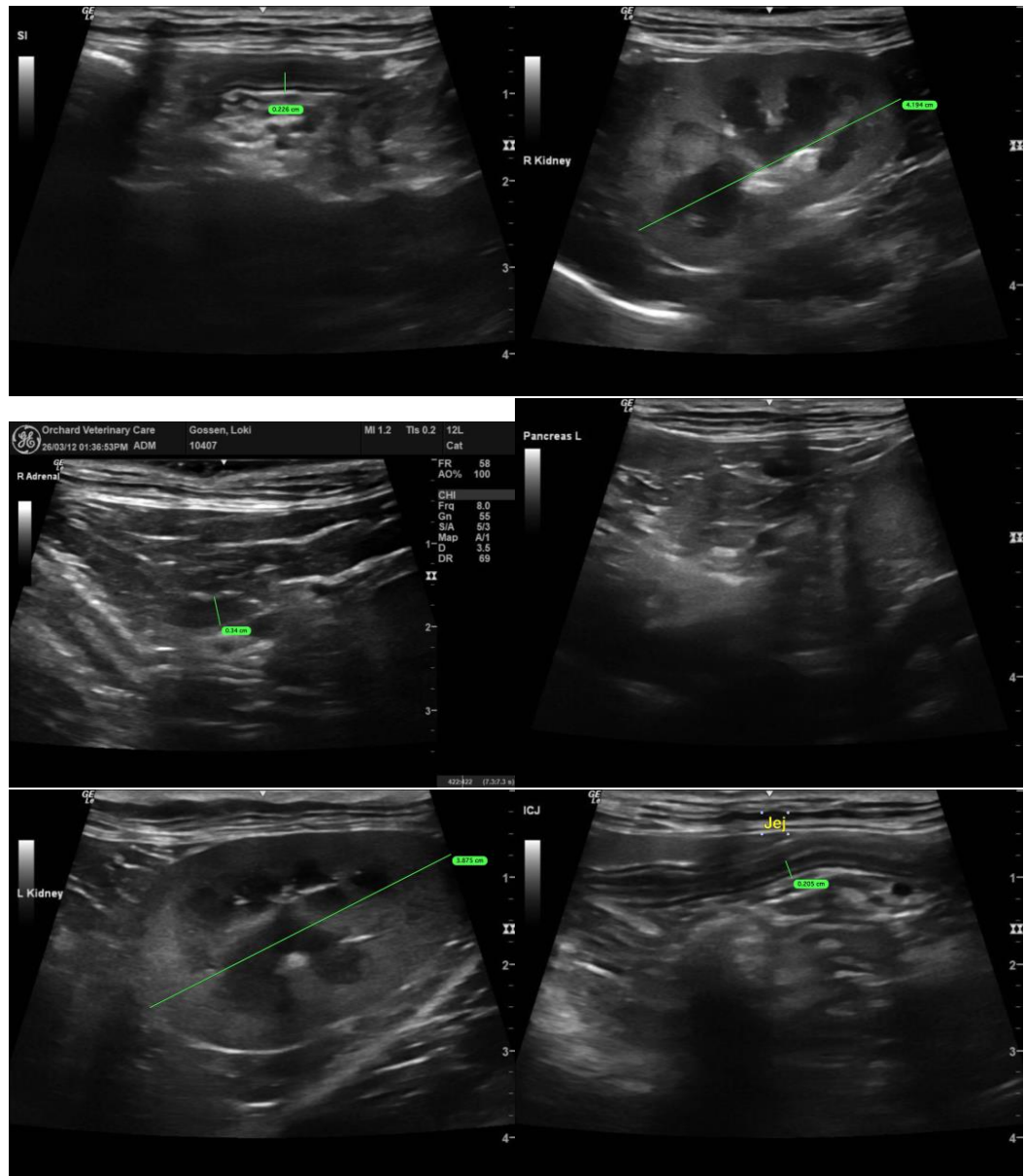
Dr. Orchard

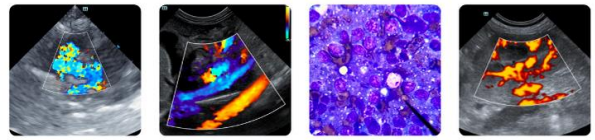
## INVOICE

10670

## DATE

3/12/26





## PATIENT

Loki Gossen

## SPECIES

Feline

## BREED

DSH

## SEX

MC

## AGE

7.5 y

## WEIGHT

4.5 kg

## INTERPRETED BY

R. McKenzie Daniel,  
DVM, DABVP  
(Canine and Feline)

## IMAGING PERFORMED BY

Danielle RVT

## HOSPITAL NAME

Orchard Veterinary  
Care

## REFERRING VET

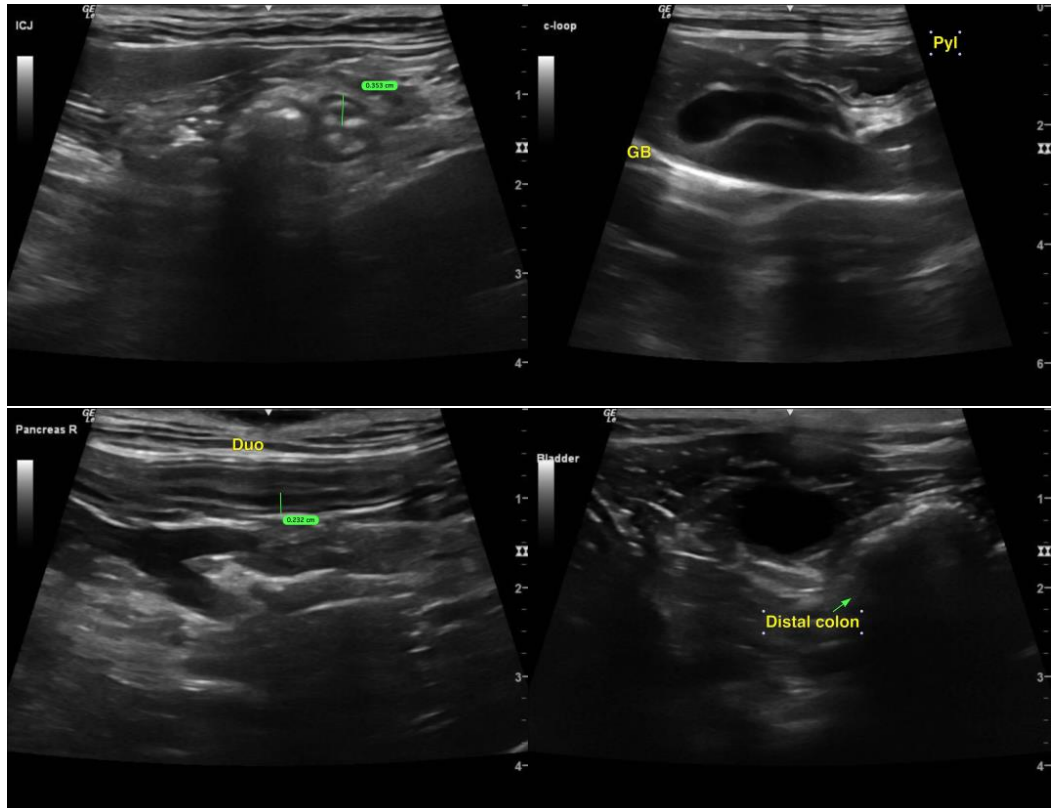
Dr. Orchard

## INVOICE

10670

## DATE

3/12/26



The information and recommendations provided are based on the images presented by the referring veterinarian/sonographer. No evaluation can be communicated regarding pathology that was not visible in the image/video clips provided.

Thank you for this referral. If the clinical or image interpretation does not parallel your findings or if I can be of any further assistance, please contact me.

R. McKenzie Daniel, DVM, DABVP (Canine/Feline Practice)  
[info@sonopath.com](mailto:info@sonopath.com)